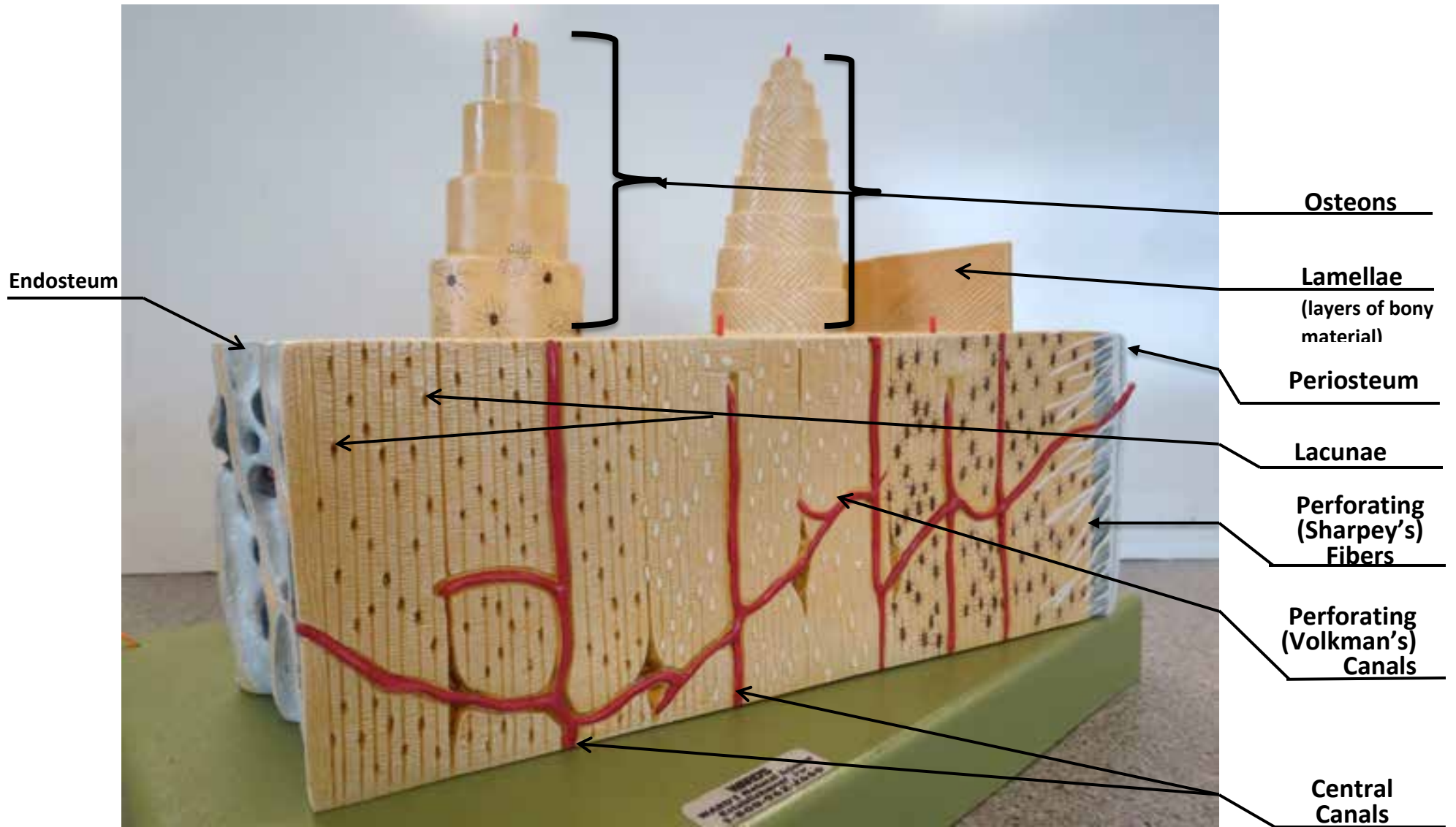


Compact Bone Model

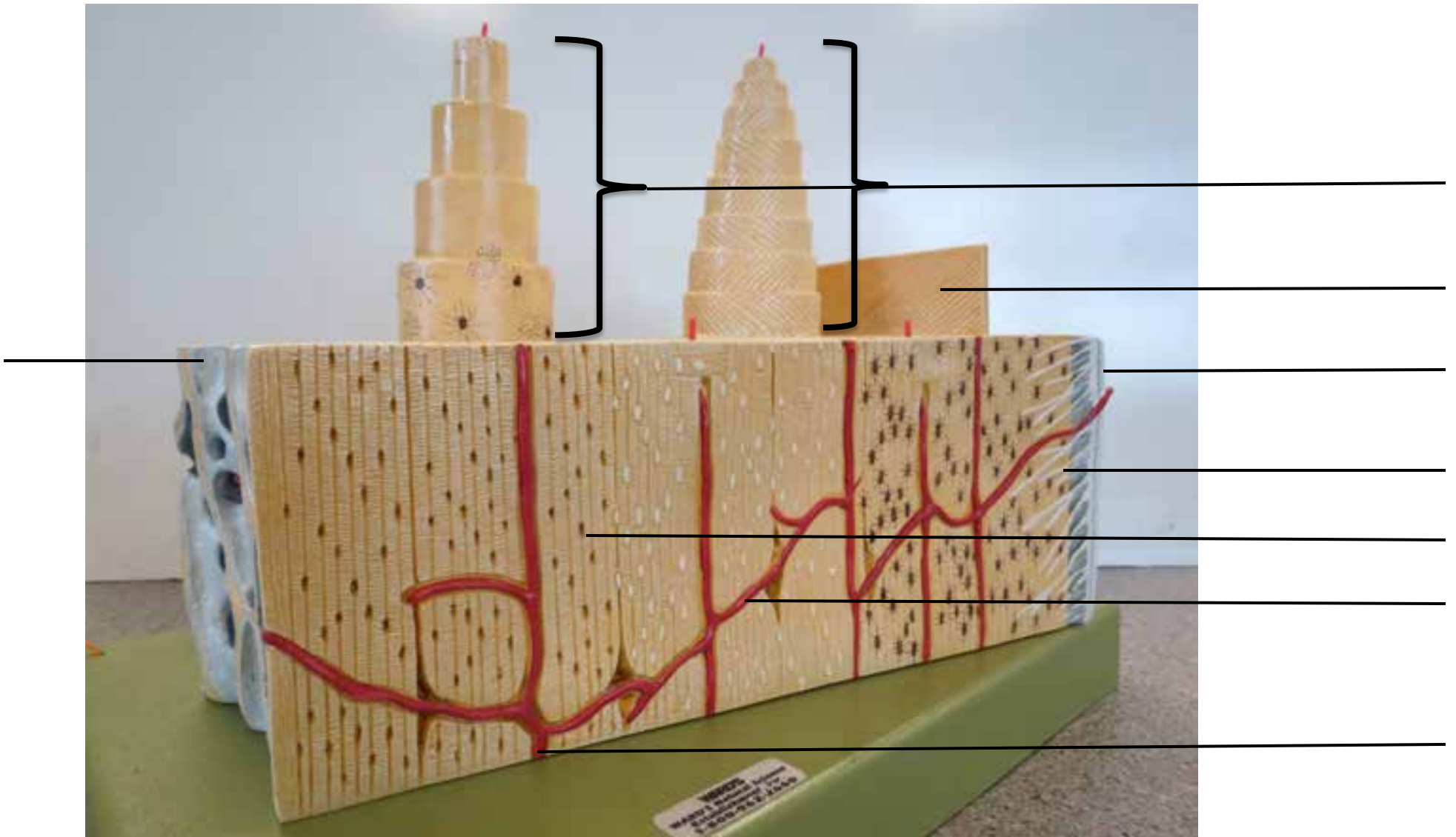


Compact Bone Model

CLOSE UP OF OSTEONS ON TOP OF BONE MODEL



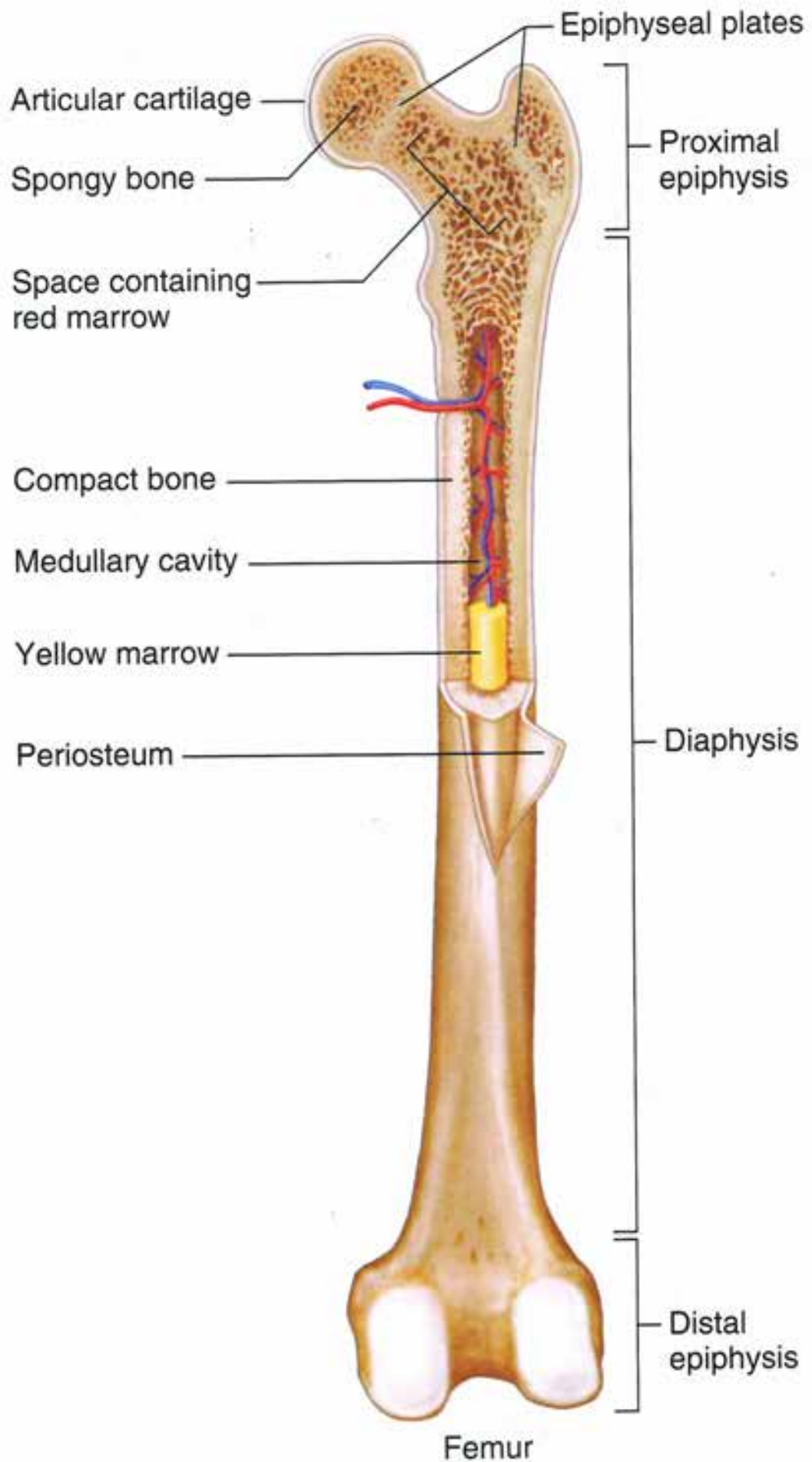
Compact Bone Model



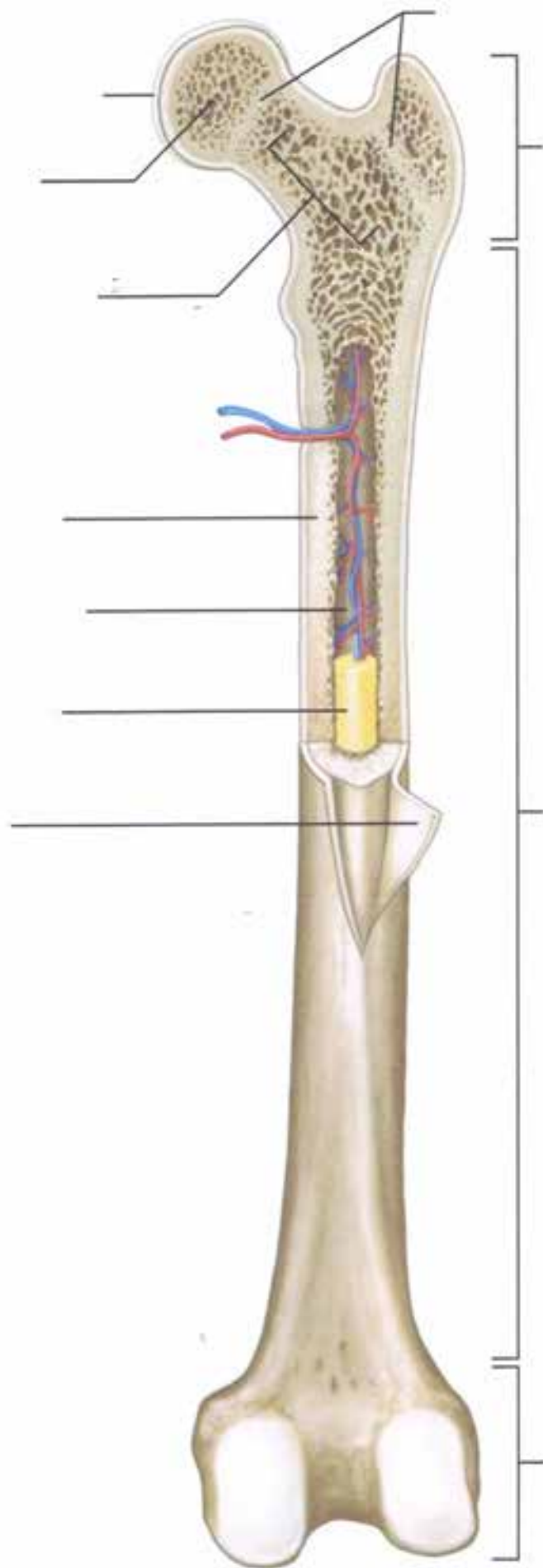
Compact Bone Model

CLOSE UP OF OSTEONS ON TOP OF BONE MODEL

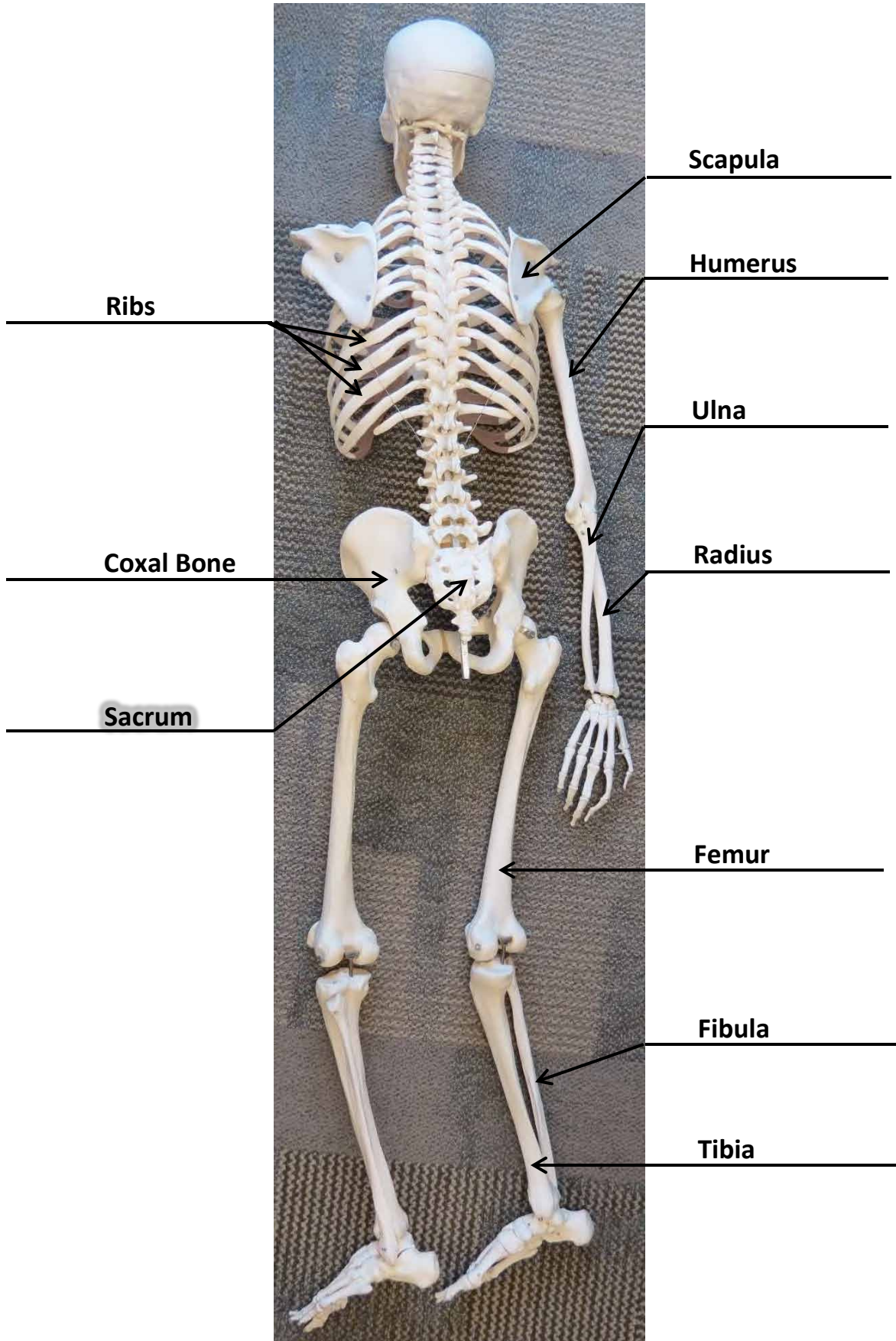




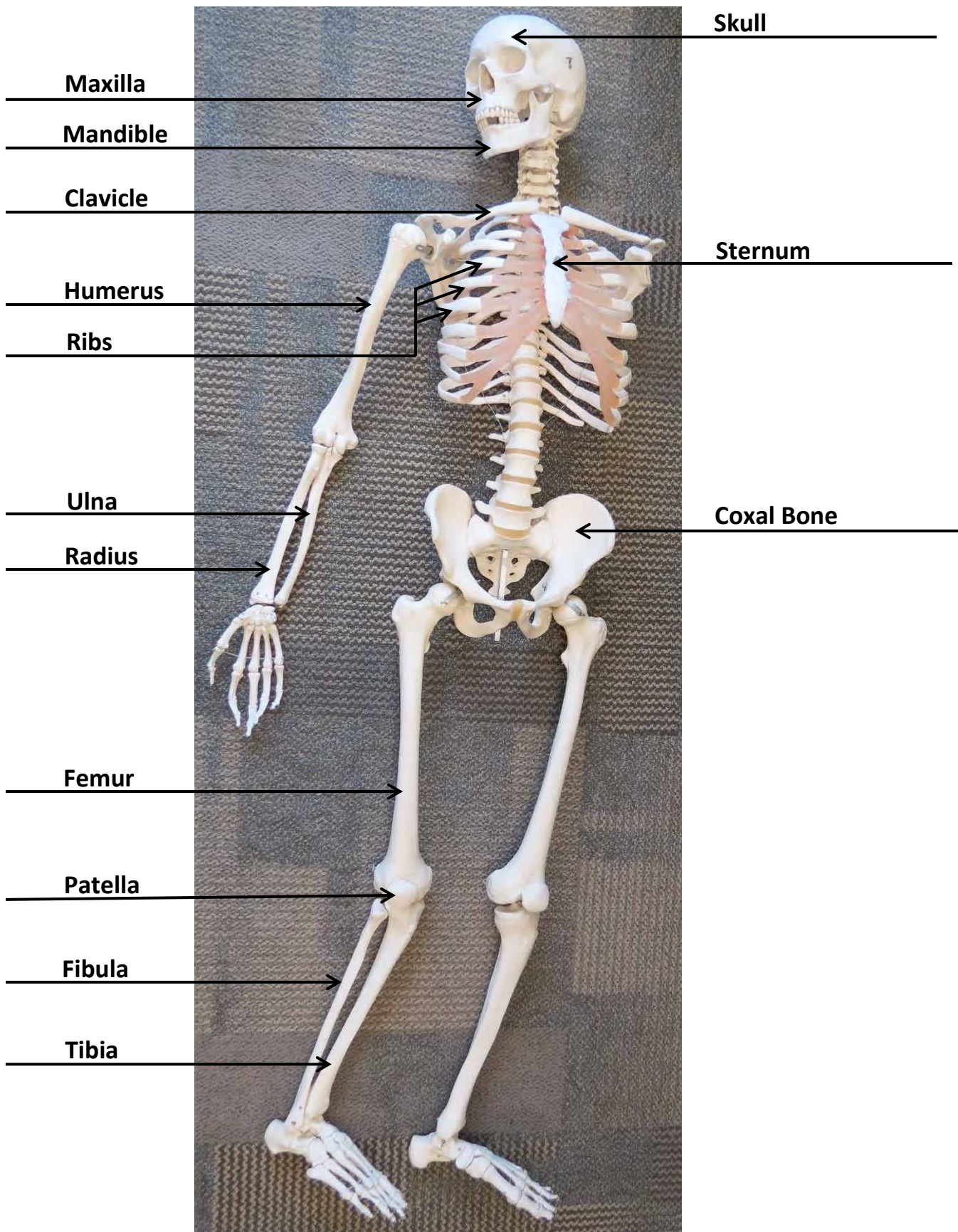
Femur



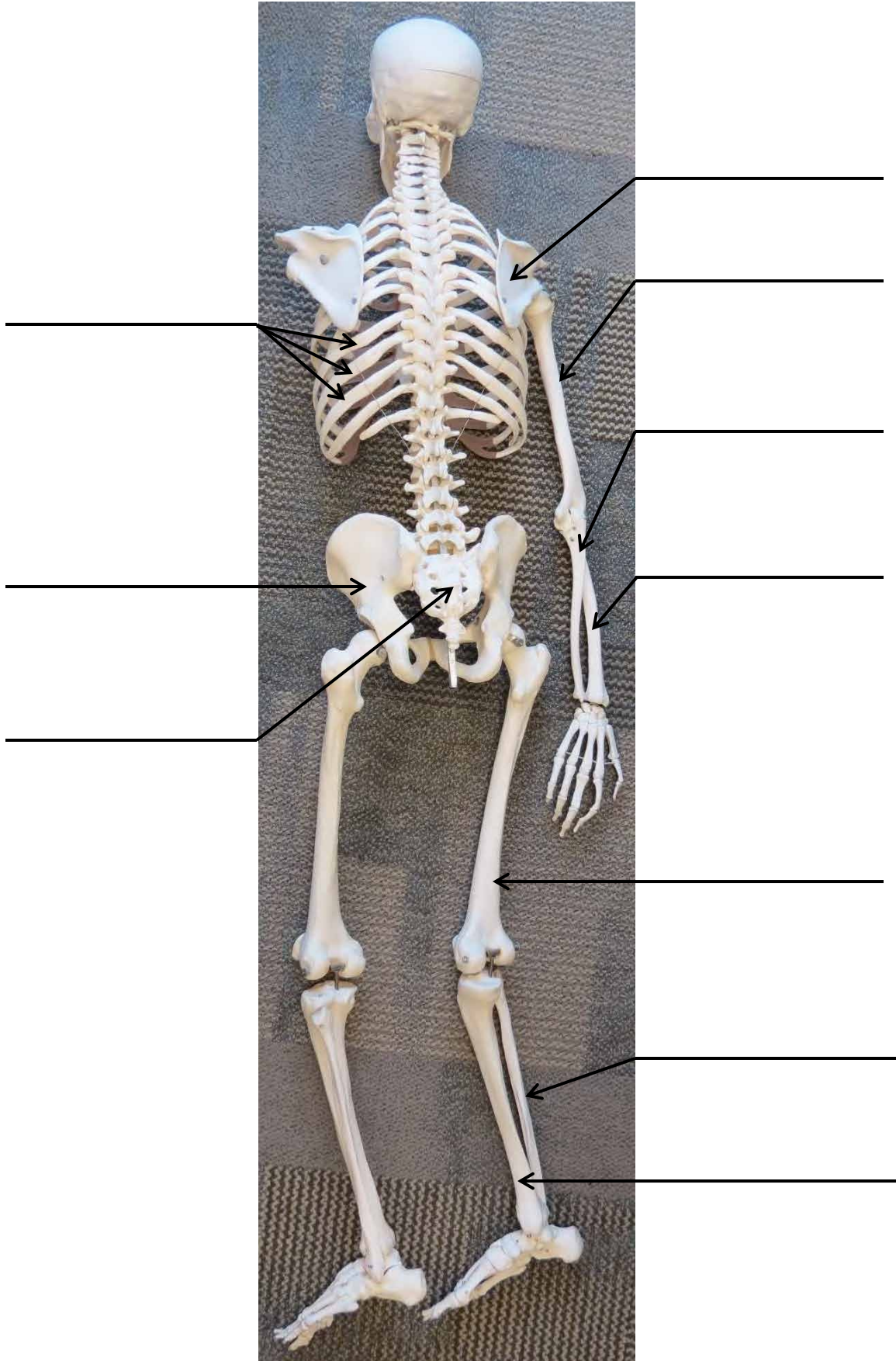
Skeleton Model



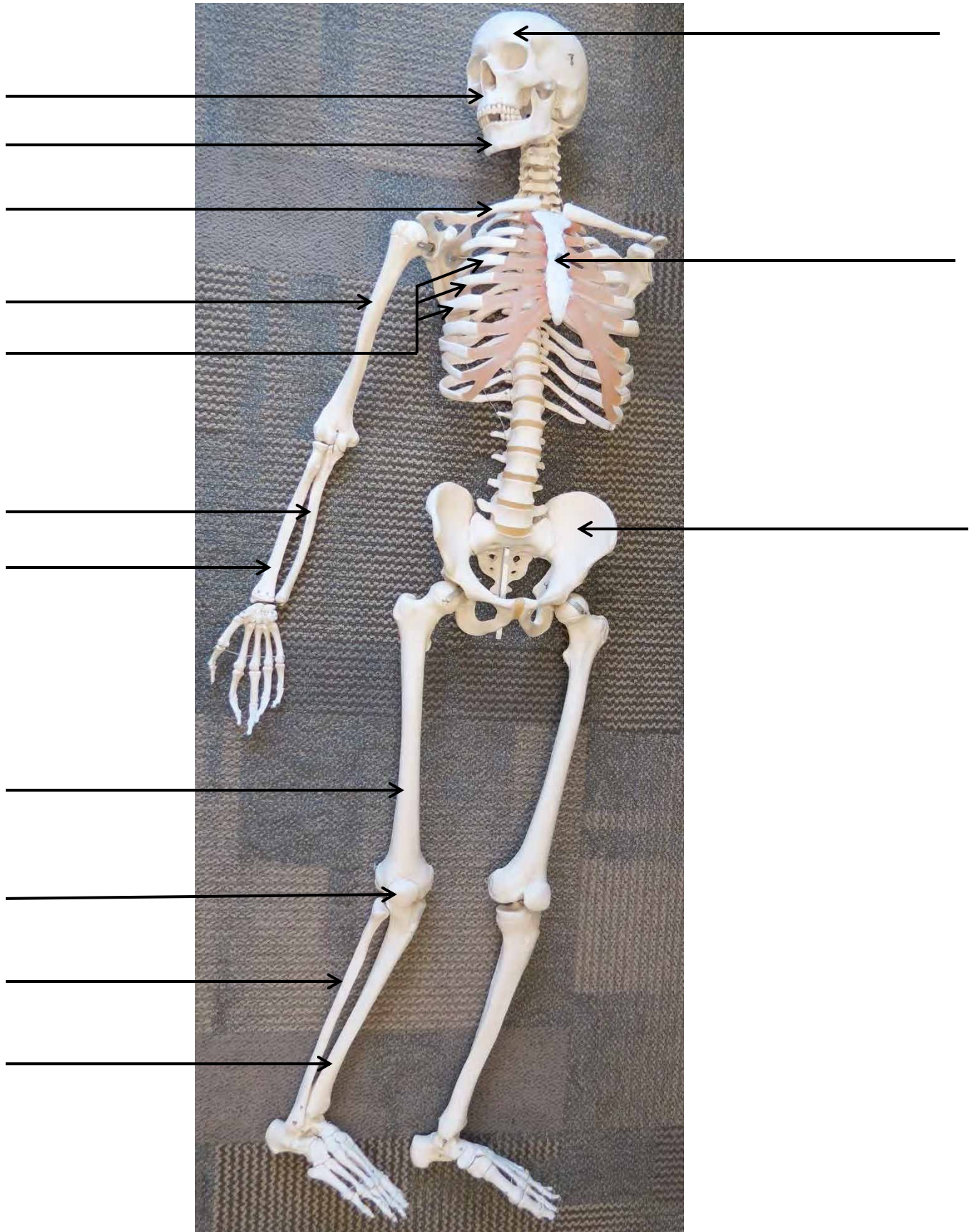
Skeleton Model



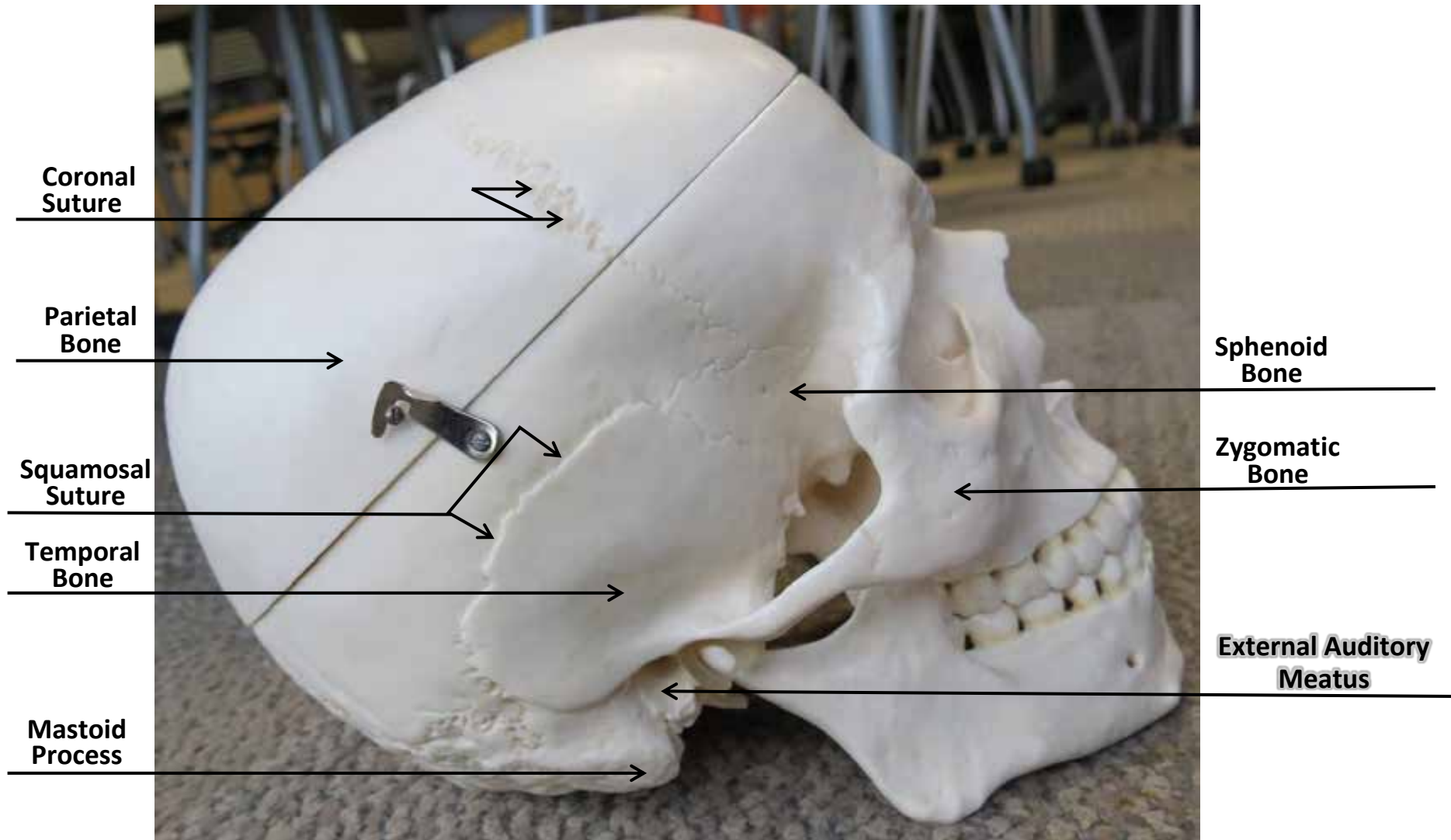
Skeleton Model




Skeleton Model



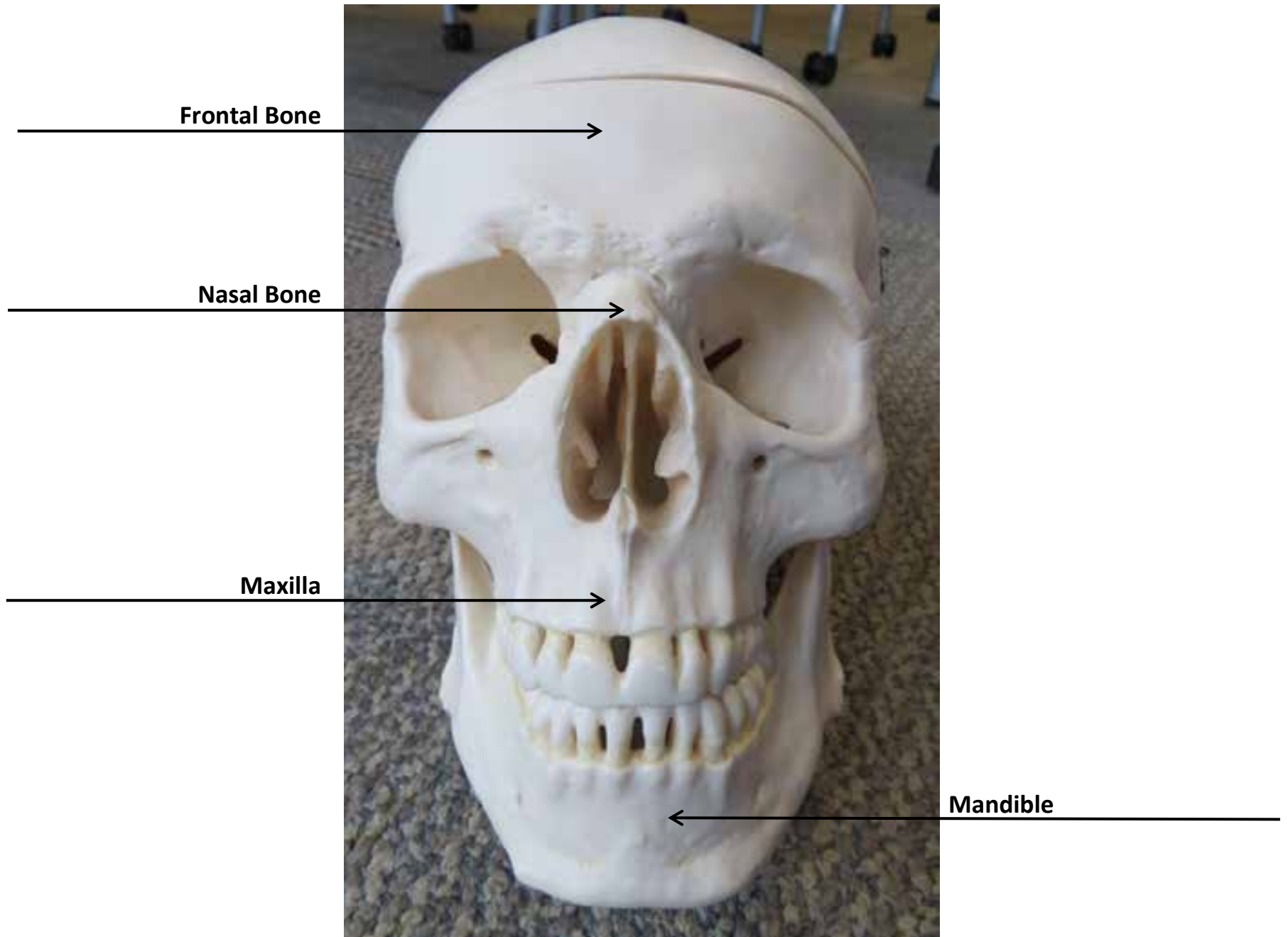
Skull Model



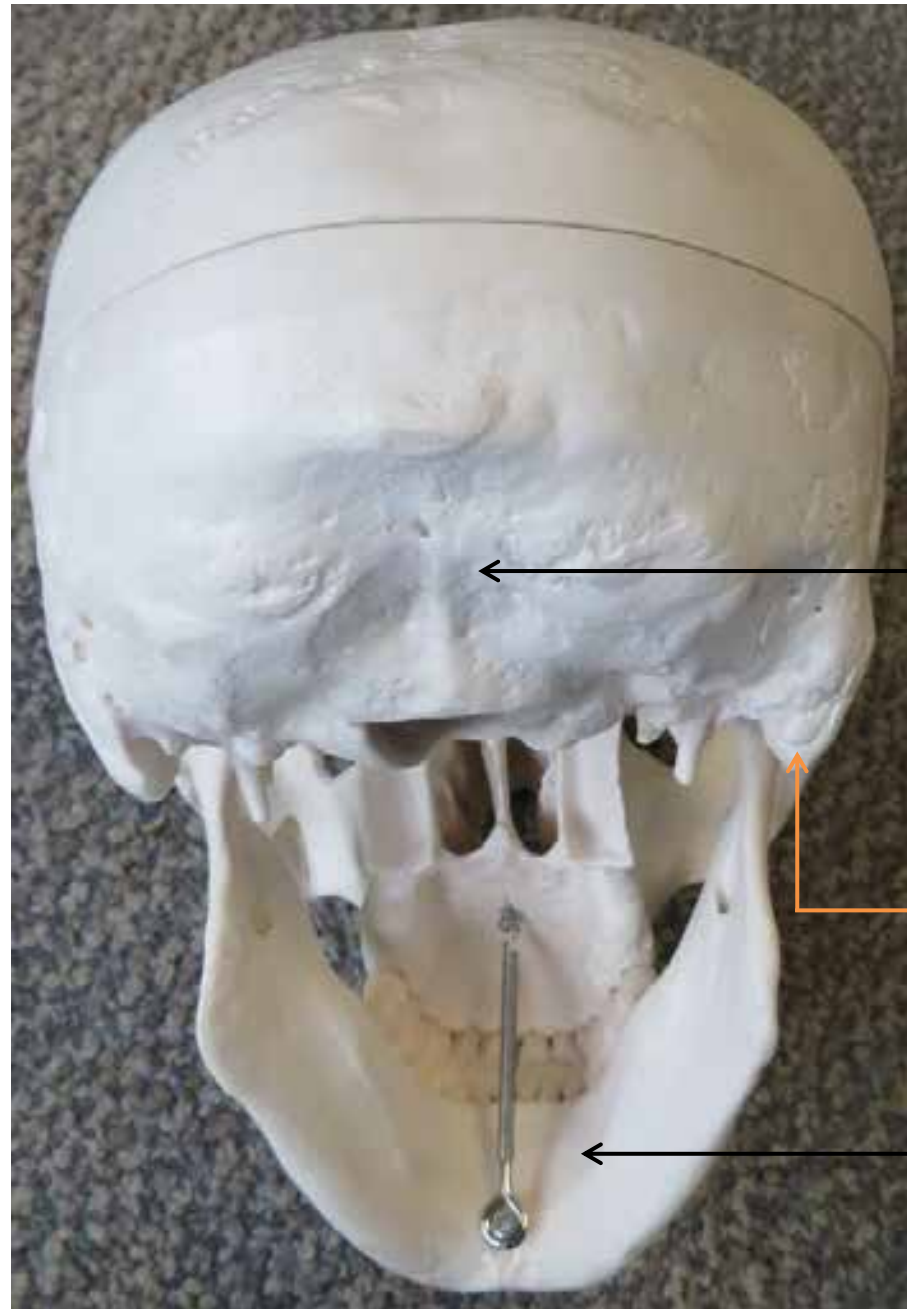
Skull Model



Skull Model



Skull Model

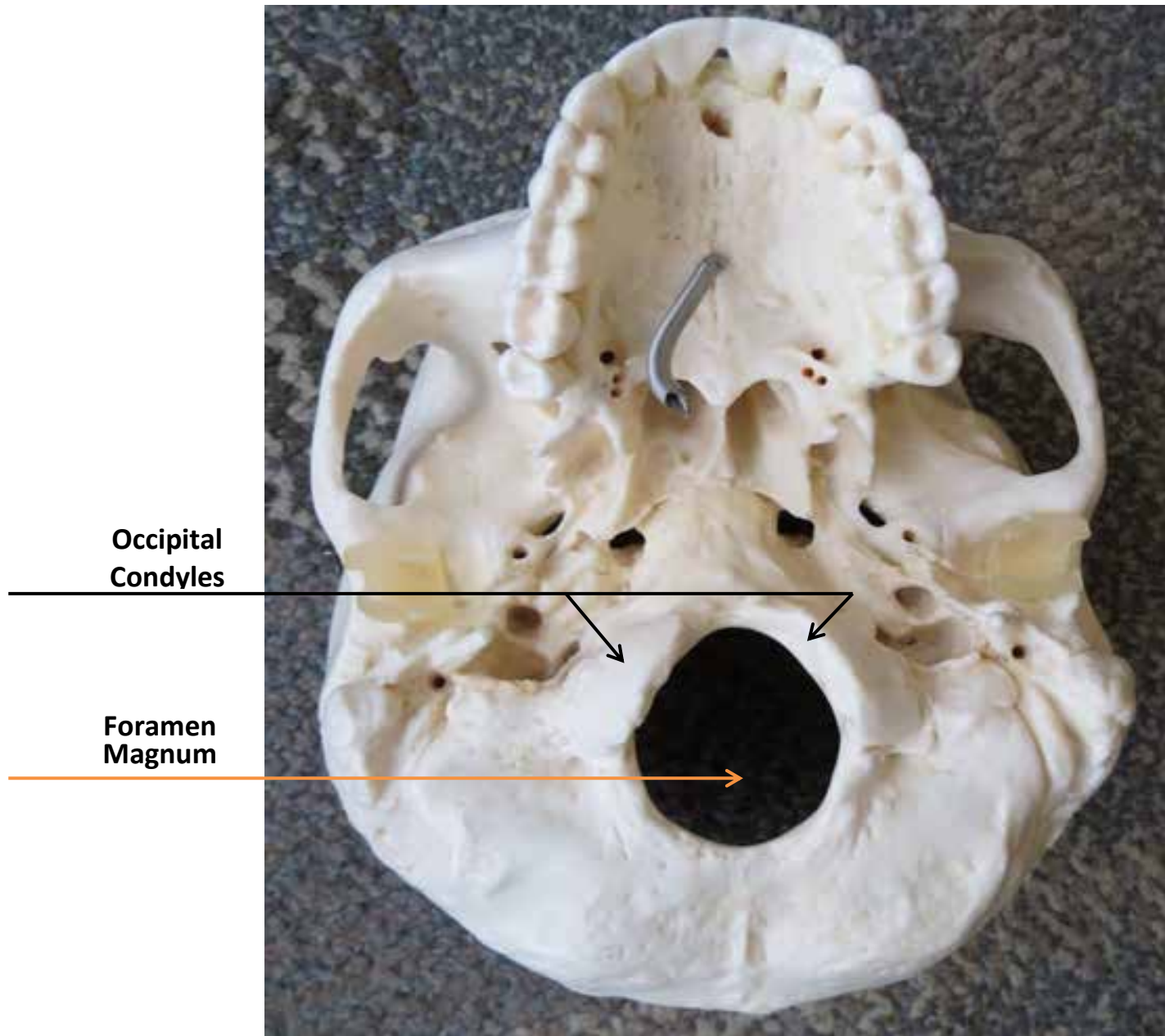


← Occipital Bone


↑ Mastoid Process

← Mandible

Skull Model




Skull Model




Sella
Turcica

Foramen
Magnum

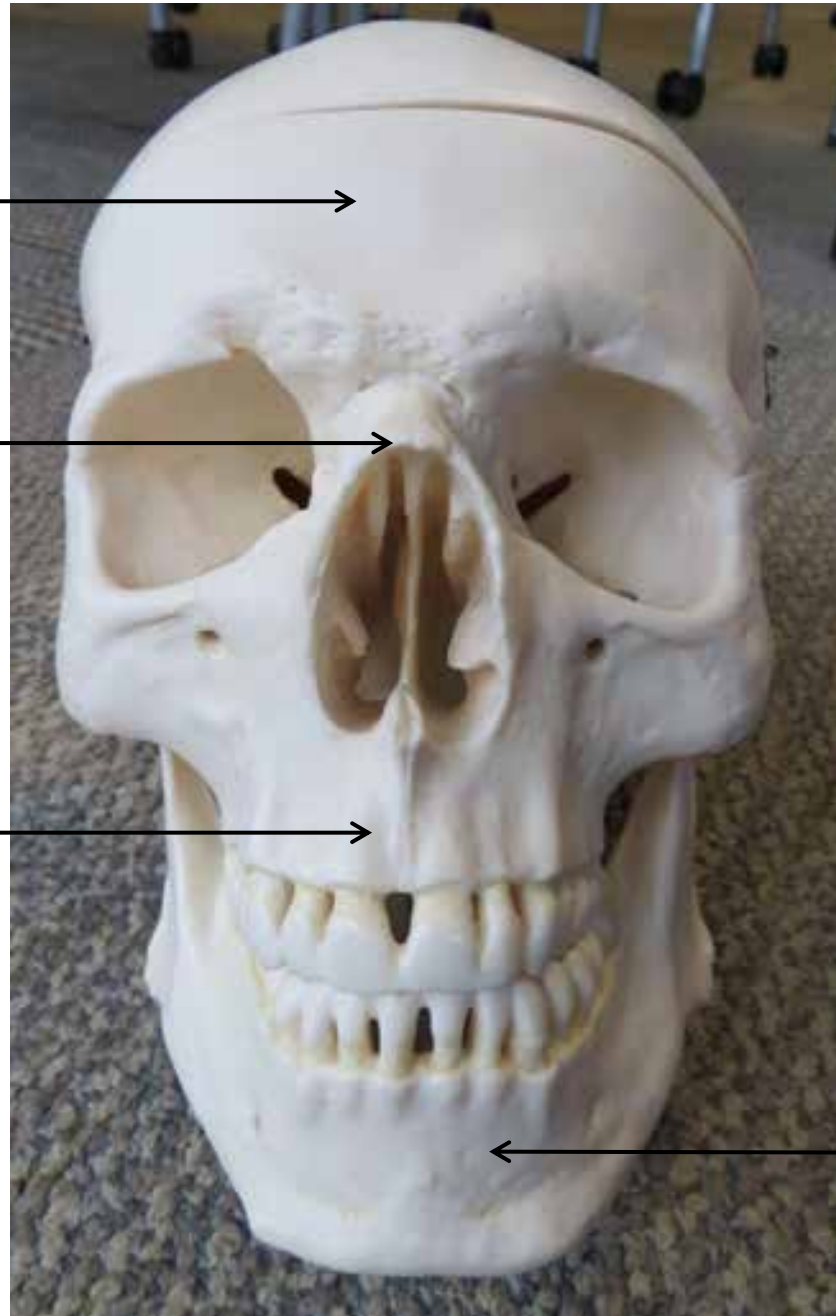
Skull Model



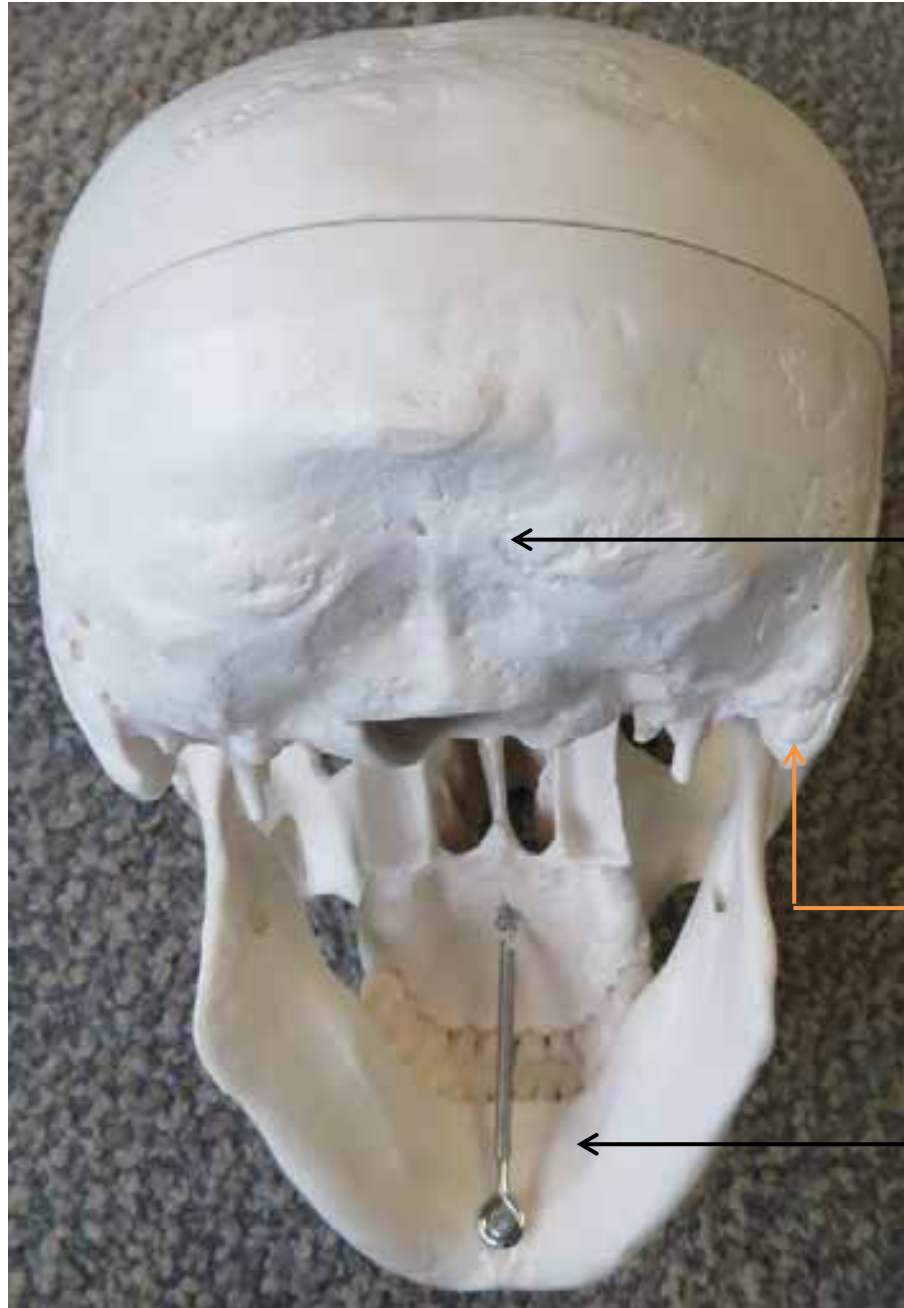
Skull Model



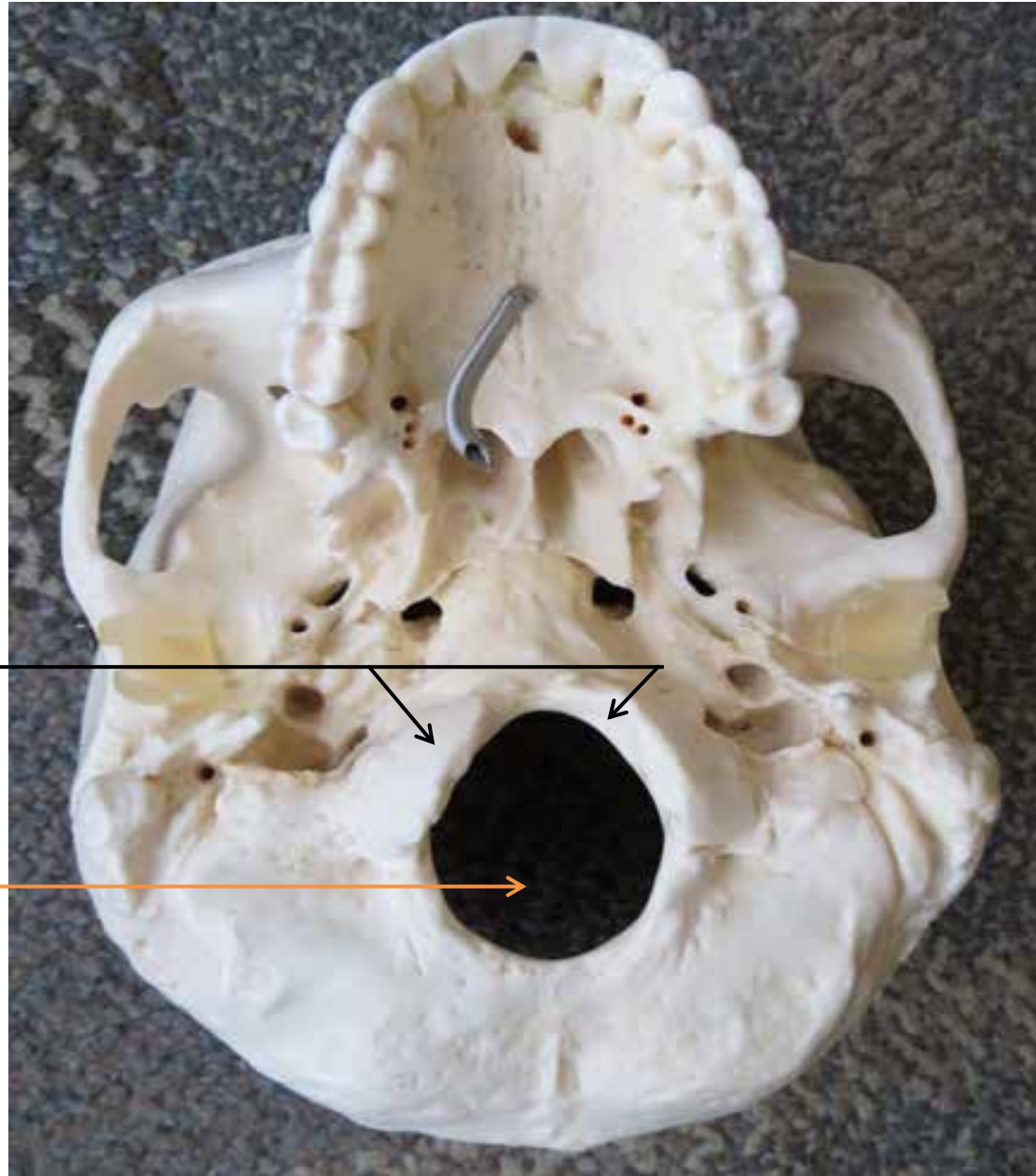
Skull Model



Skull Model

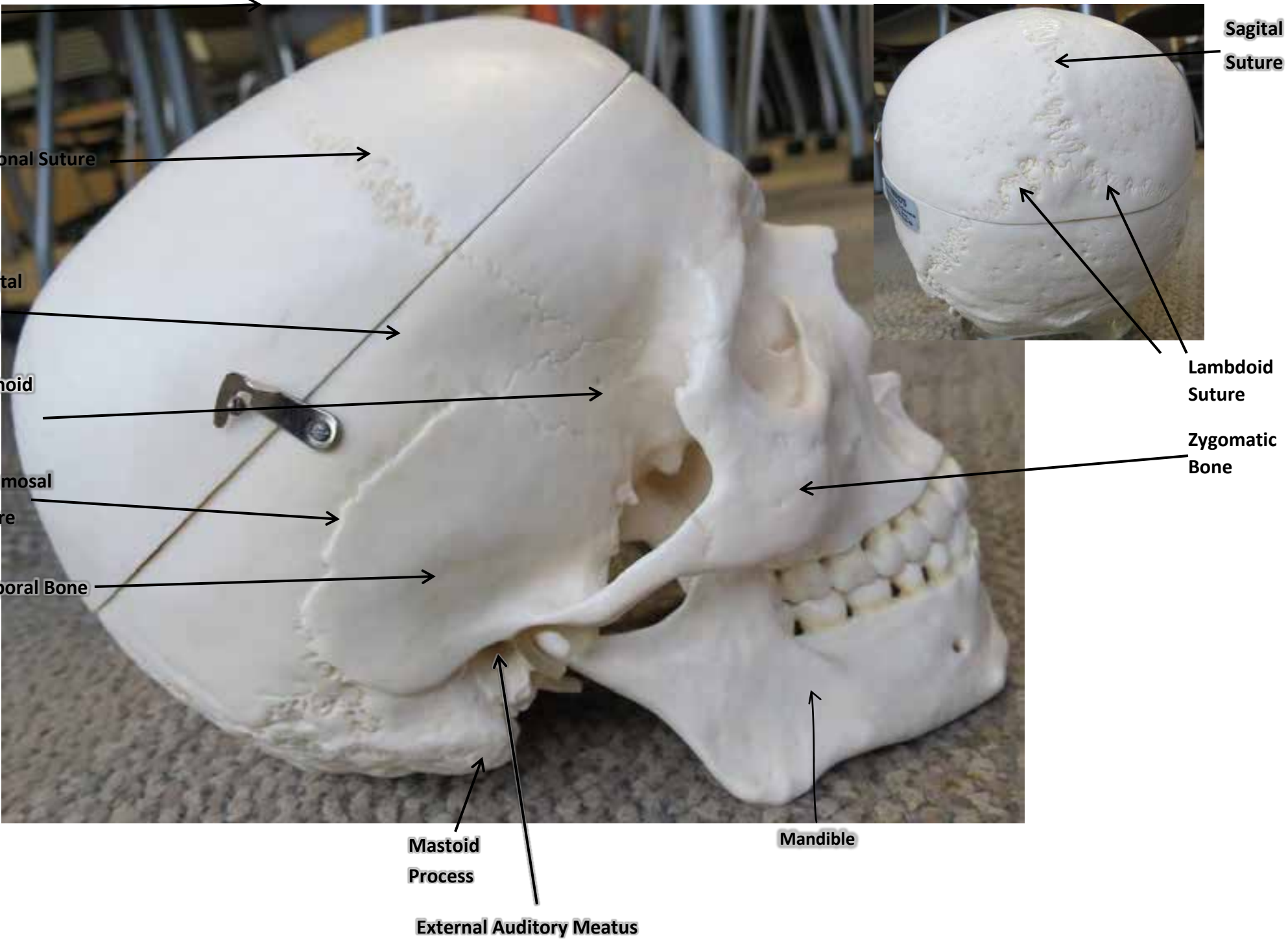


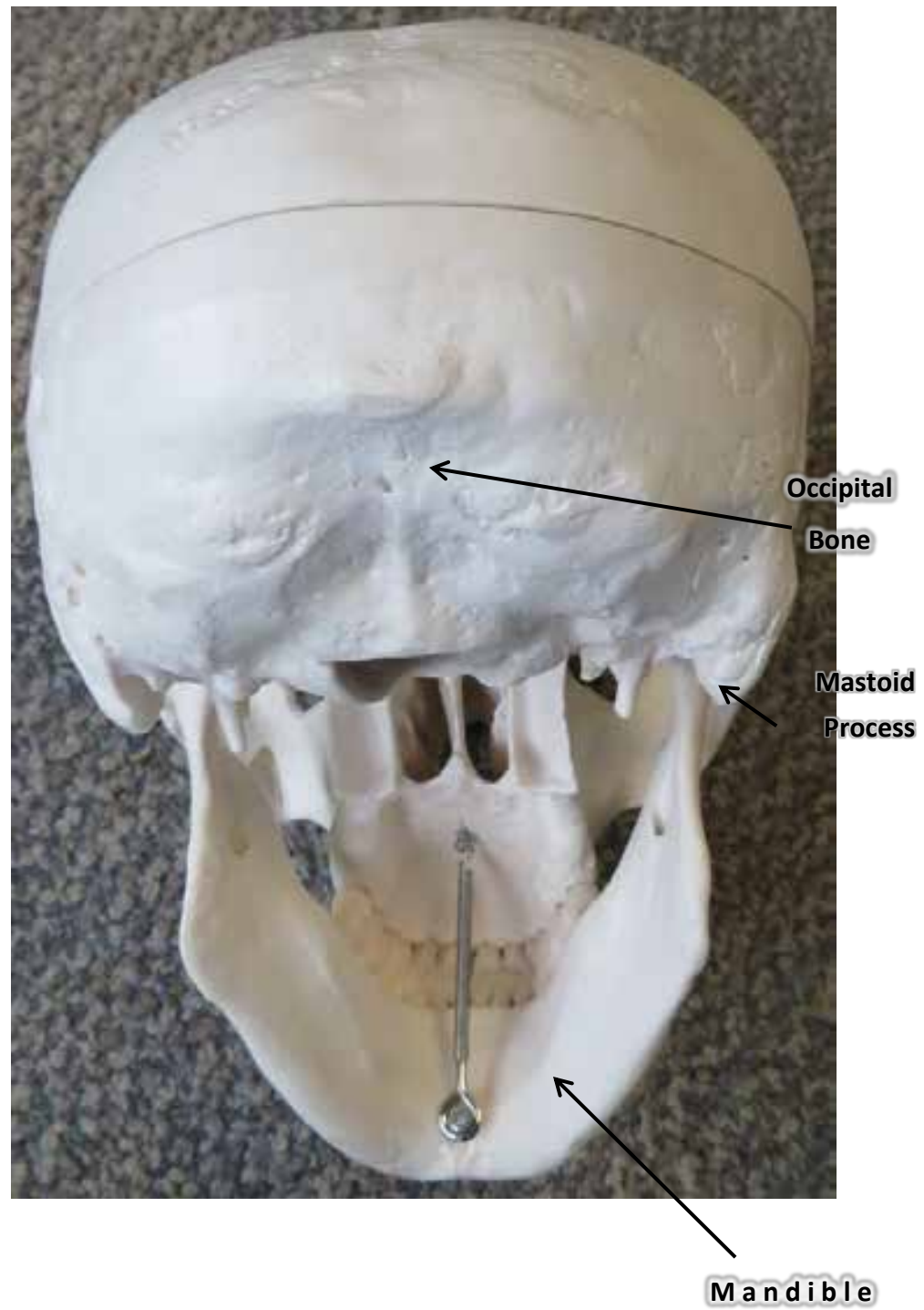
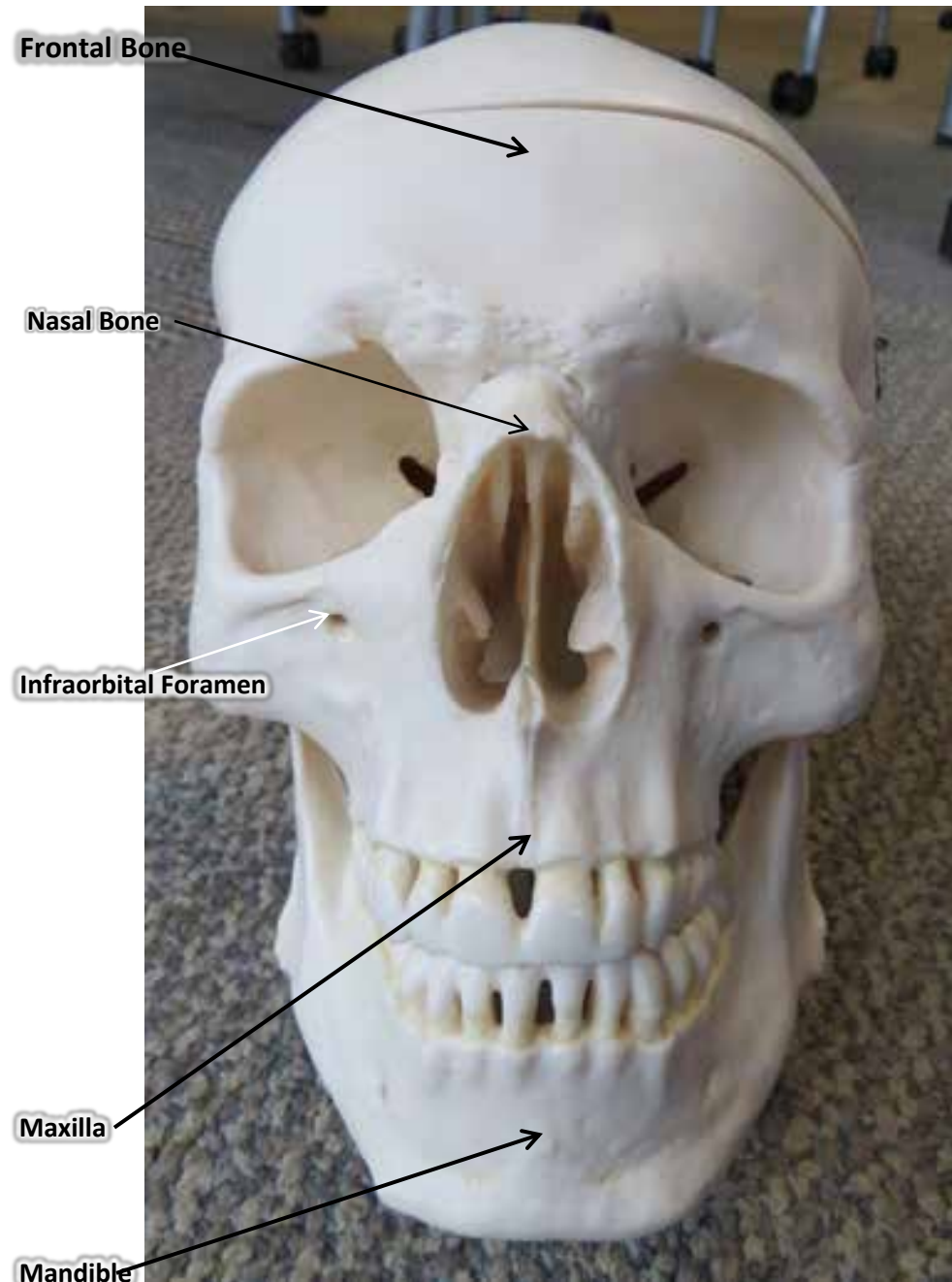
Skull Model


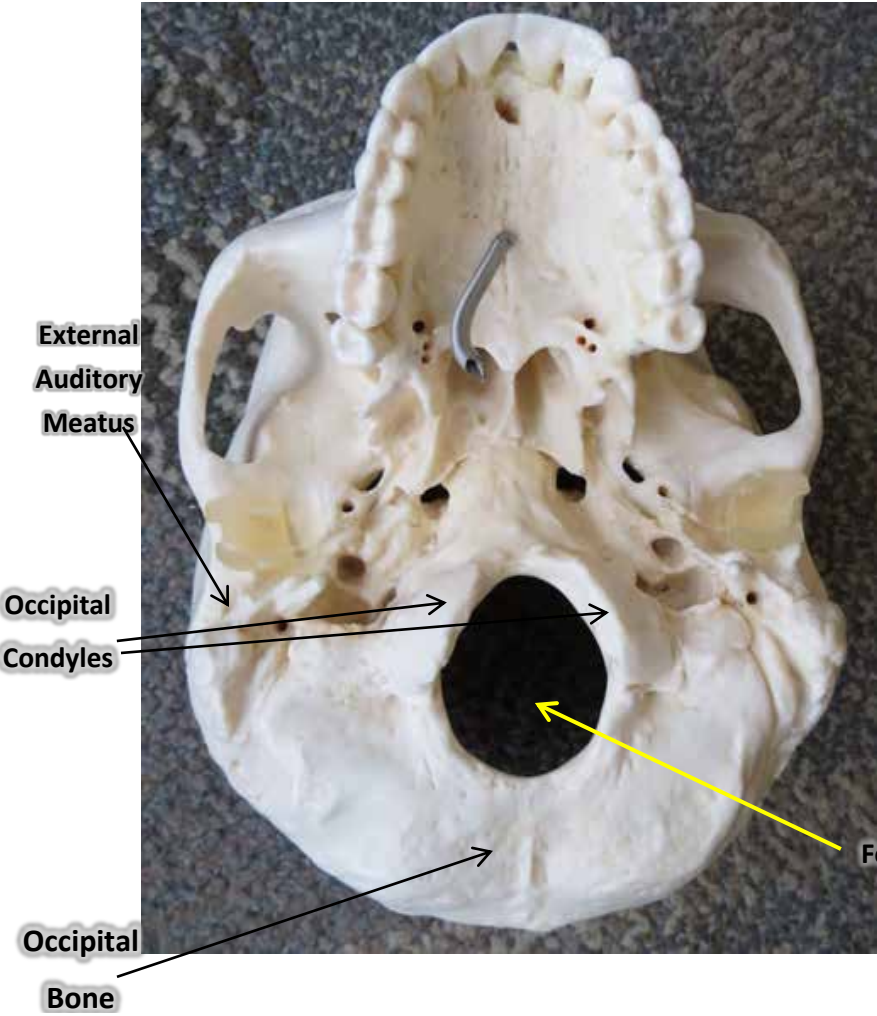


Skull Model





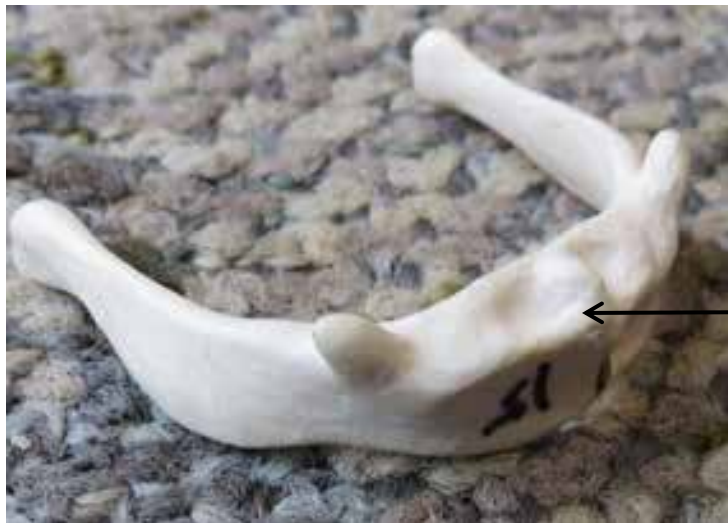



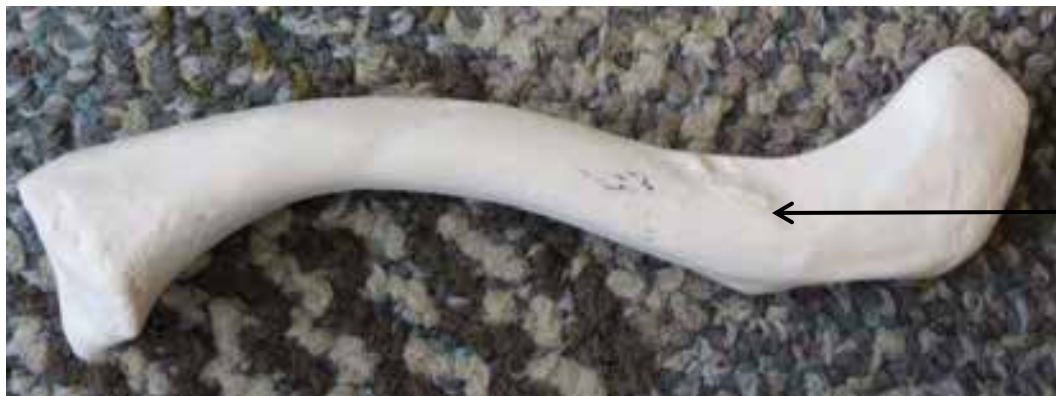PATELLA HYOID AND CLAVICLE MODEL



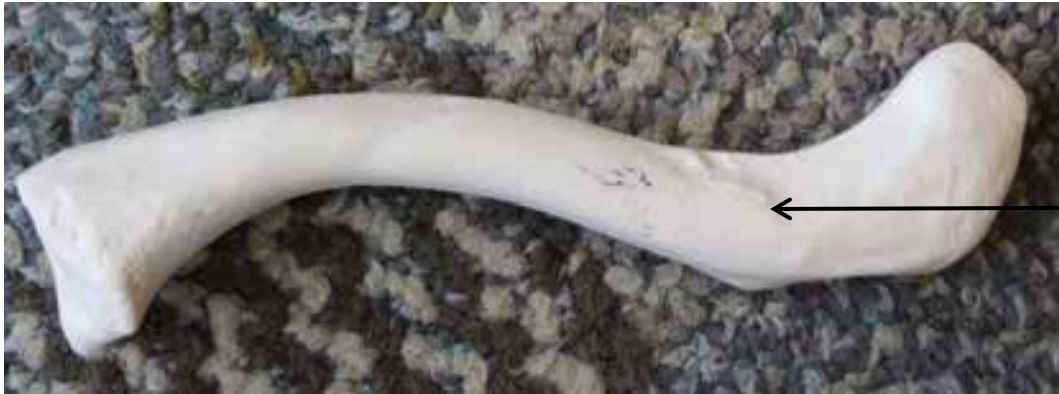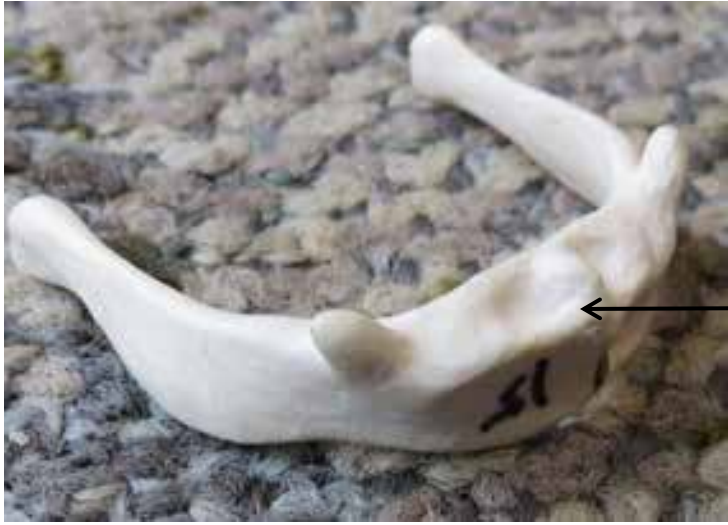Patella



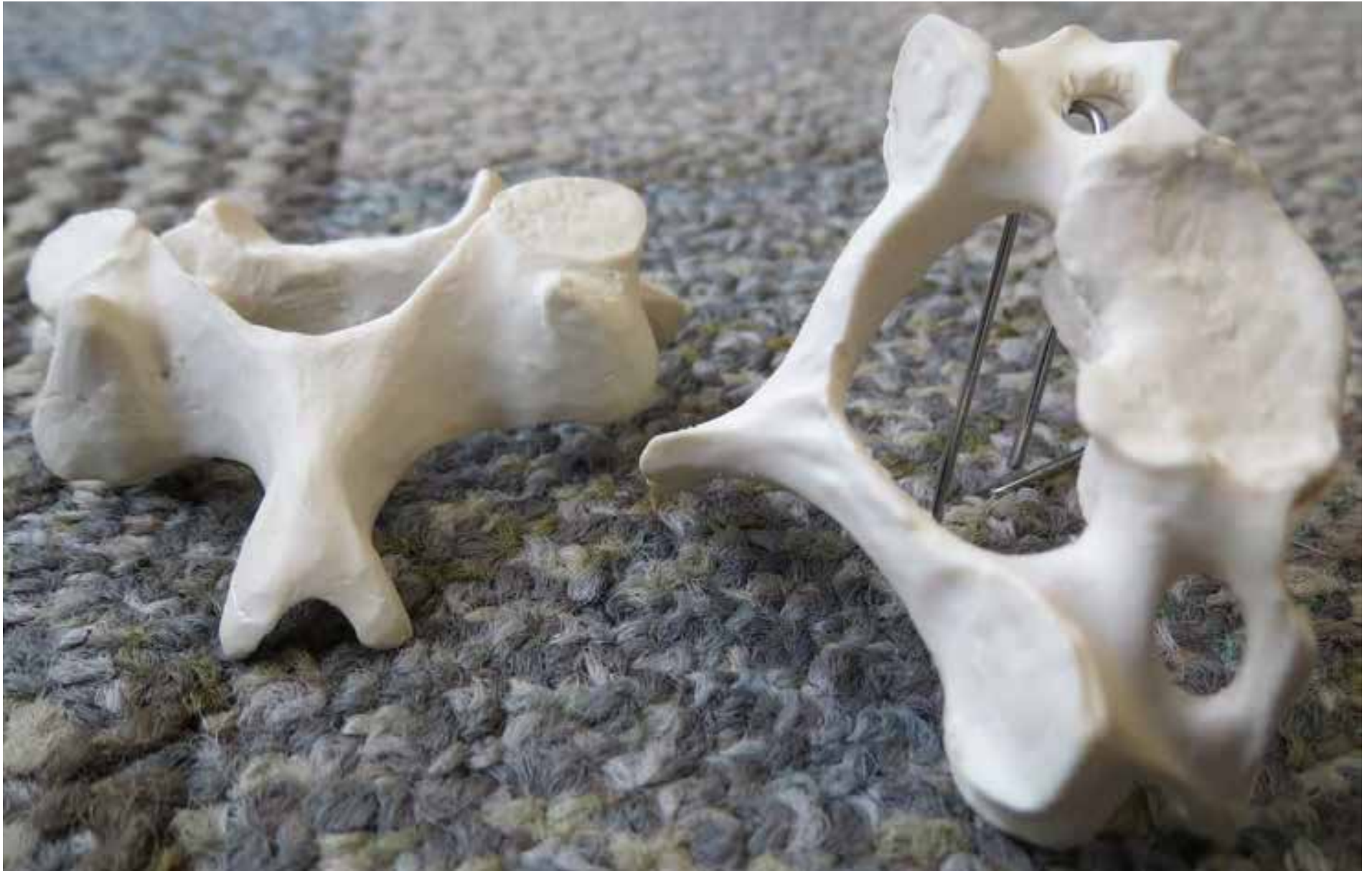Hyoid



Clavicle



Cervical Vertebrae

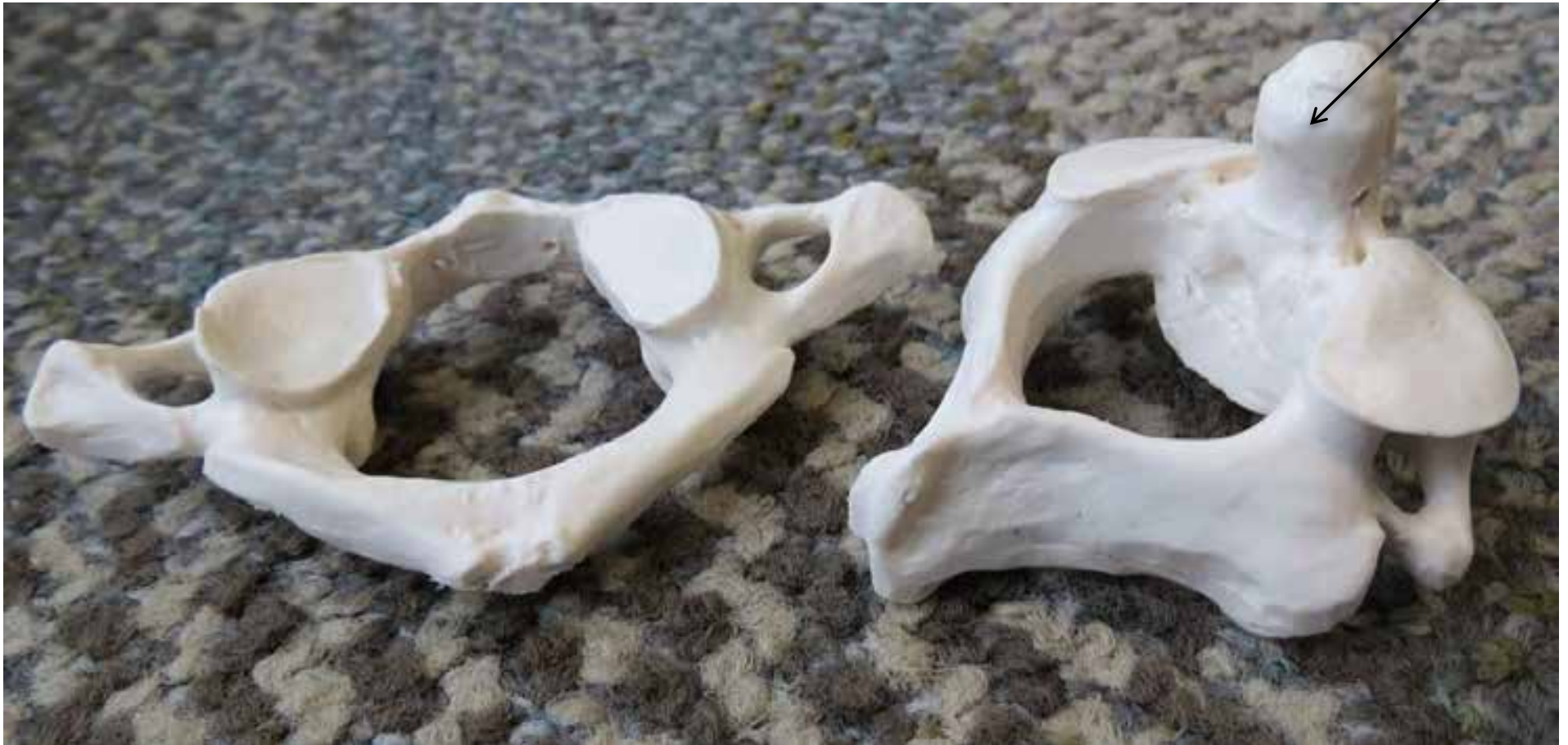

Atlas Bone

and

Axis Bone

dens



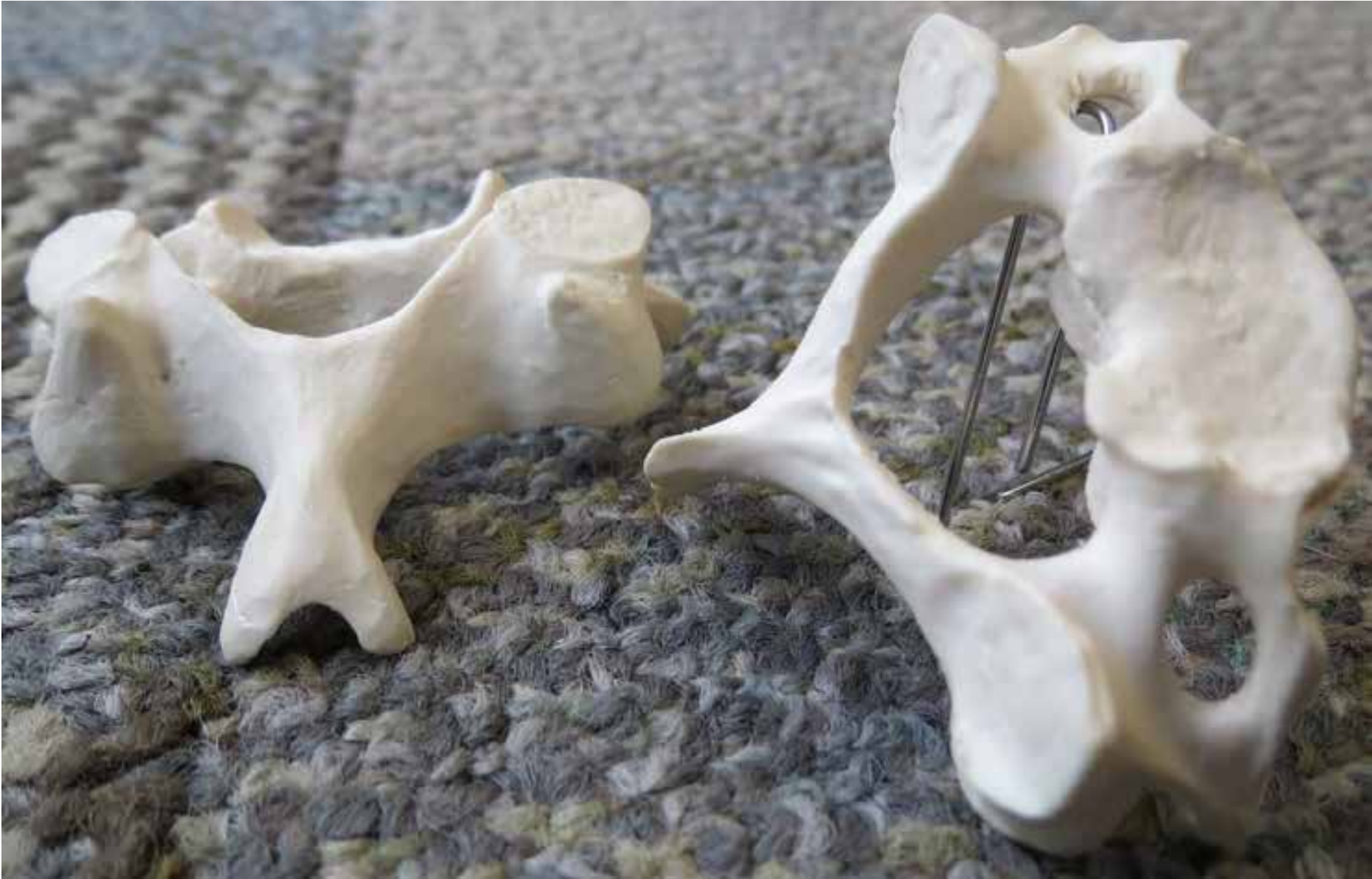(which are also Cervical Vertebrae)

Thoracic Vertebrae: have ribs attached: some say, it “looks like a giraffe” (see middle bone.)



Lumbar Vertebrae: some say “looks like a moose” (see bone on the right.)











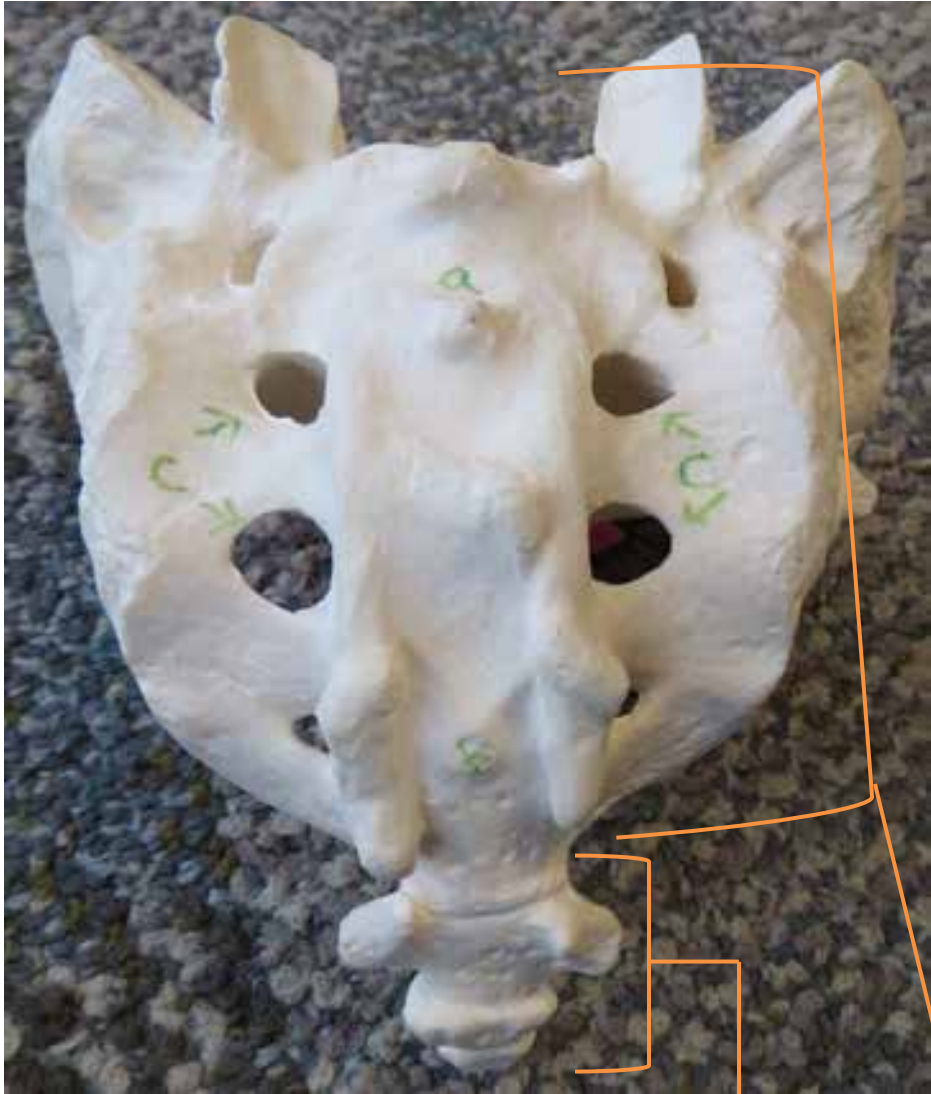

Sacrum bone



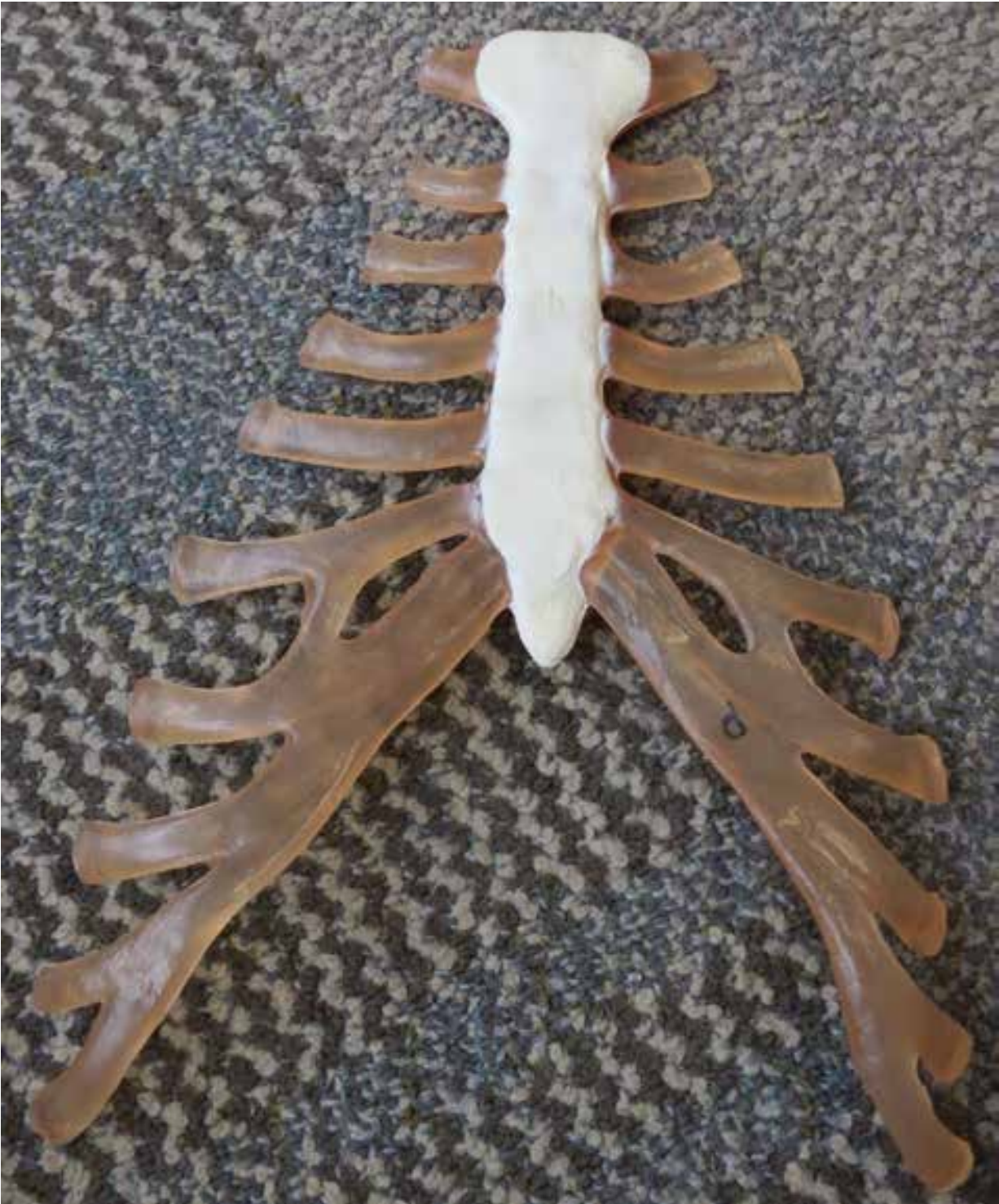Sacrum

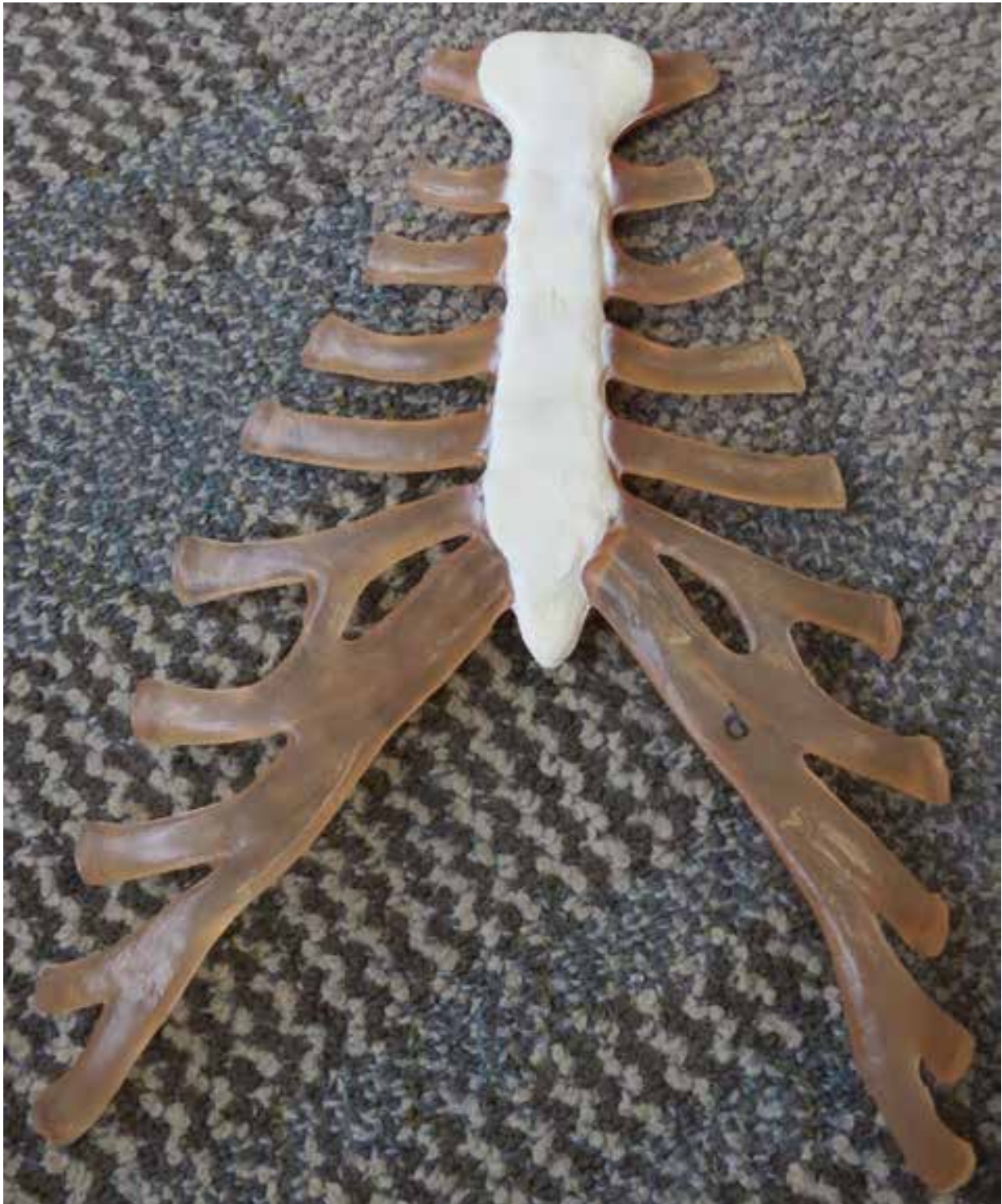Coccyx

Coccyx



STERNUM





Various Ribs





Scapula



Spine

**Glenoid
Cavity**



Humerus

Head



Head





Radius

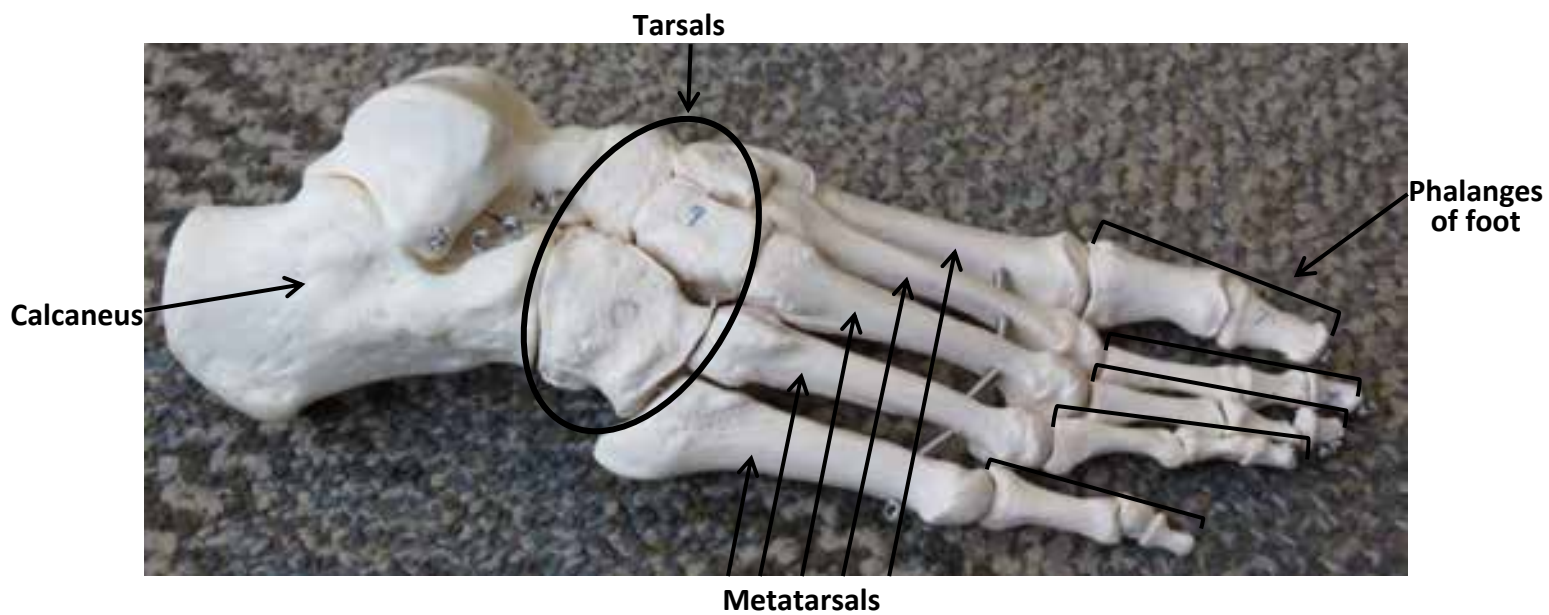
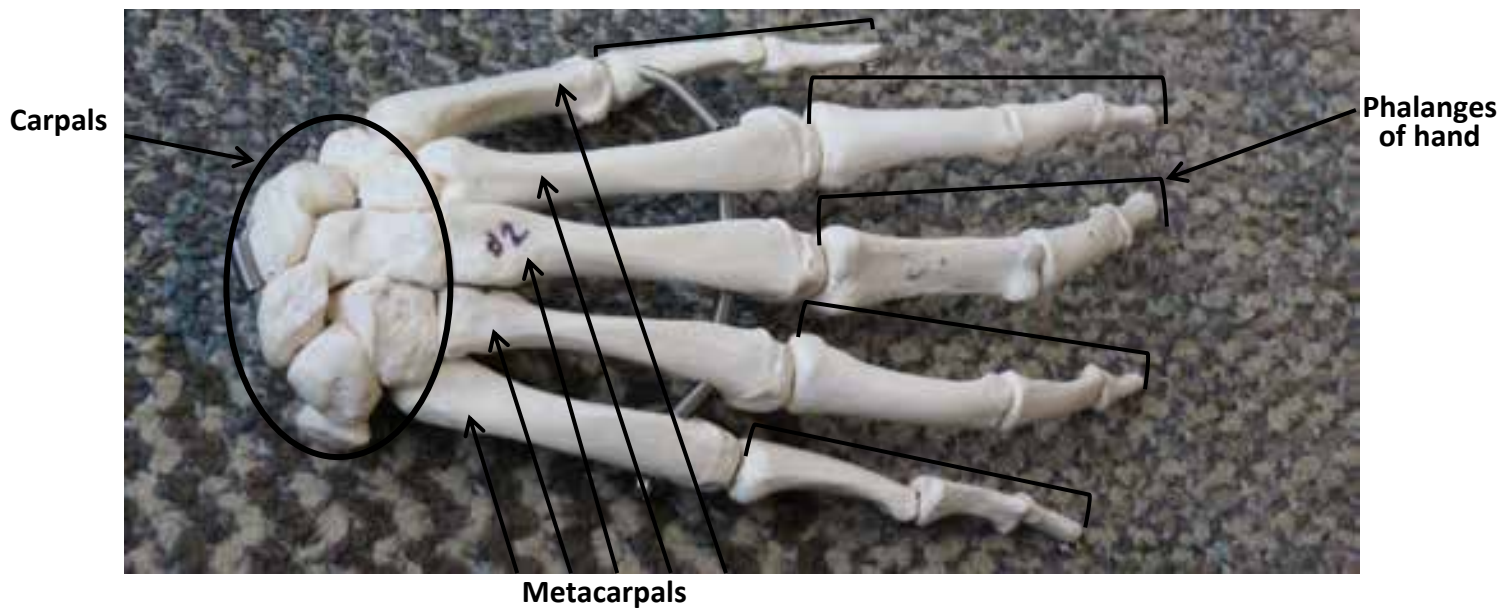


Ulna

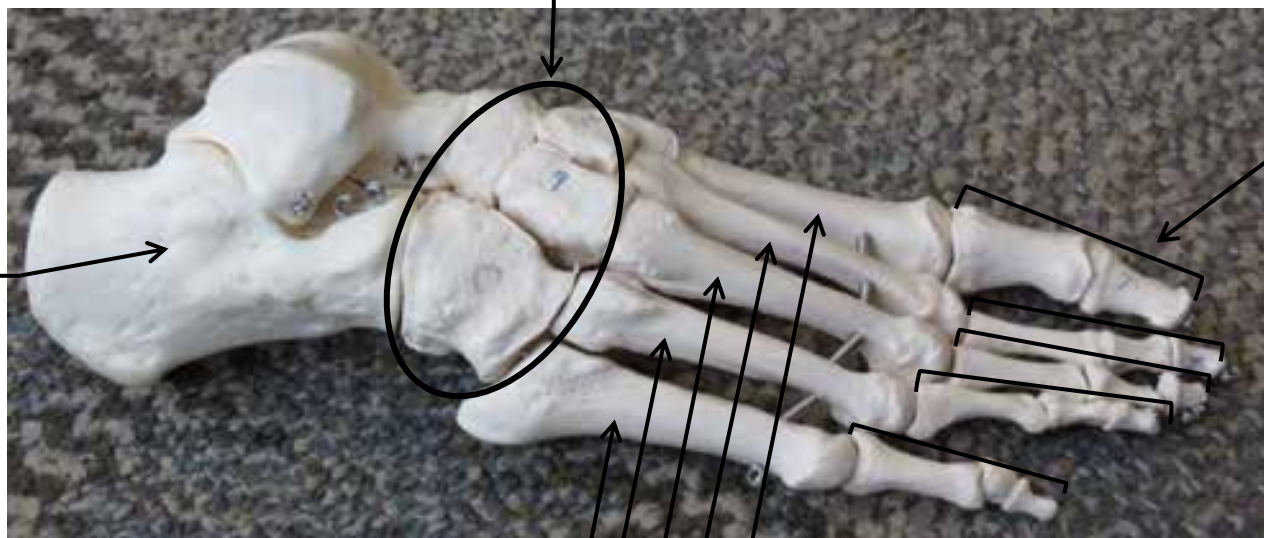
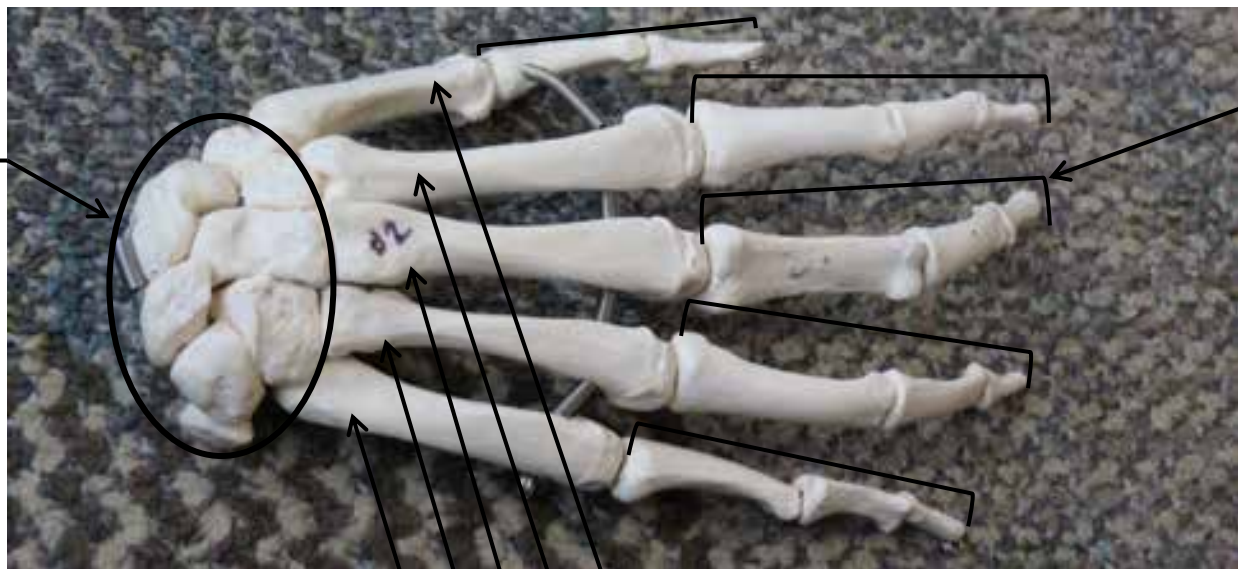



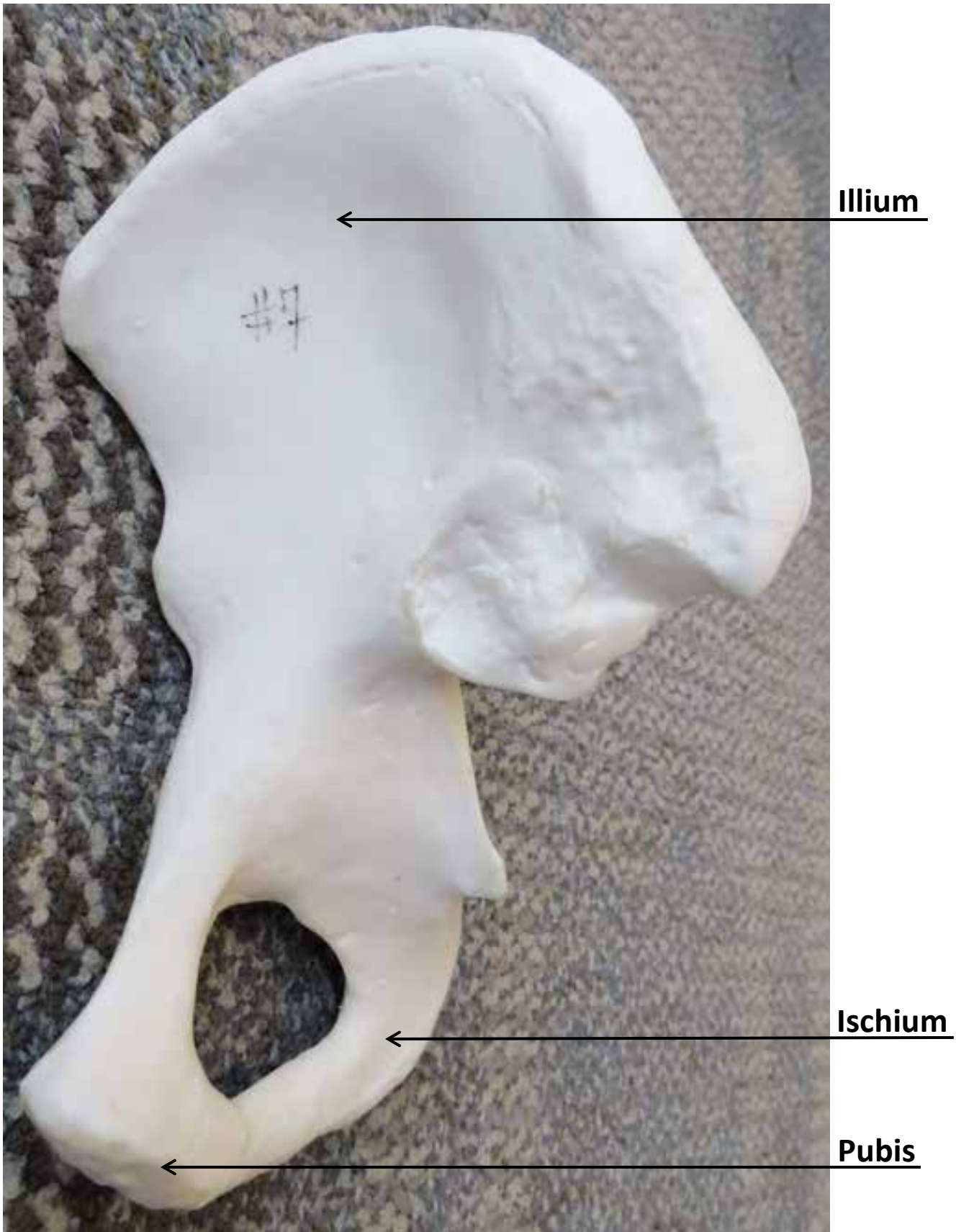
HAND AND FOOT BONE MODEL



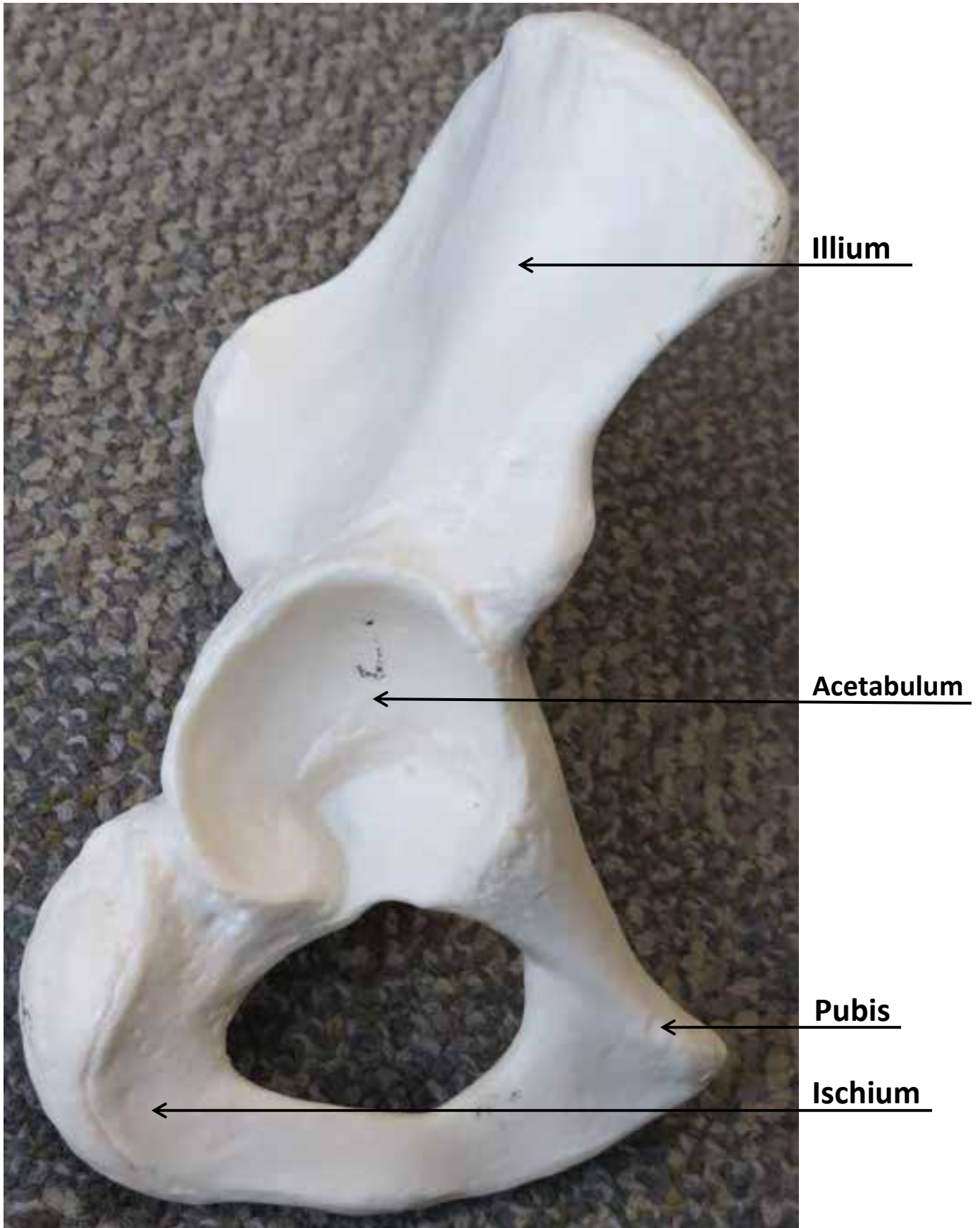
HAND AND FOOT BONE MODEL

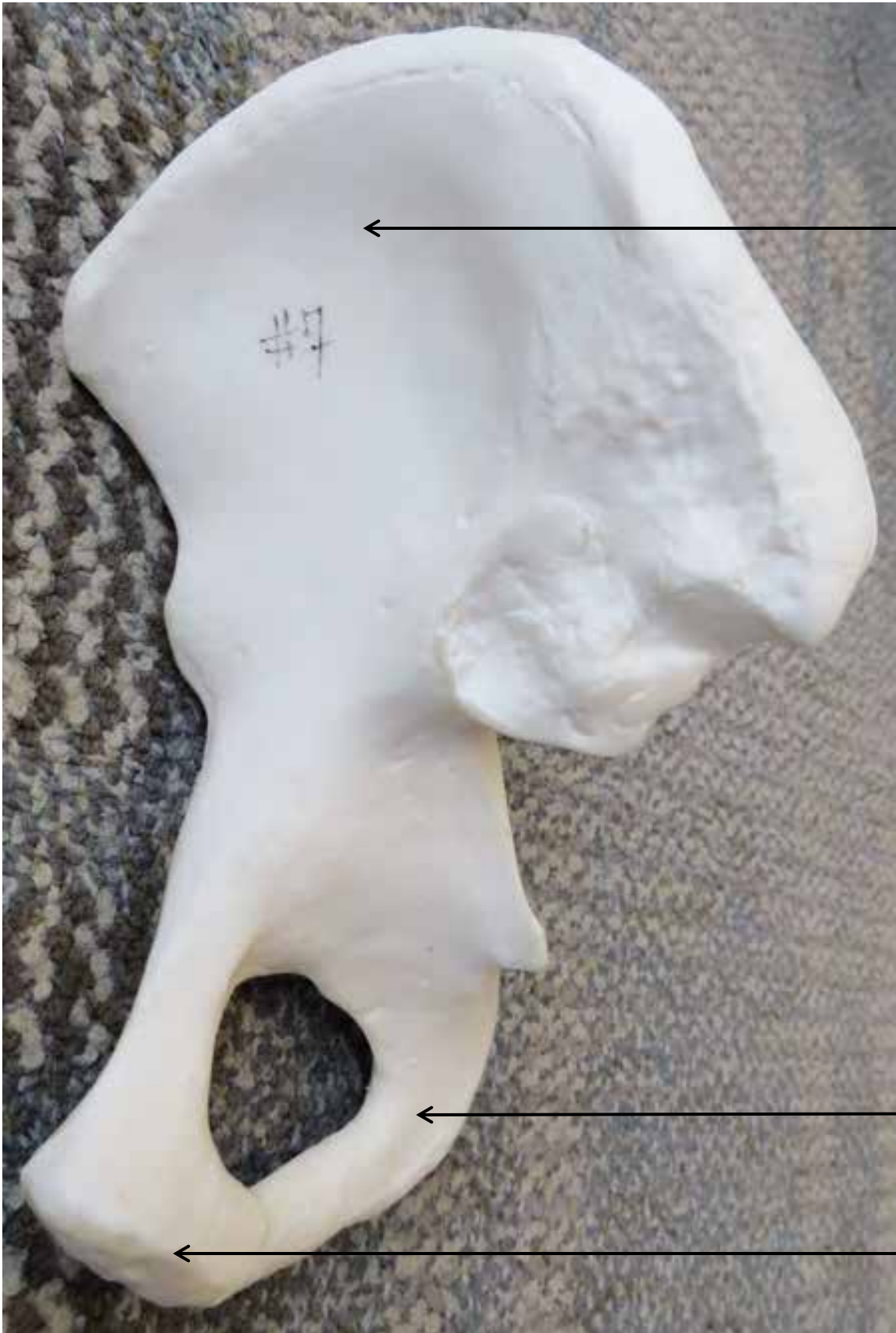

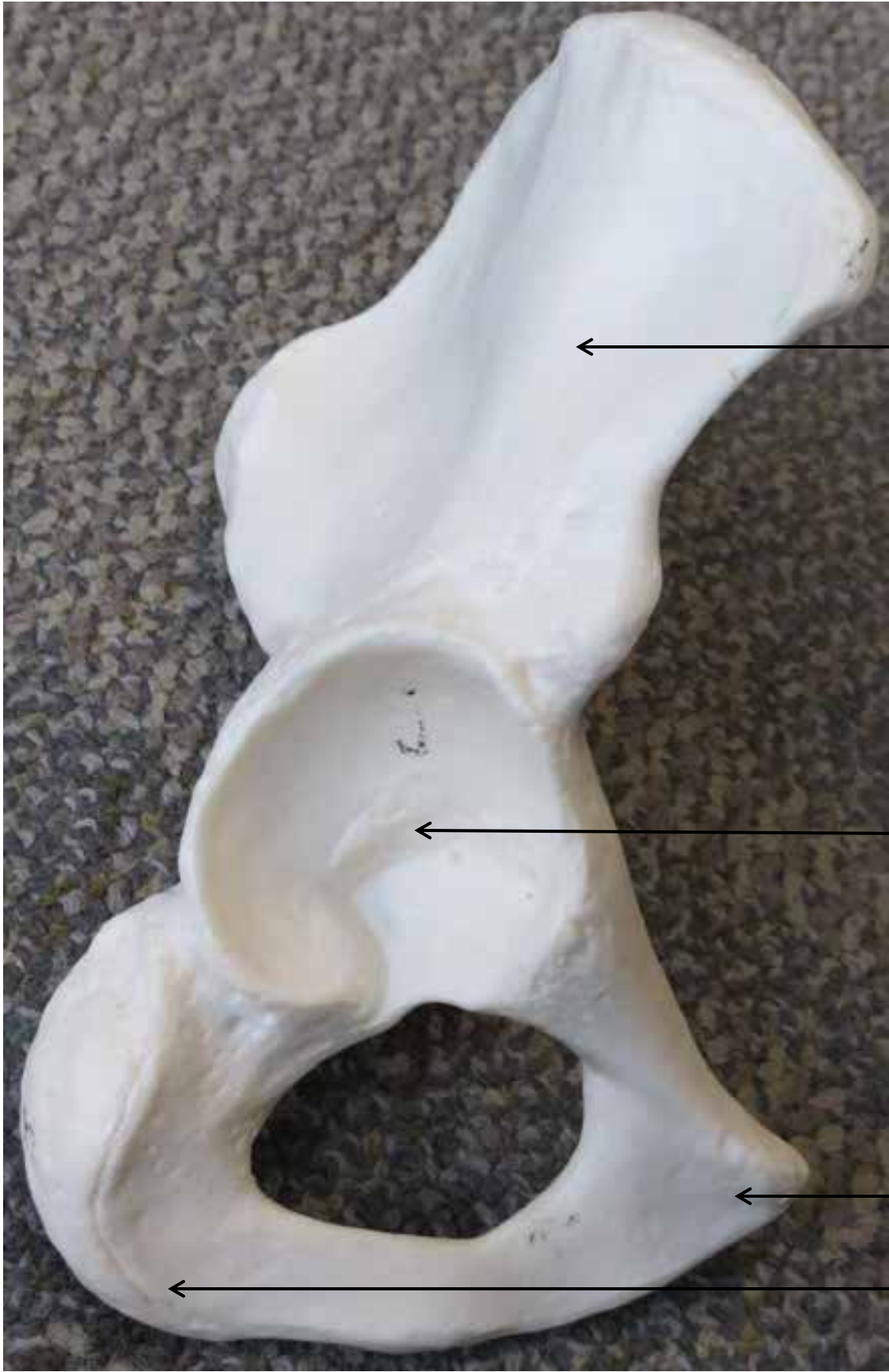
Coxal Bone Model



Coxal Bone Model







Femur Bone



Head

Neck



Head

Neck



Fibula

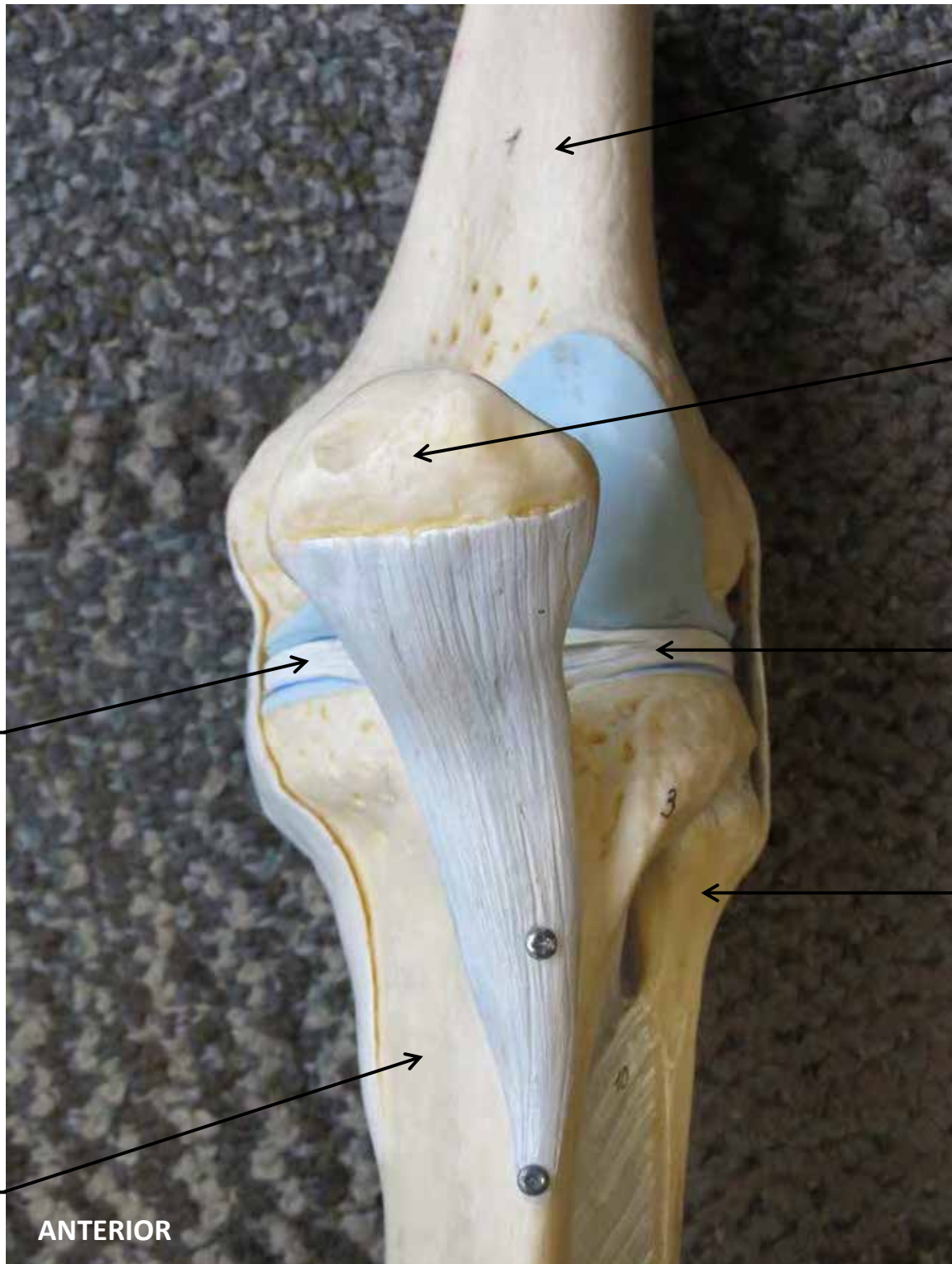


Tibia





KNEE JOINT MODEL



Femur

Patella

Lateral
Meniscus

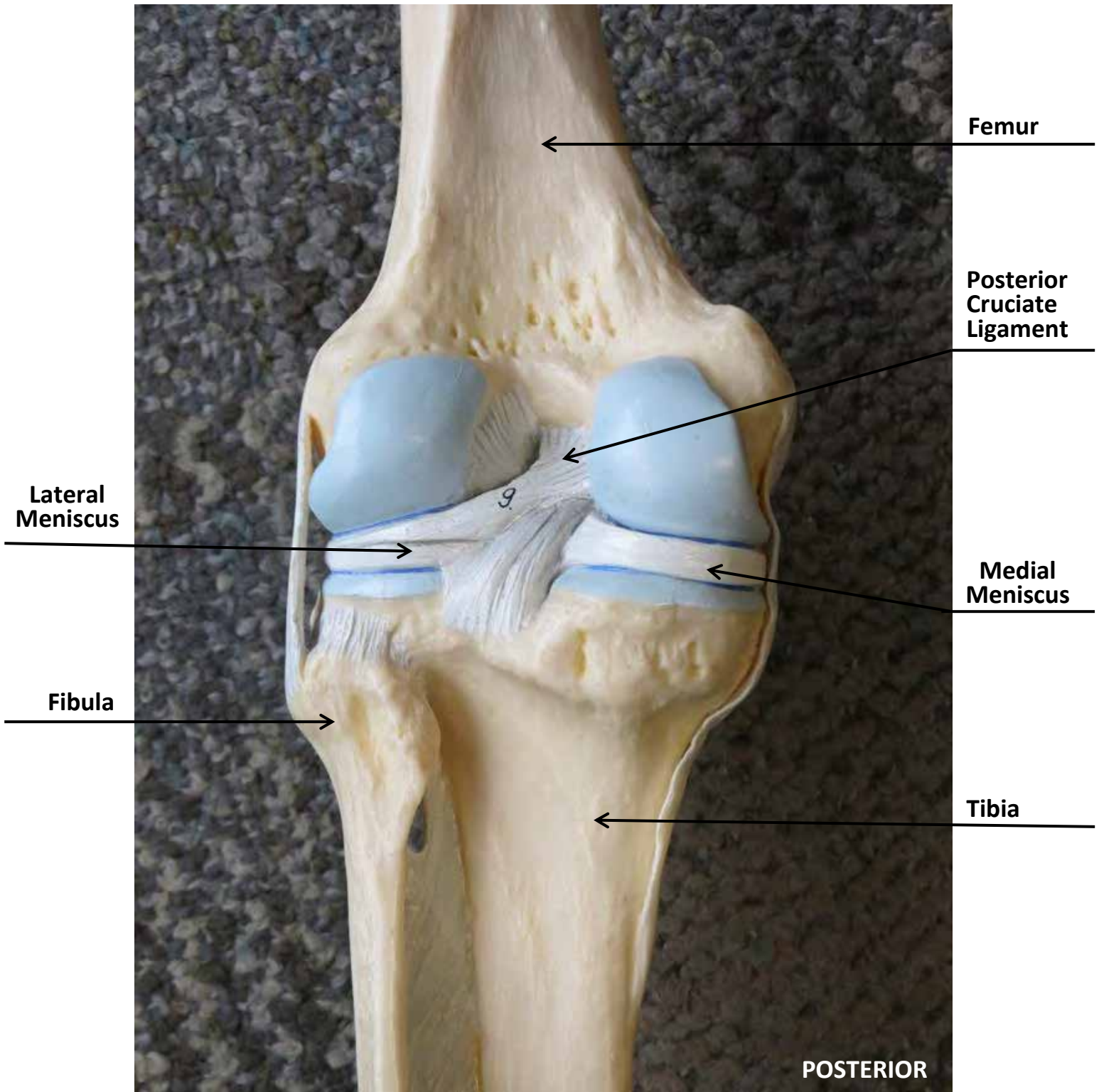
Medial
Meniscus

Fibula

Tibia

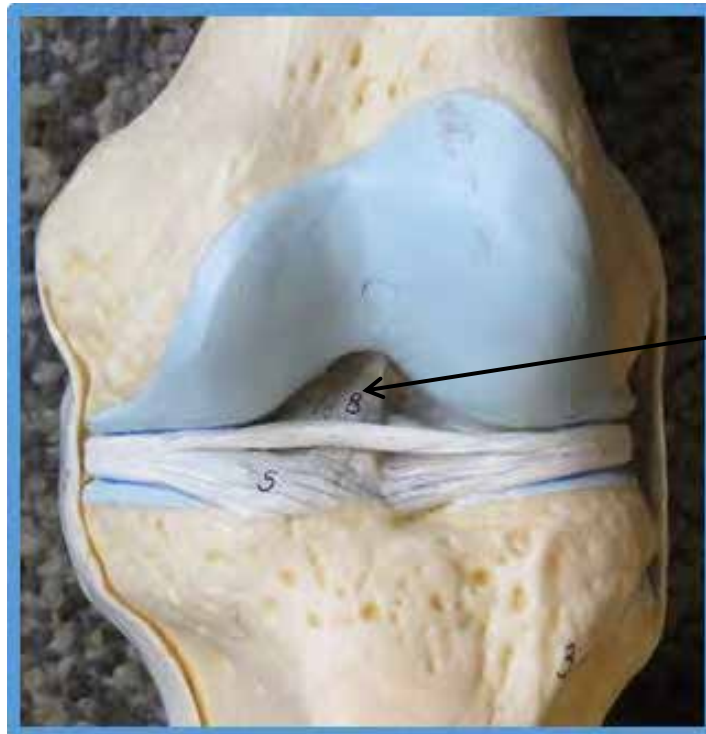
ANTERIOR

KNEE JOINT MODEL



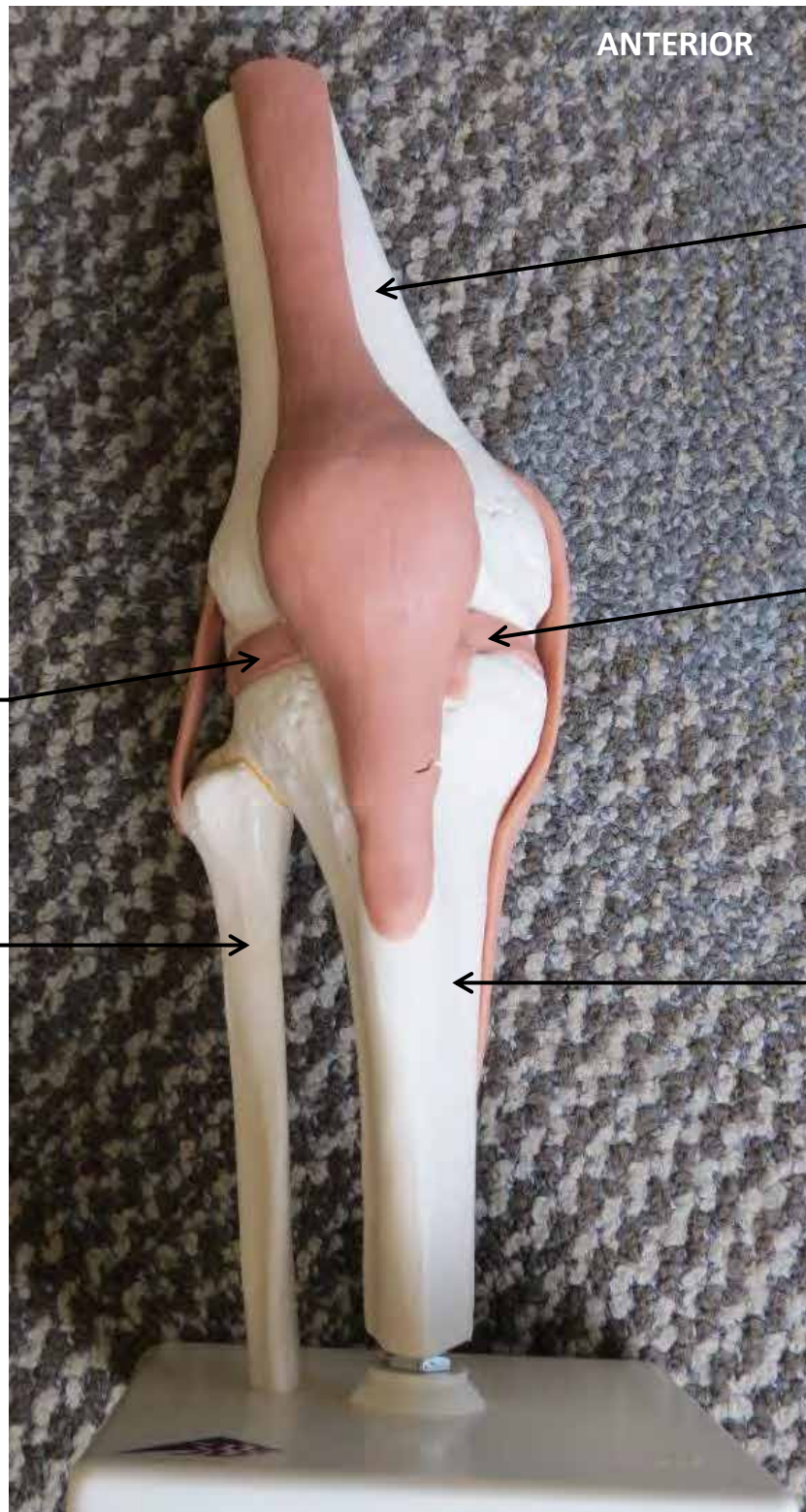KNEE JOINT MODEL

**ANTERIOR
(beneath patella)**



**Anterior Cruciate
Ligament**

KNEE JOINT MODEL



ANTERIOR

Femur

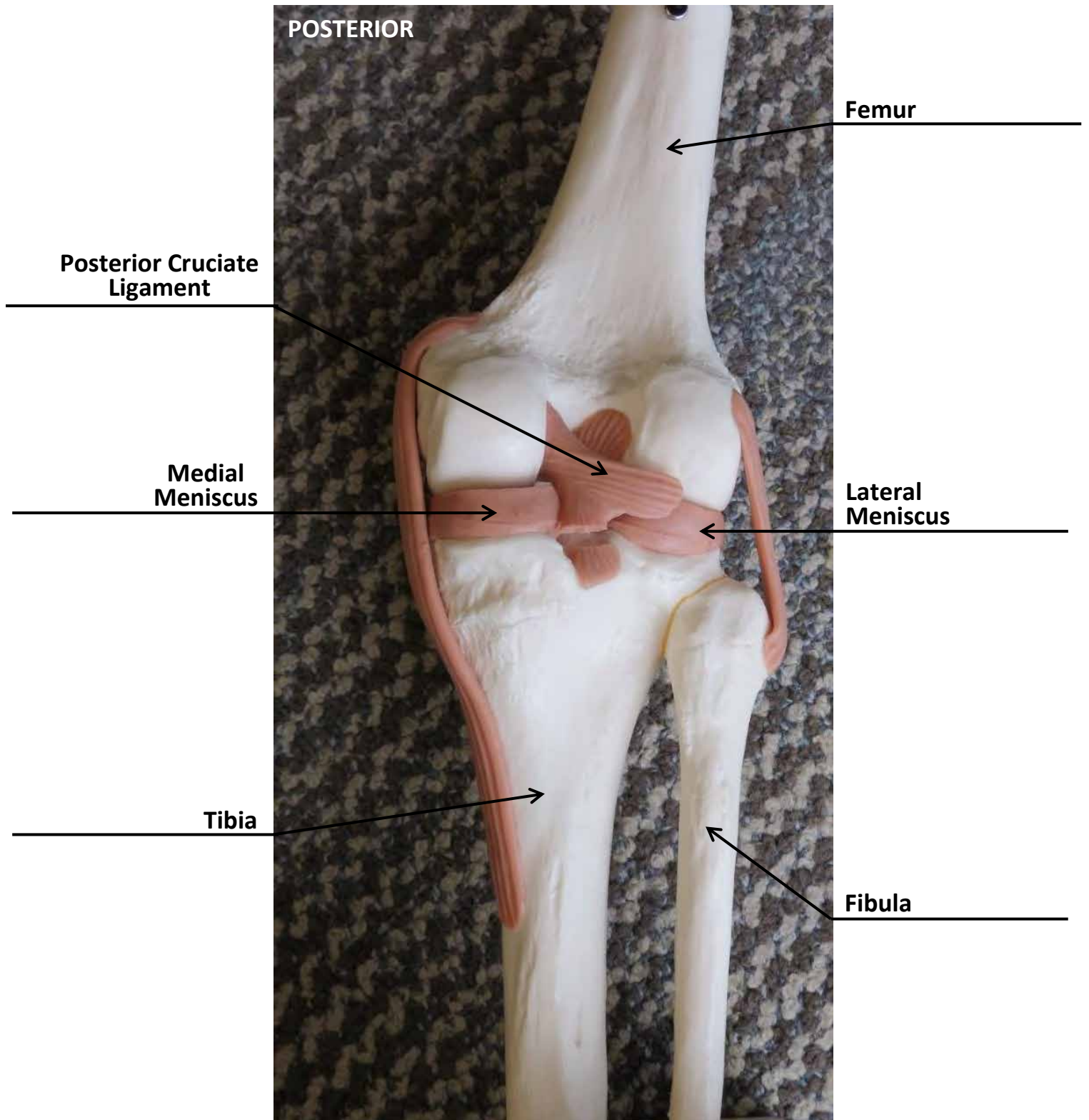
Medial
Meniscus

Lateral
Meniscus

Fibula

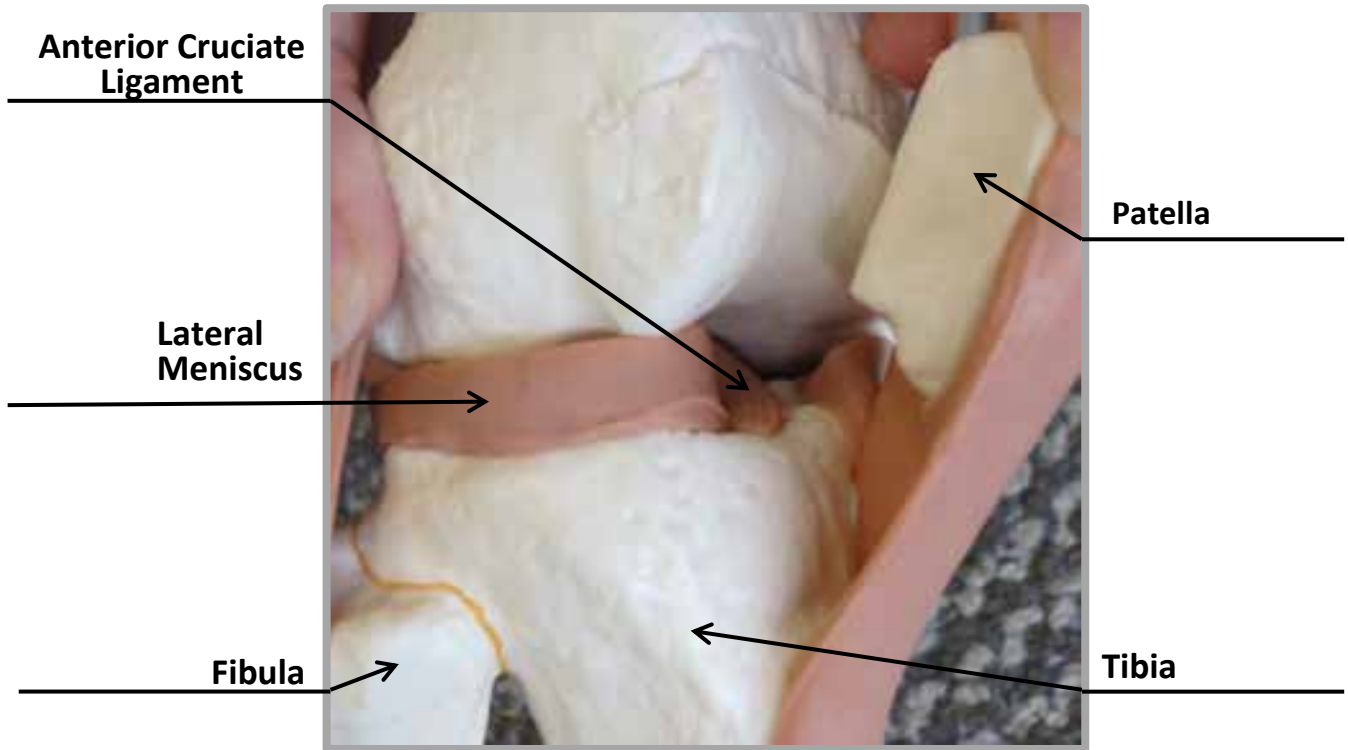
Tibia

KNEE JOINT MODEL

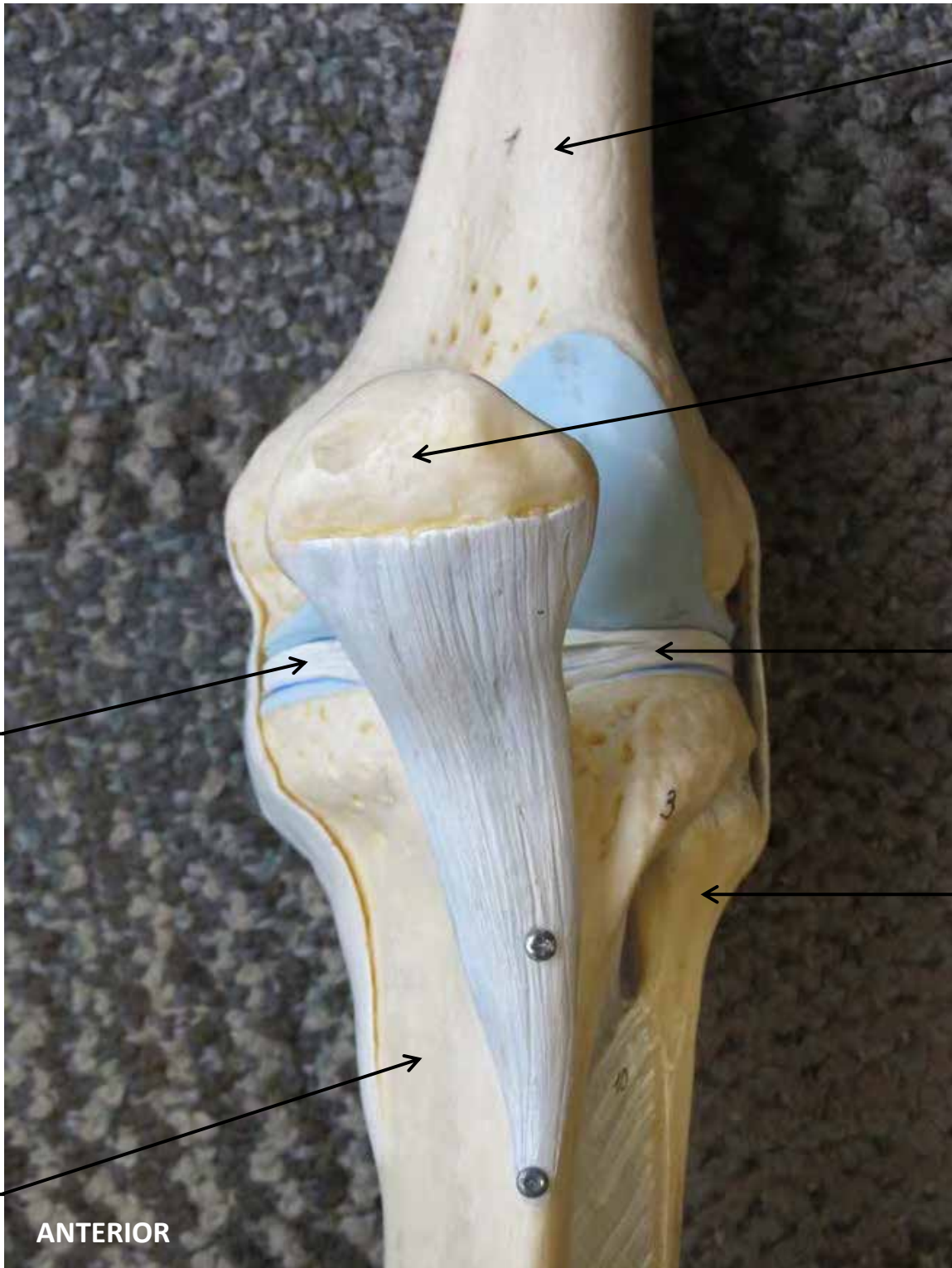


KNEE JOINT MODEL

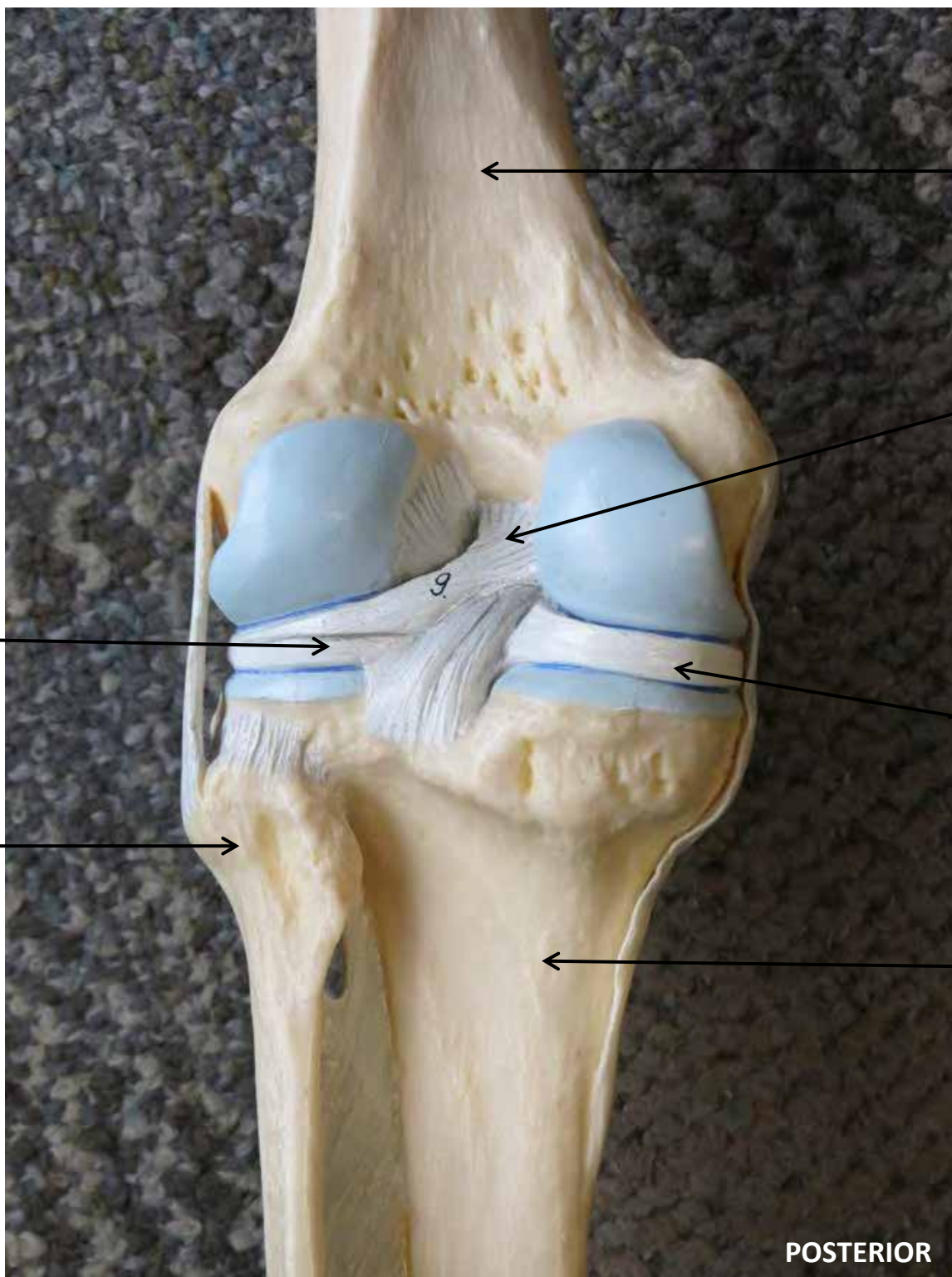
ANTERIOR
(beneath patella)



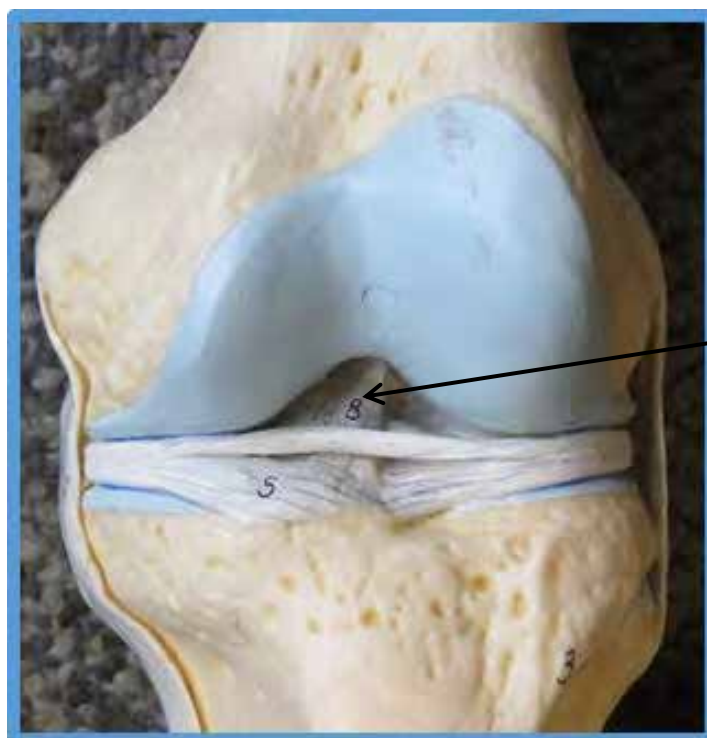
KNEE JOINT MODEL



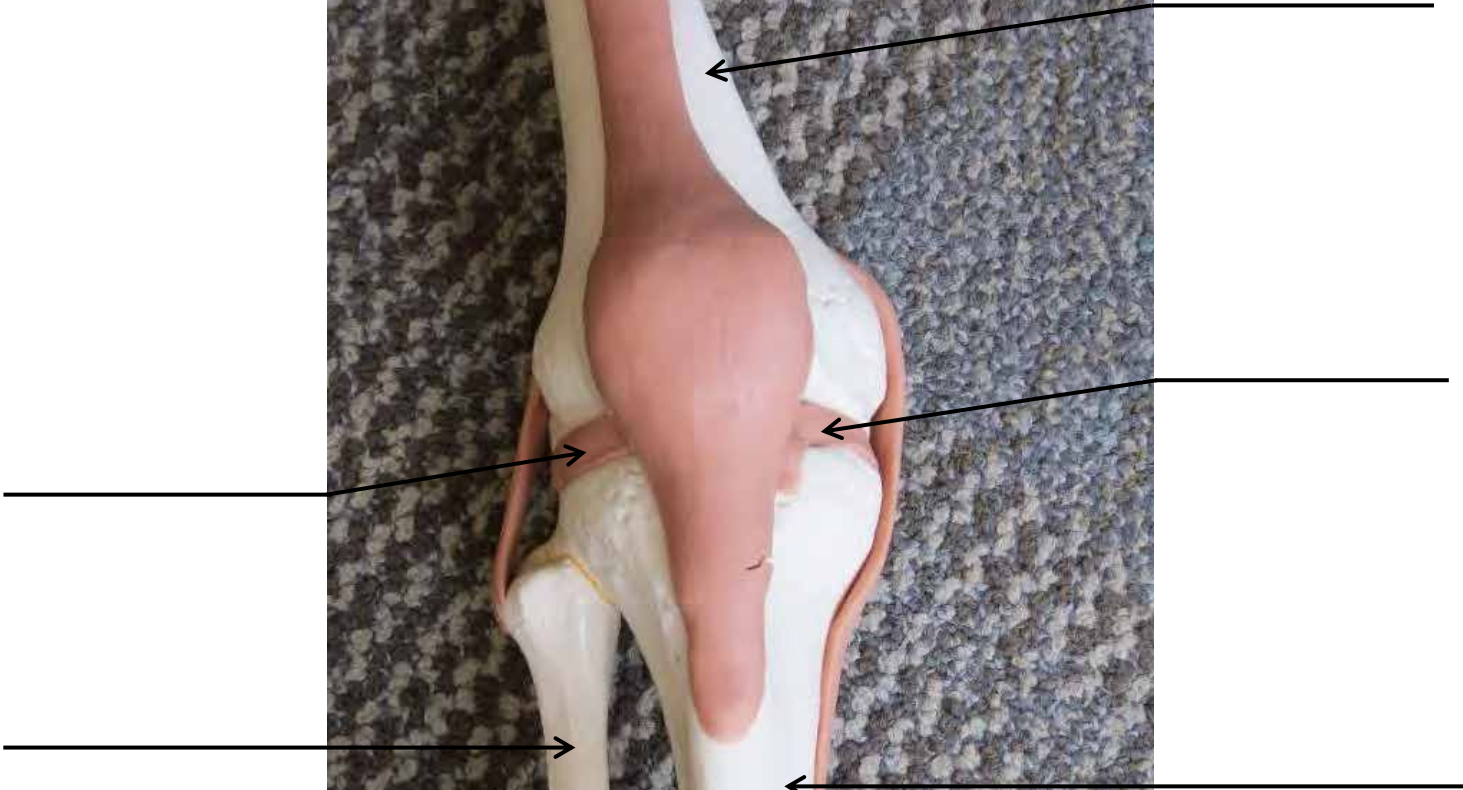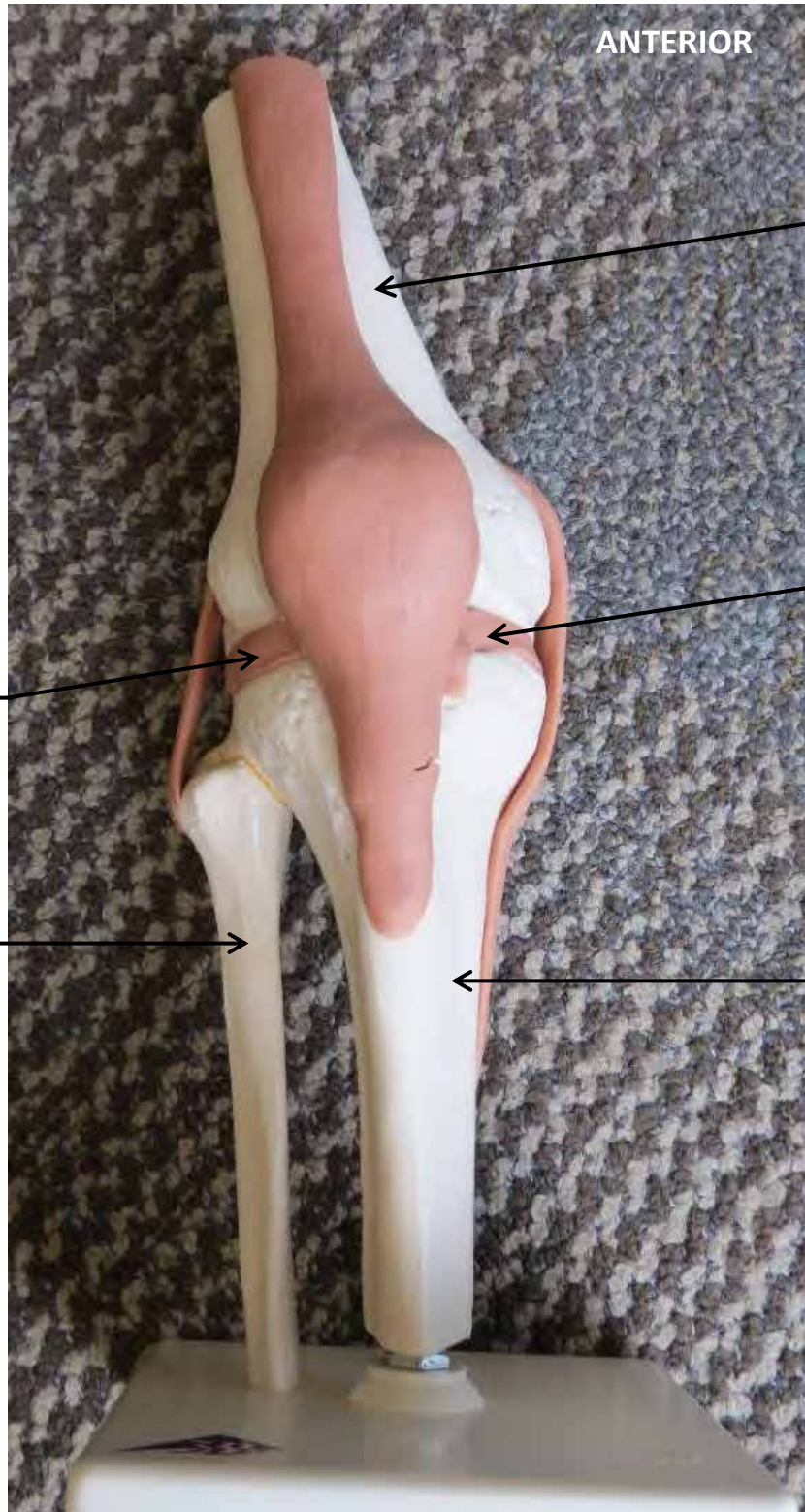KNEE JOINT MODEL



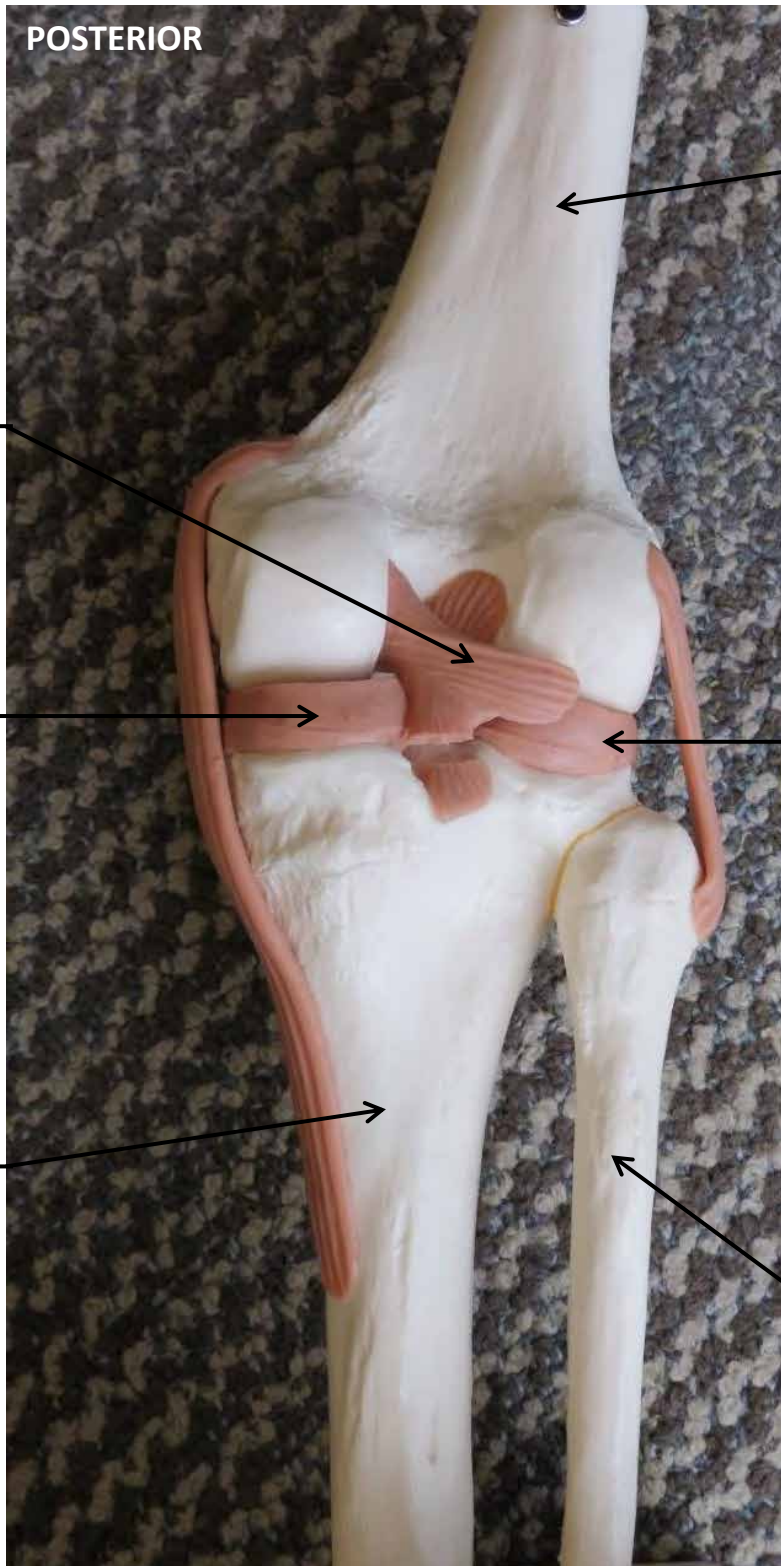
KNEE JOINT MODEL



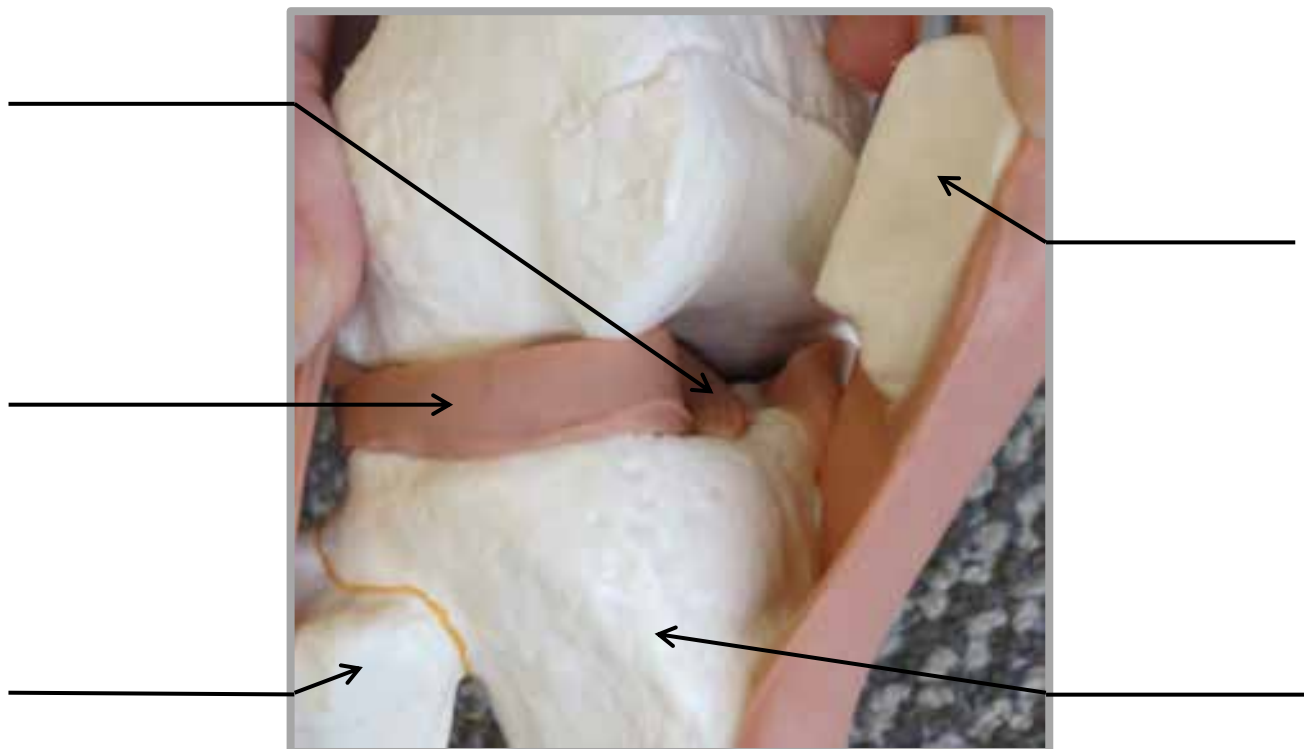
KNEE JOINT MODEL



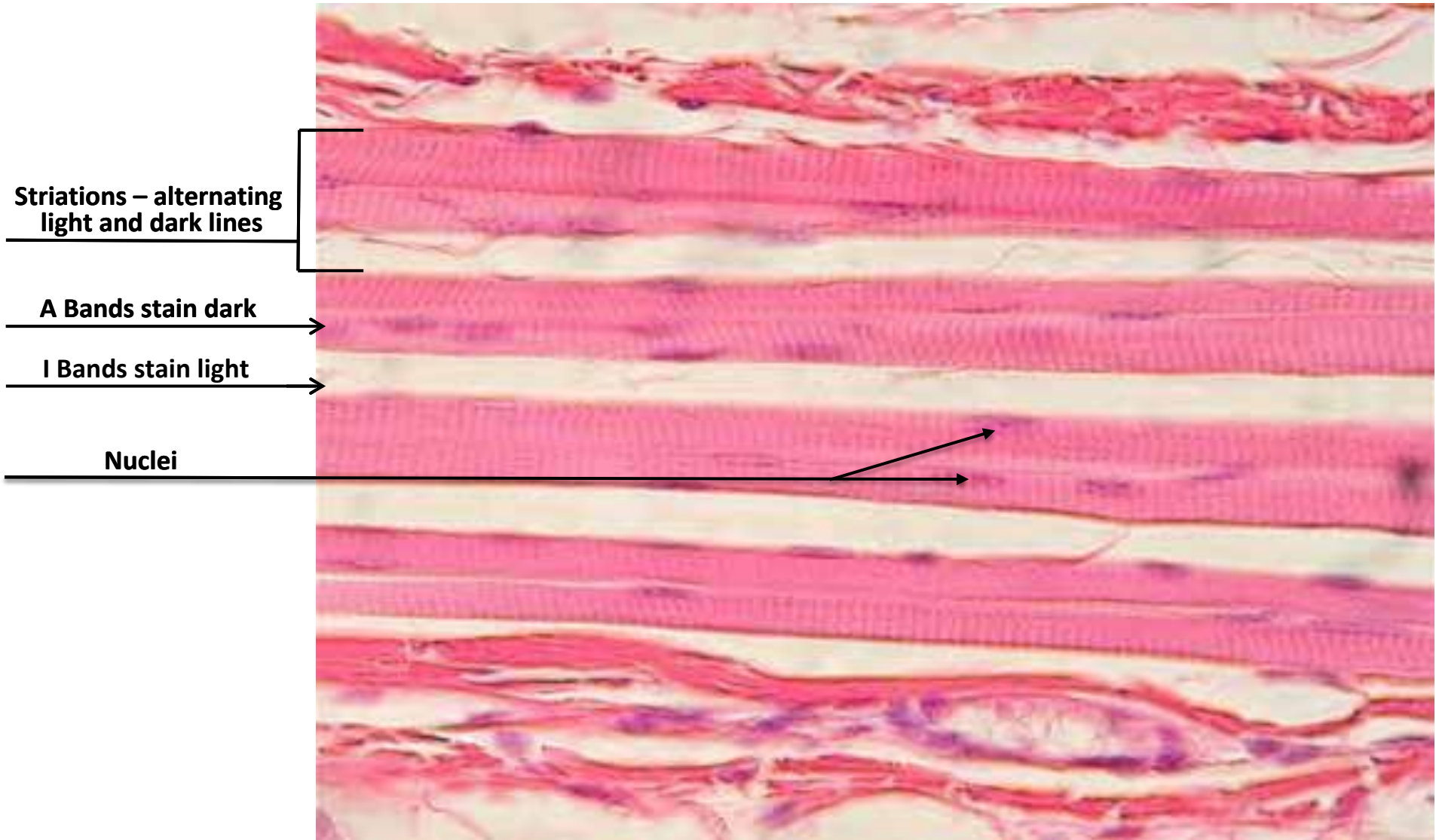
KNEE JOINT MODEL



KNEE JOINT MODEL



SKELETAL MUSCLE SLIDE

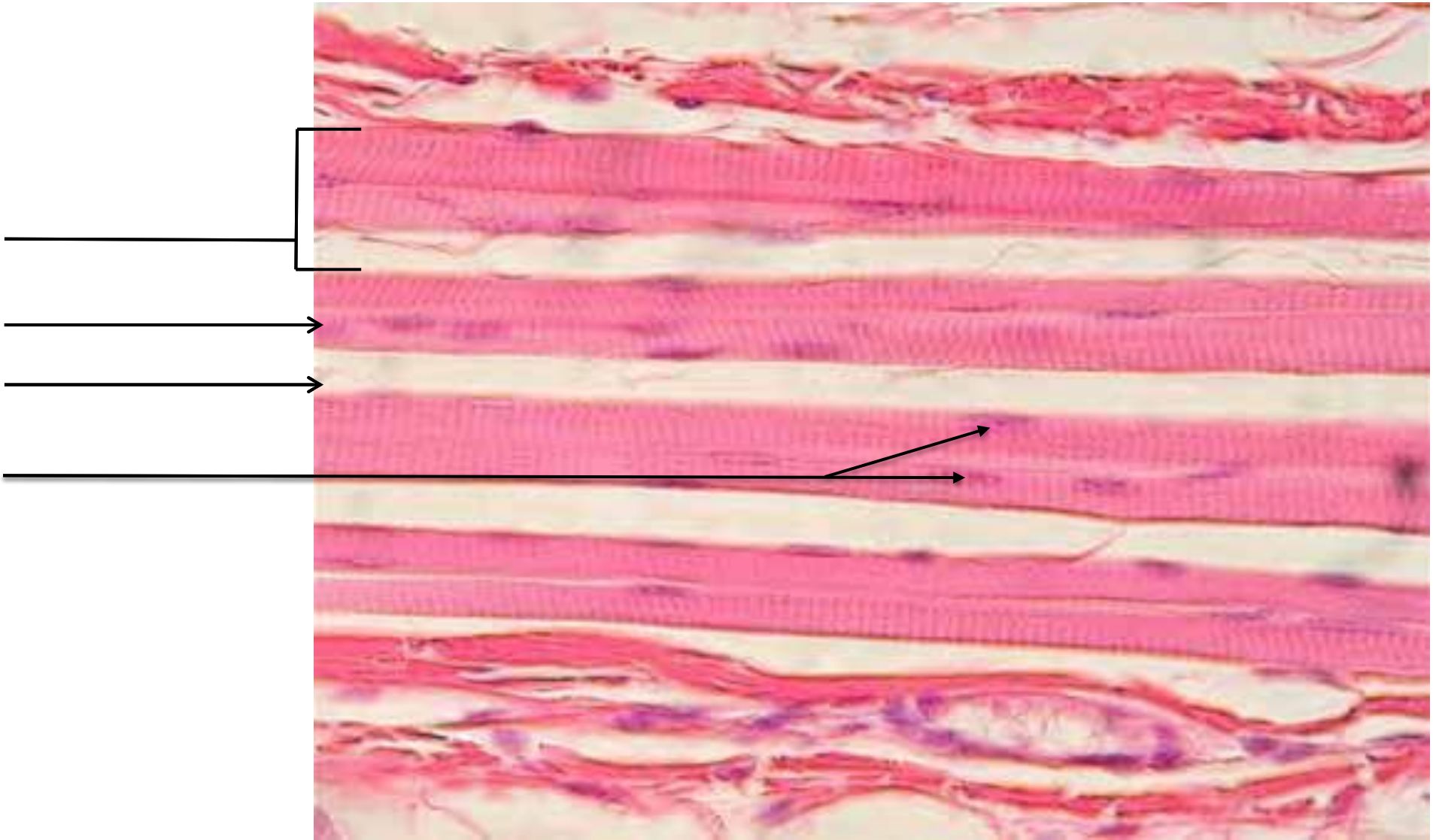


Striations – alternating light and dark lines

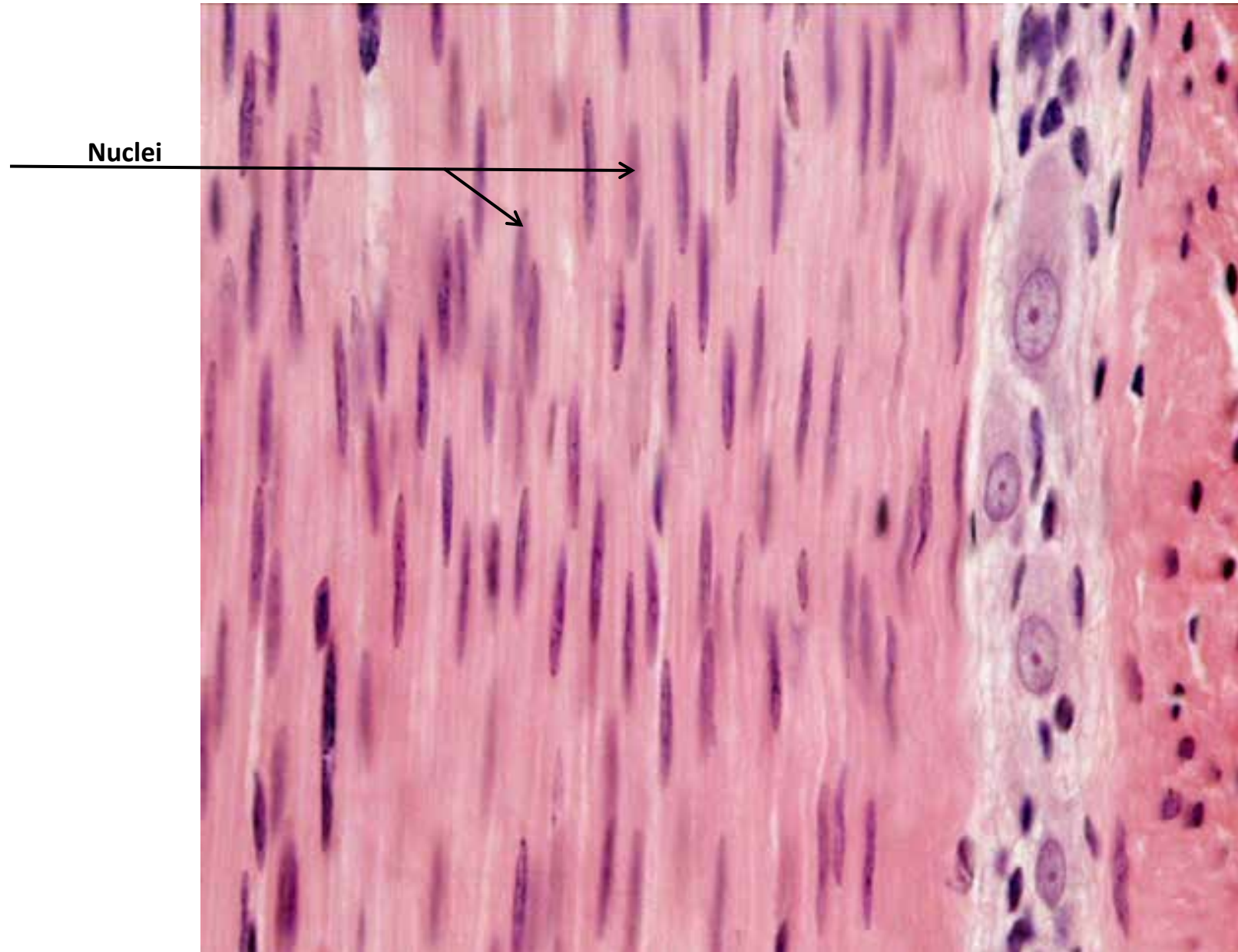
A Bands stain dark

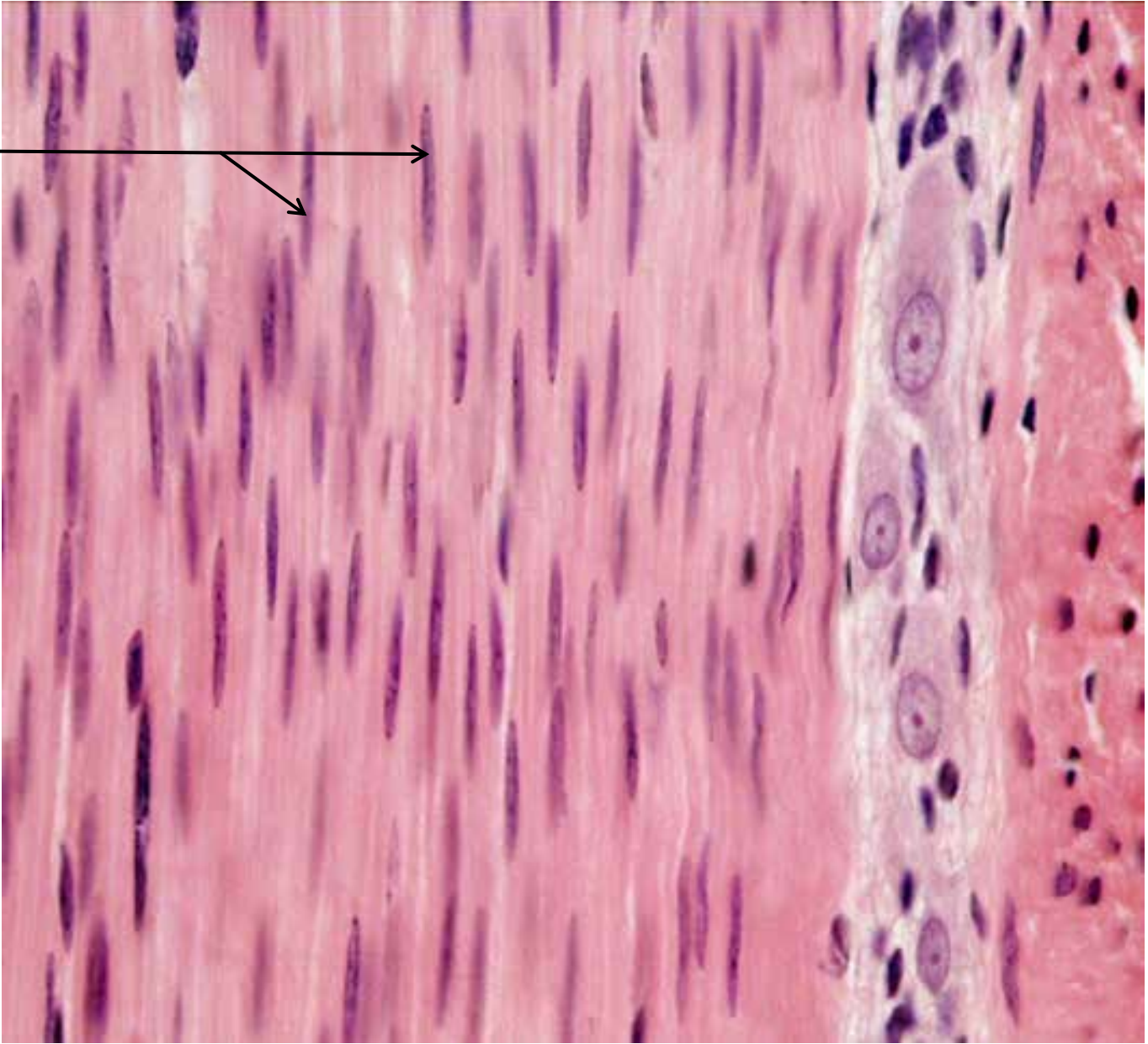
I Bands stain light

Nuclei

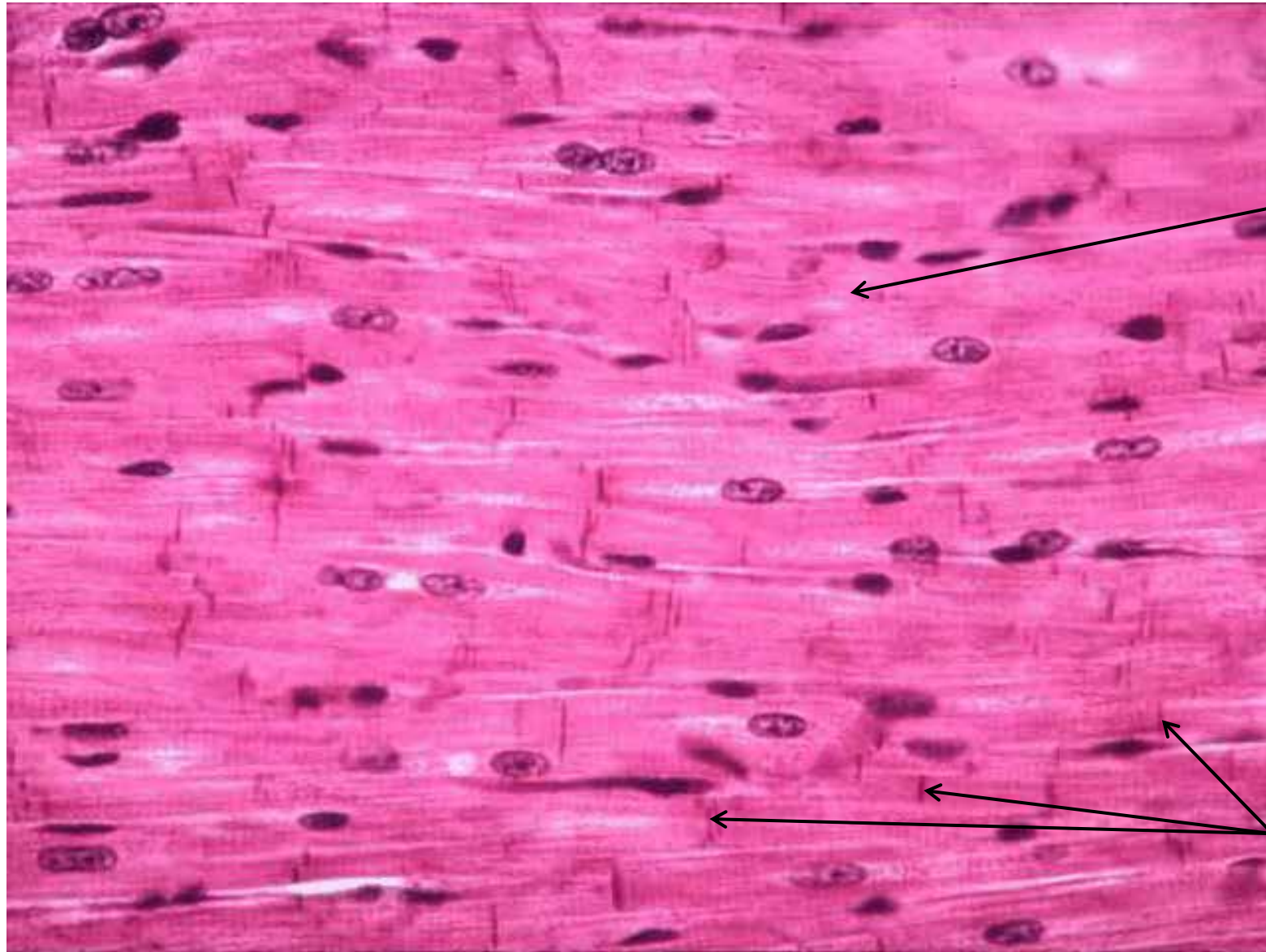


SMOOTH MUSCLE SLIDE



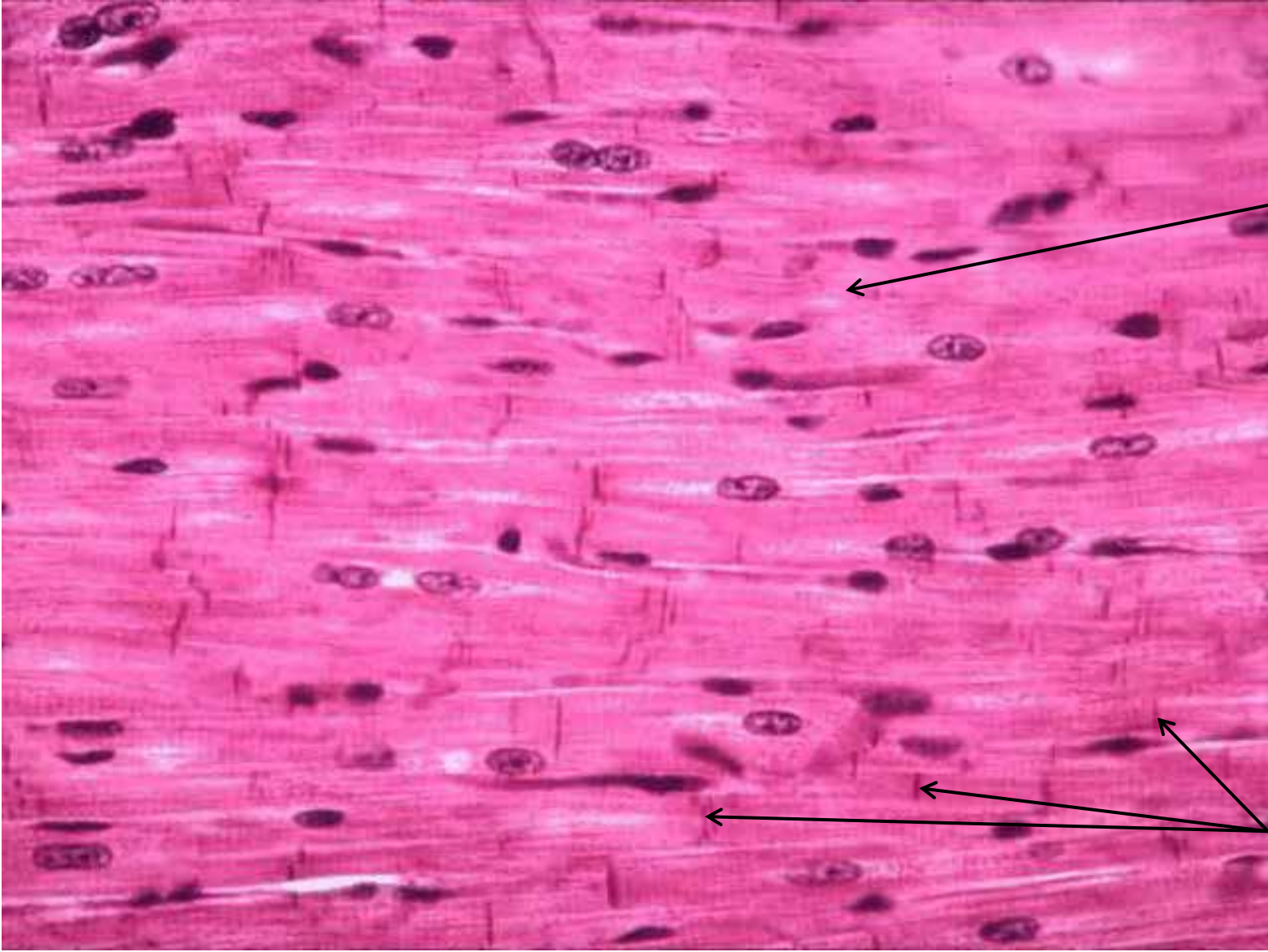


CARDIAC MUSCLE SLIDE

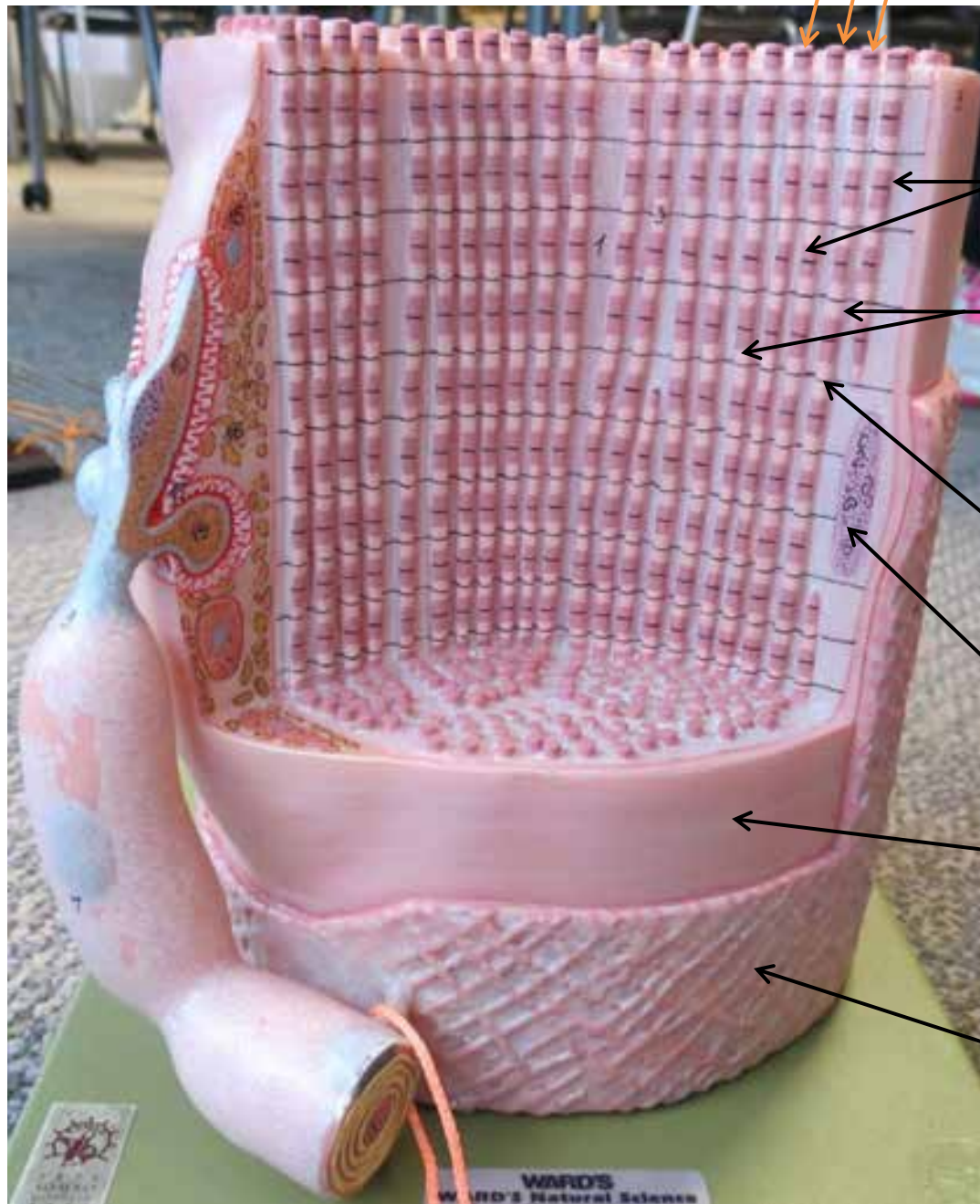


Striations
(alternating dark
& light lines)
(difficult to see)

**Intercalated
Disks**



MUSCLE FIBER MODEL



Myofibrils

A Band
(dark band
on myofibril)

I Band
(light band
on myofibril)

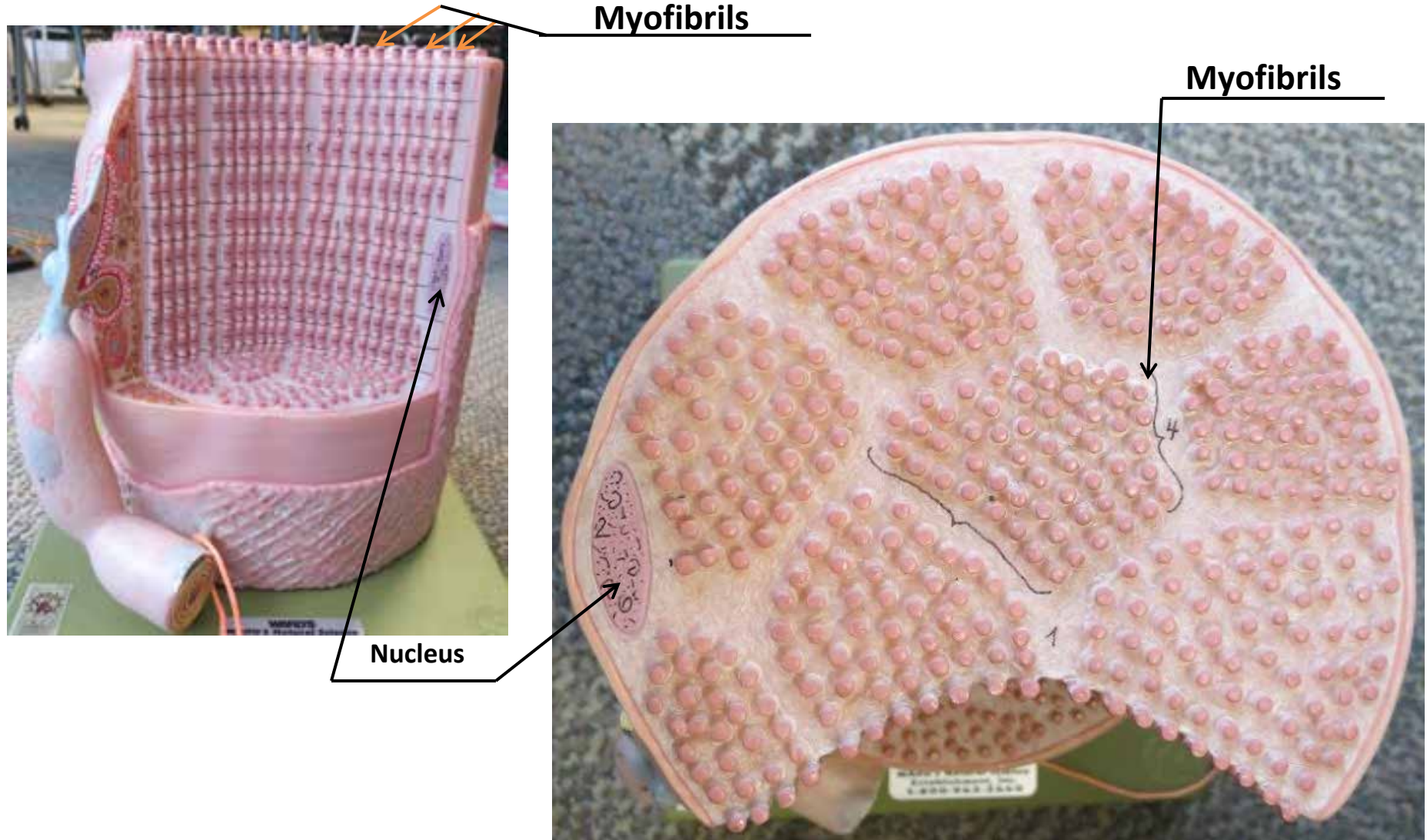
Z - Disk
(lines moving
through I Bands)

Nucleus

Sarcolemma

Endomysium

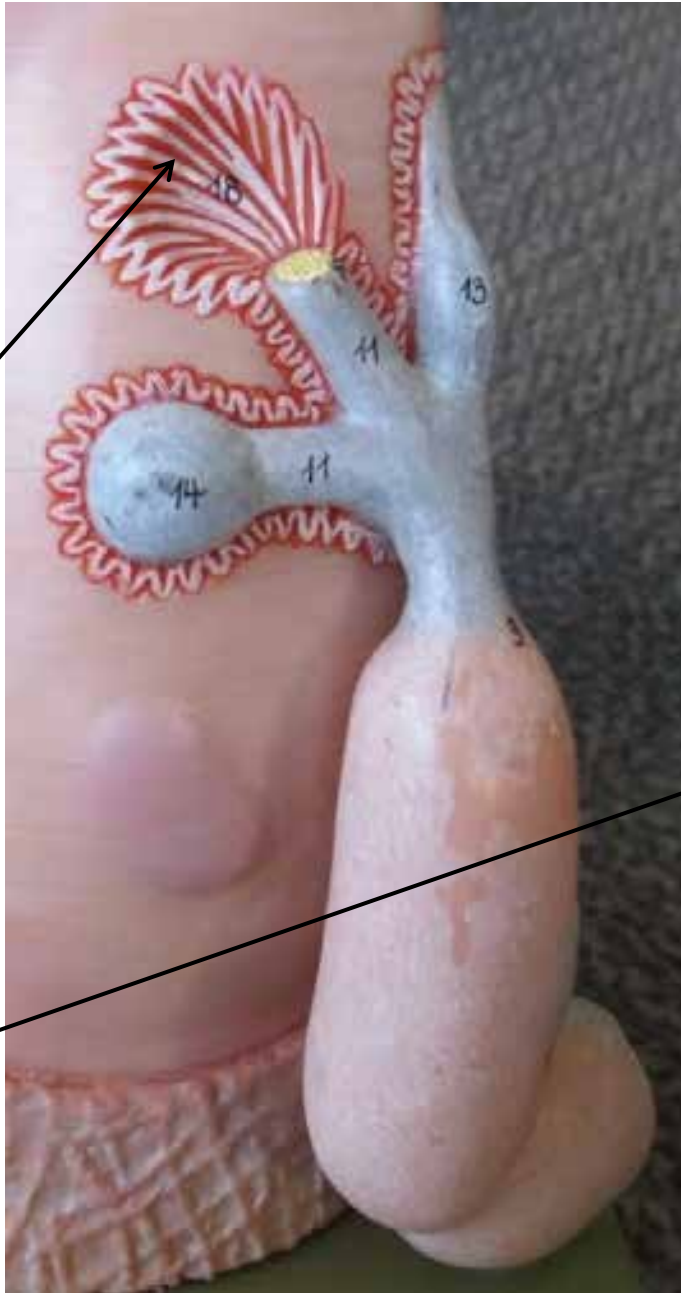MUSCLE FIBER MODEL



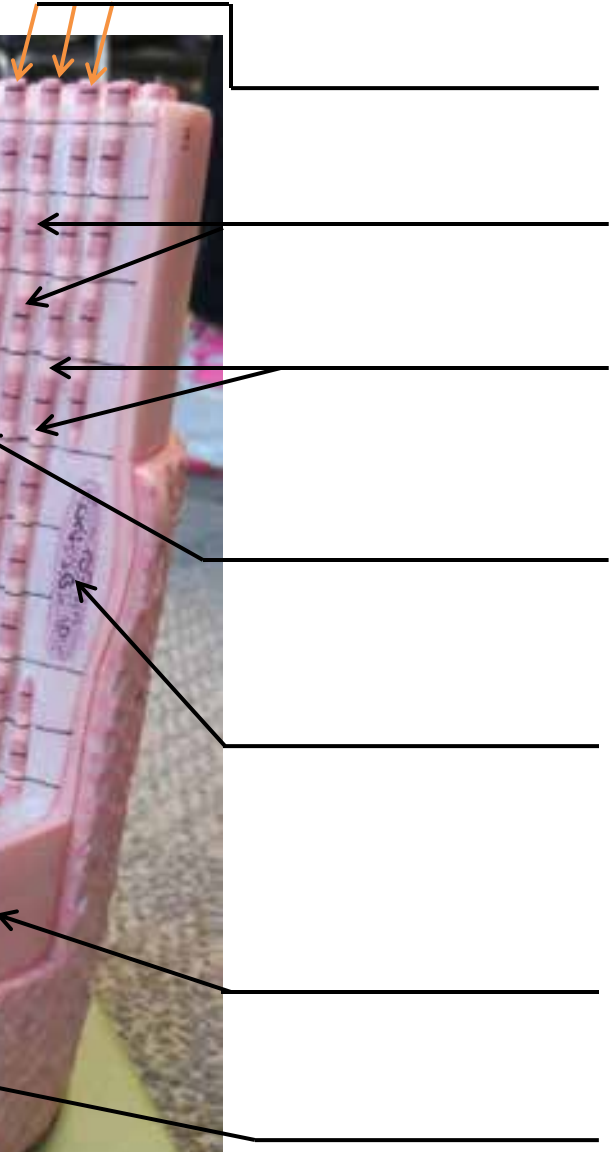

MUSCLE FIBER MODEL

Motor Endplate

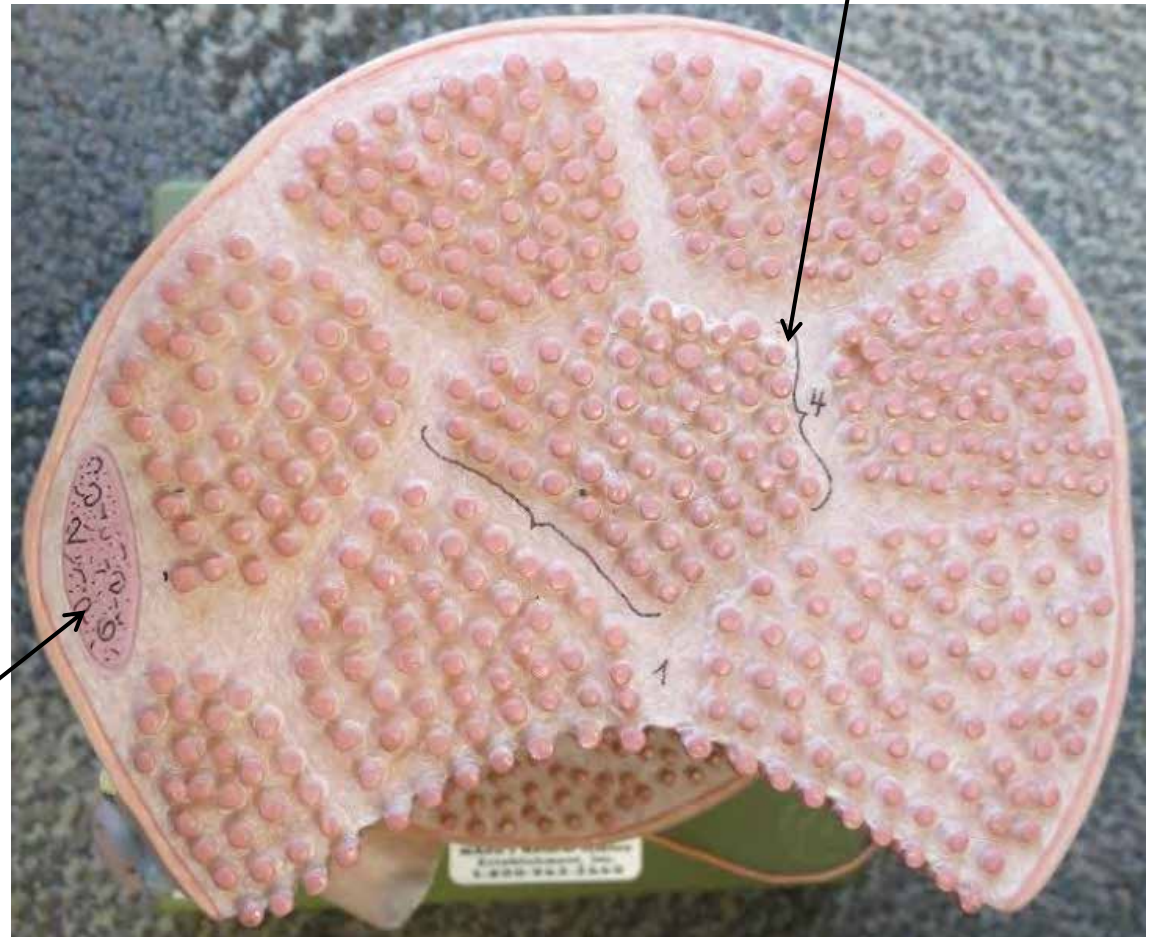
Motor Neuron



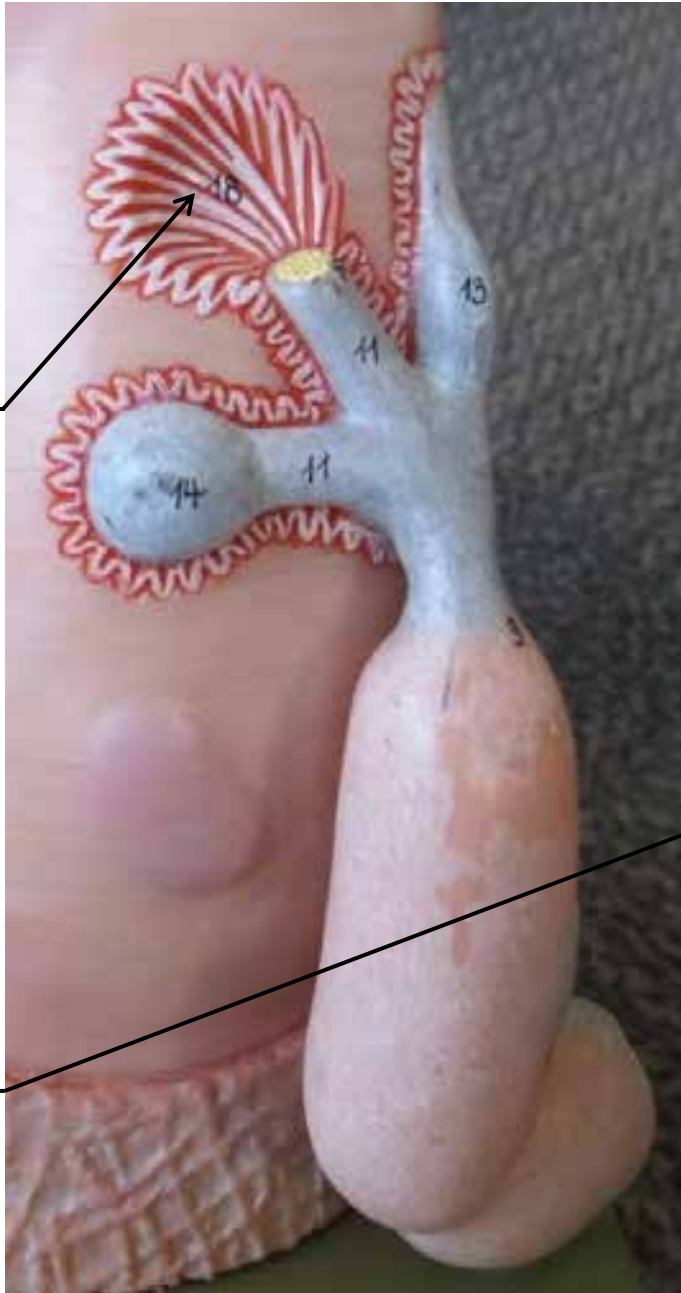MUSCLE FIBER MODEL




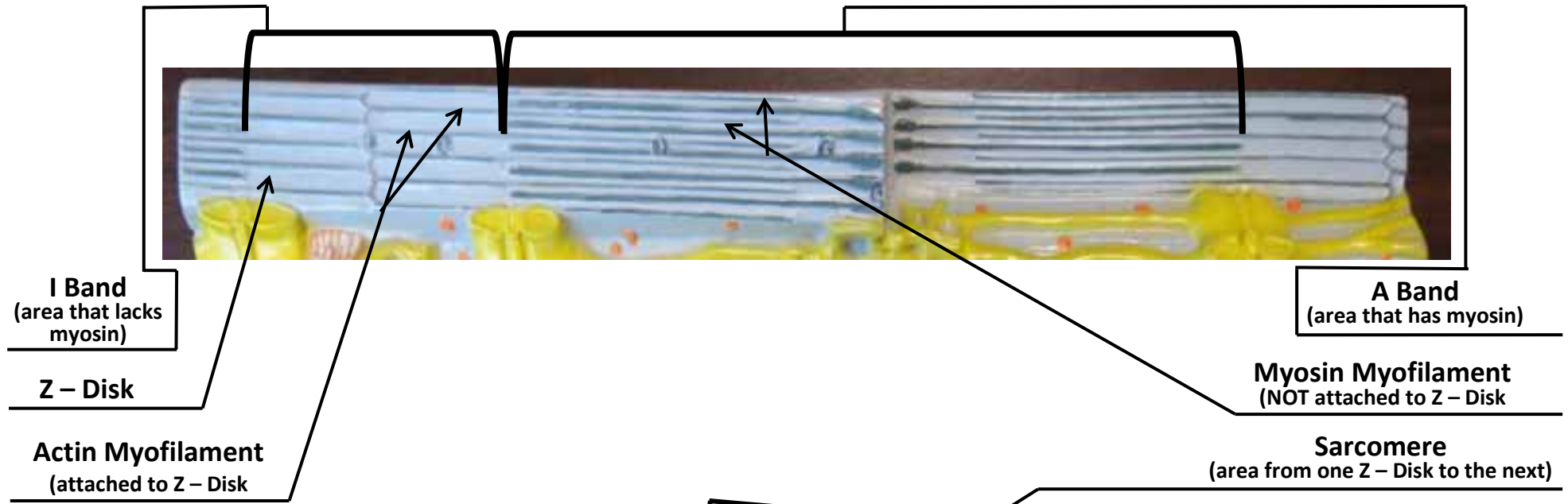
MUSCLE FIBER MODEL


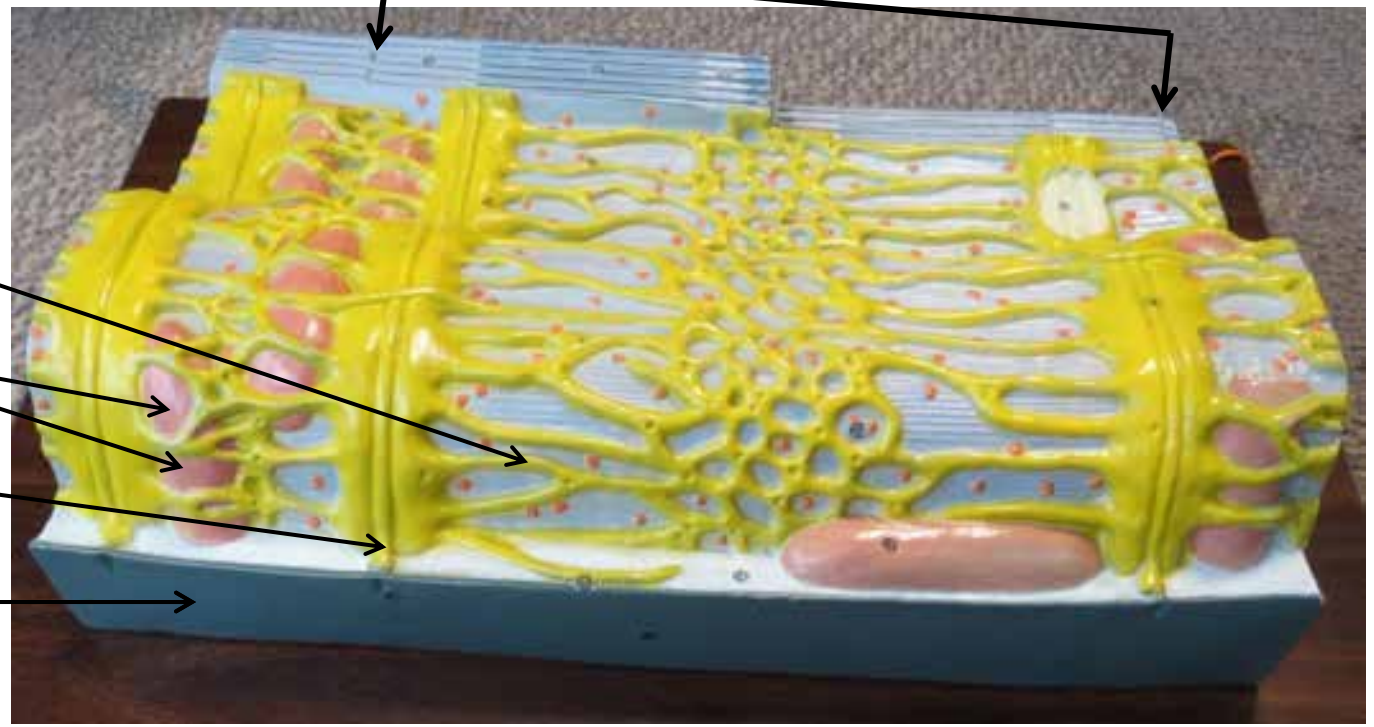
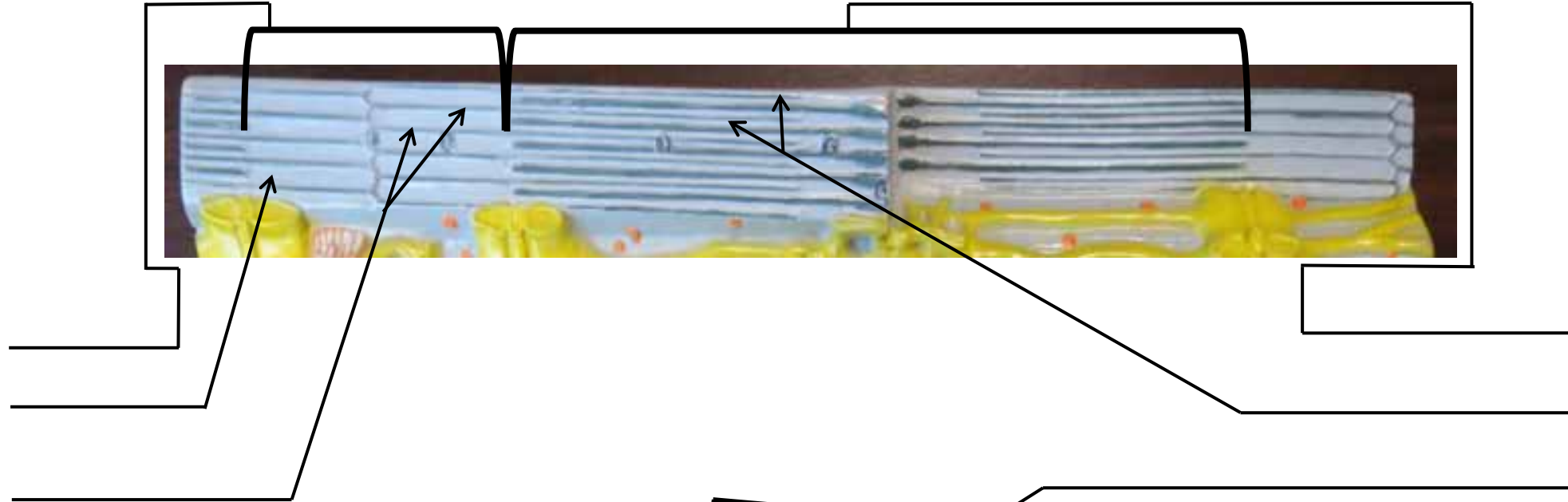



MUSCLE FIBER MODEL

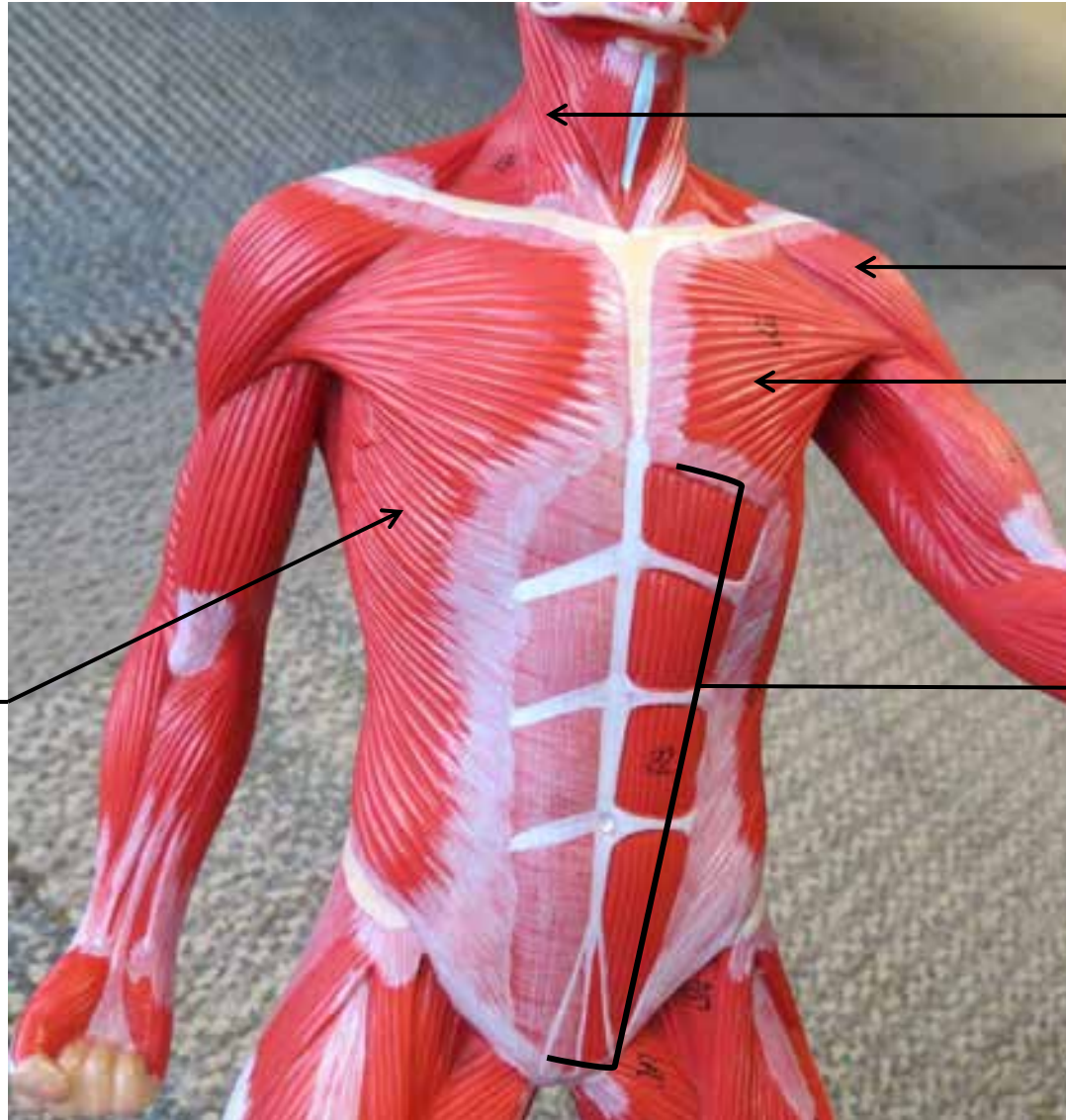


Muscle Fiber Model With Sacroplasmic Reticulum





SMALL MUSCULAR MODELS



Sternocleidomastoid

Deltoid

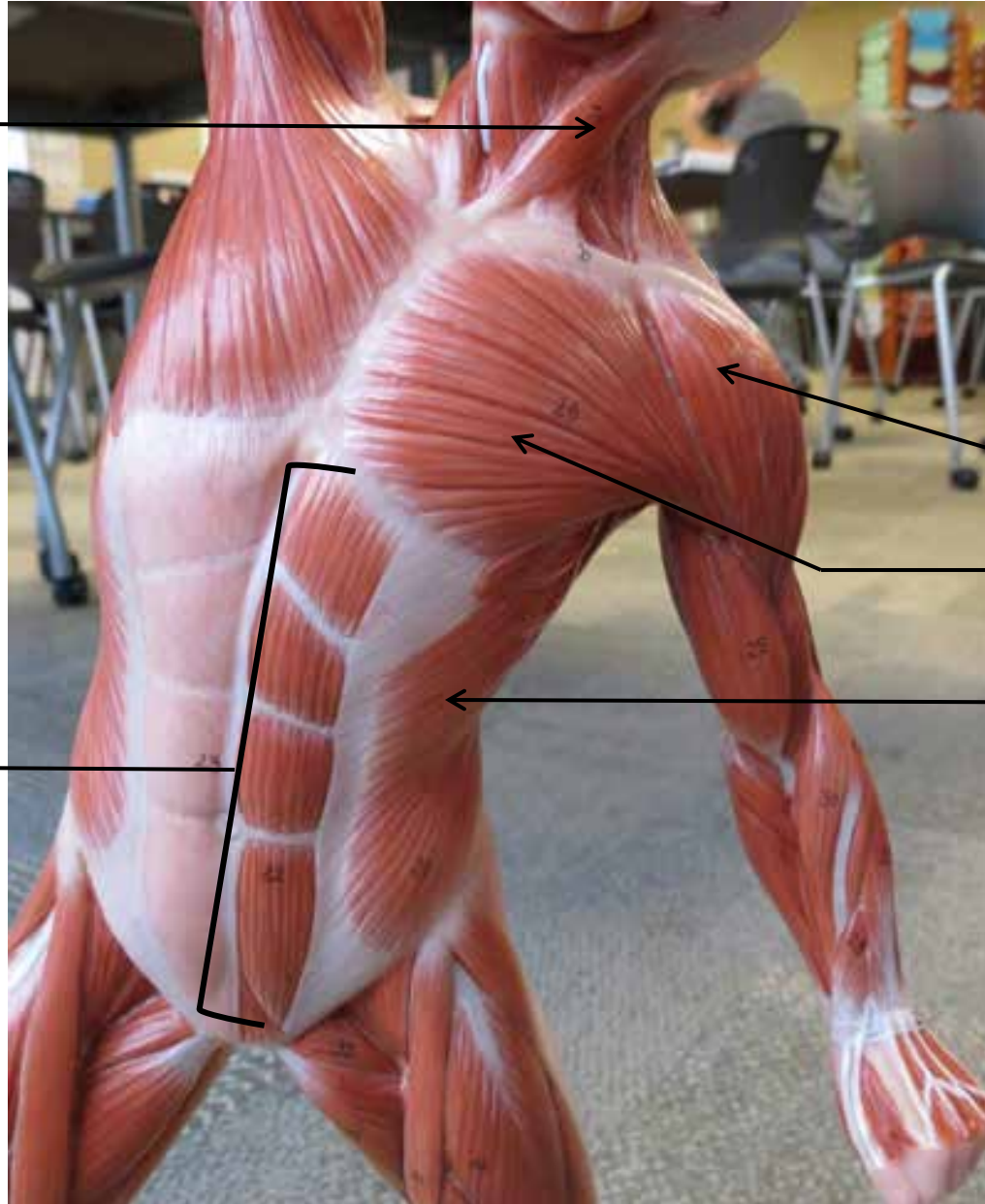
Pectoralis
Major

Rectus
Abdominis

External
Obliques

SMALL MUSCULAR MODELS

Sternocleidomastoid



Deltoid

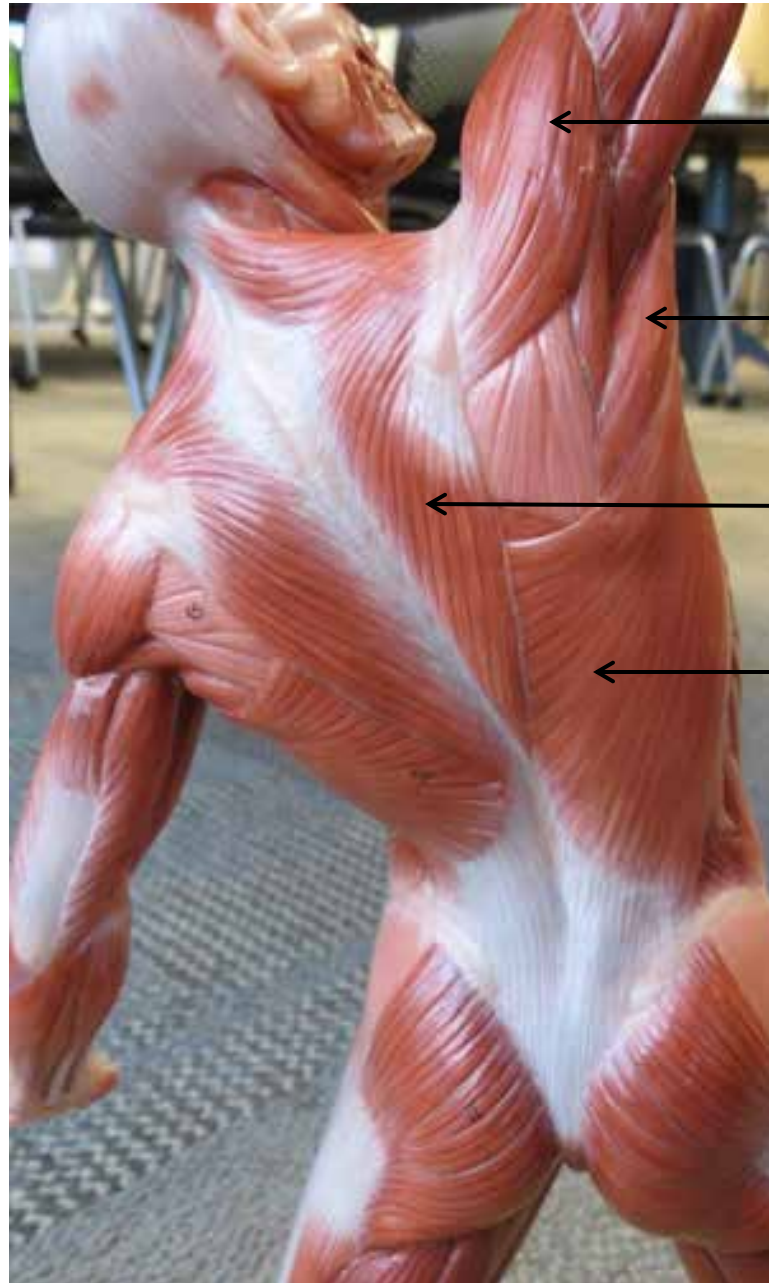
Pectoralis Major

External Obliques

Rectus Abdominis



SMALL MUSCULAR MODELS



Deltoid



Teres Major



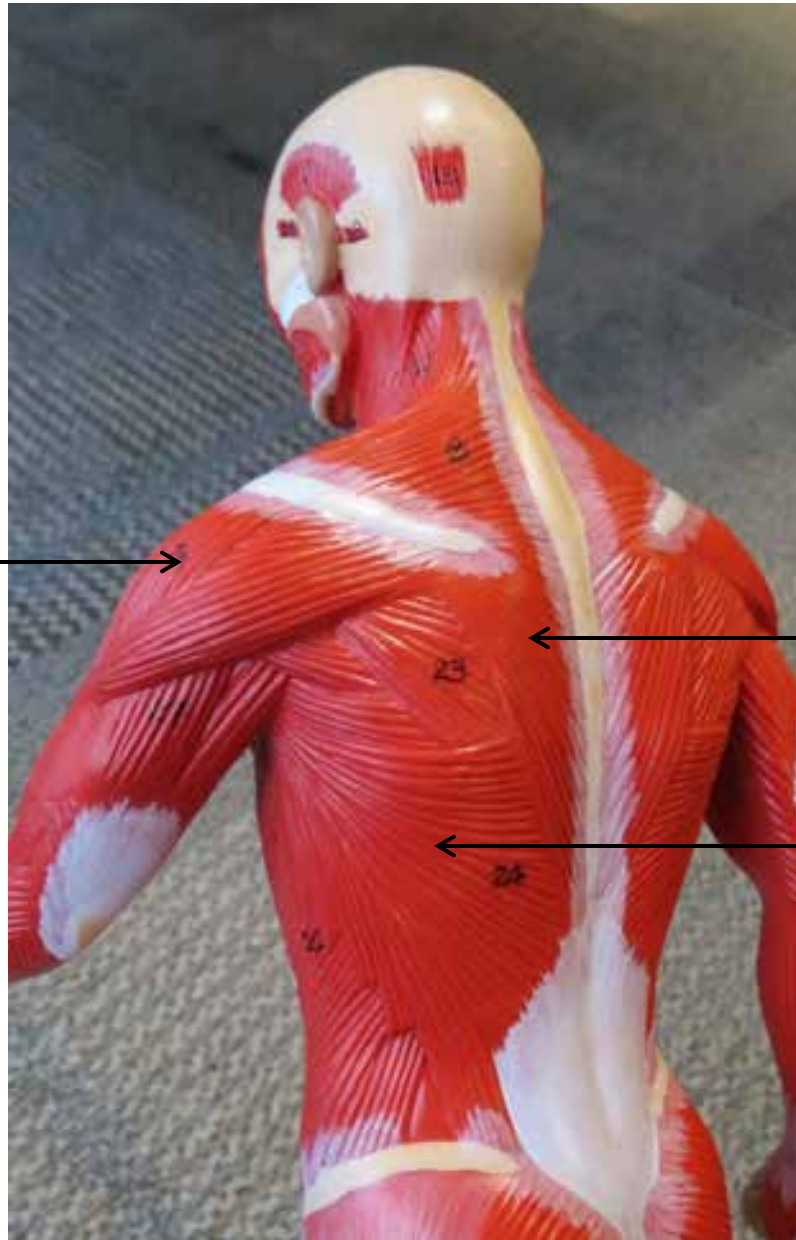
Trapezius



Latissimus Dorsi




SMALL MUSCULAR MODELS



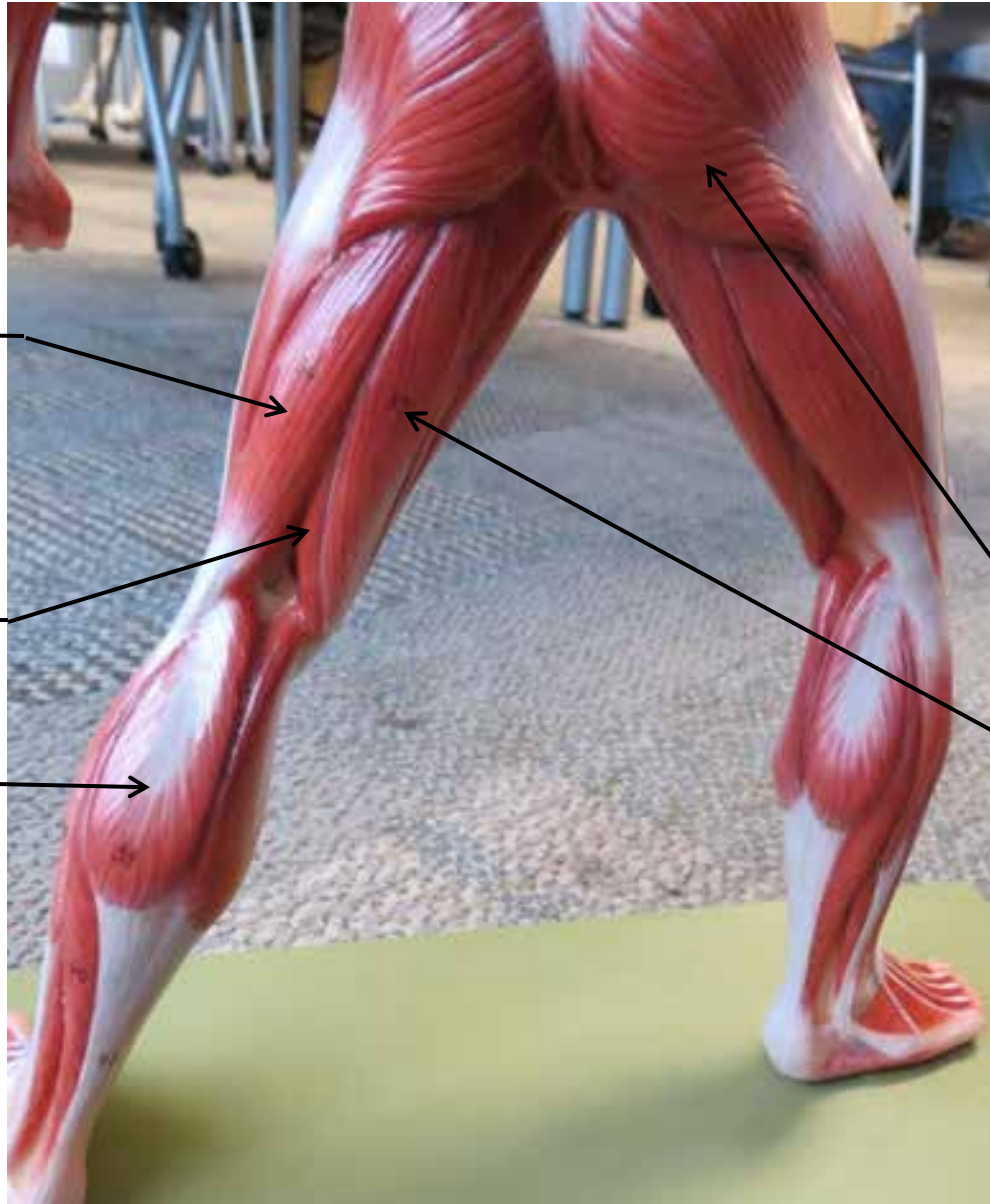Deltoid

Trapezius

Latissimus
Dorsi



SMALL MUSCULAR MODELS



Biceps Femoris

Semimembranosus

Gastrocnemius

Gluteus Maximus

Semitendinosus

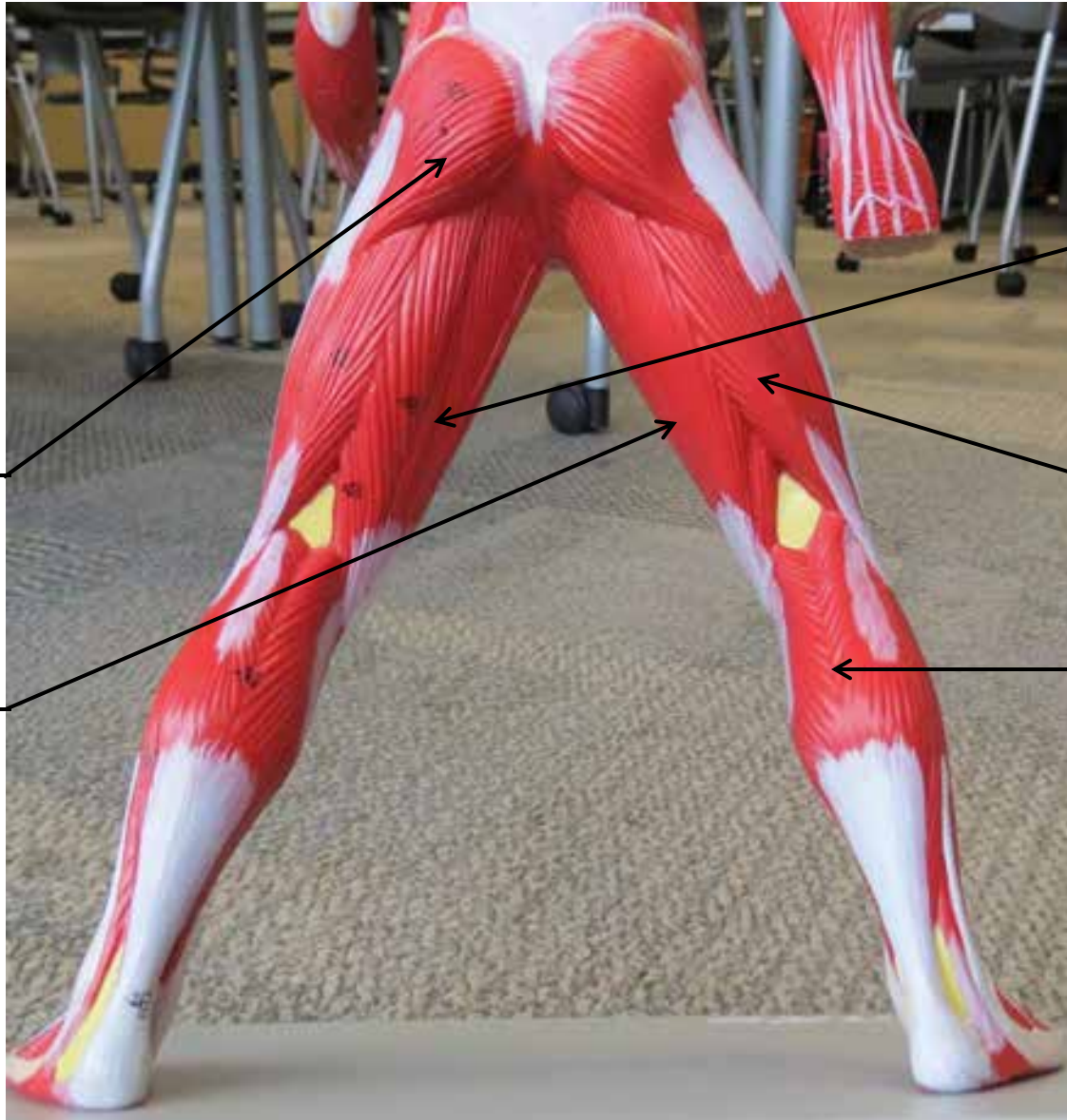


SMALL MUSCULAR MODELS



**Gluteus
Maximus**

Semitendinosus



Semimembranosus

Biceps Femoris

Gastrocnemius


SMALL MUSCULAR MODELS

Rectus Femoris

Gracilis

Vastus Lateralis

Vastus Medialis

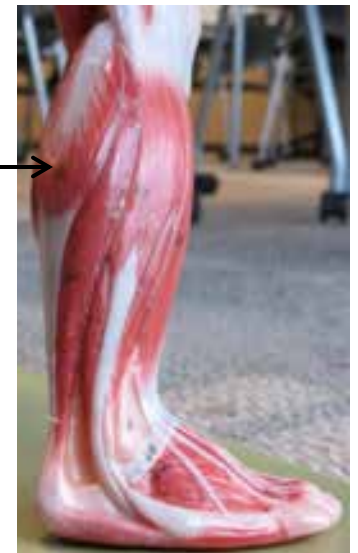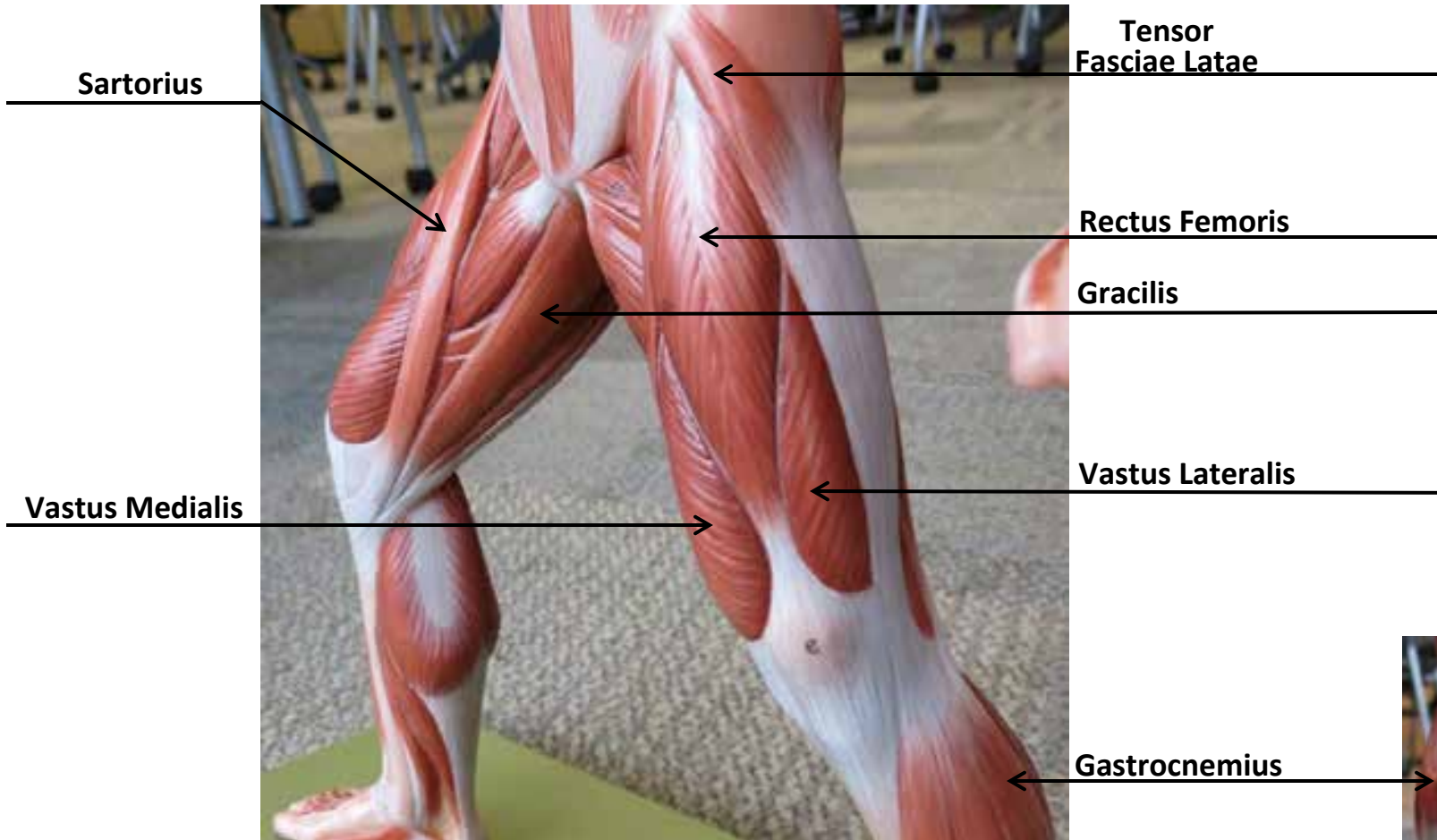


Sartorius

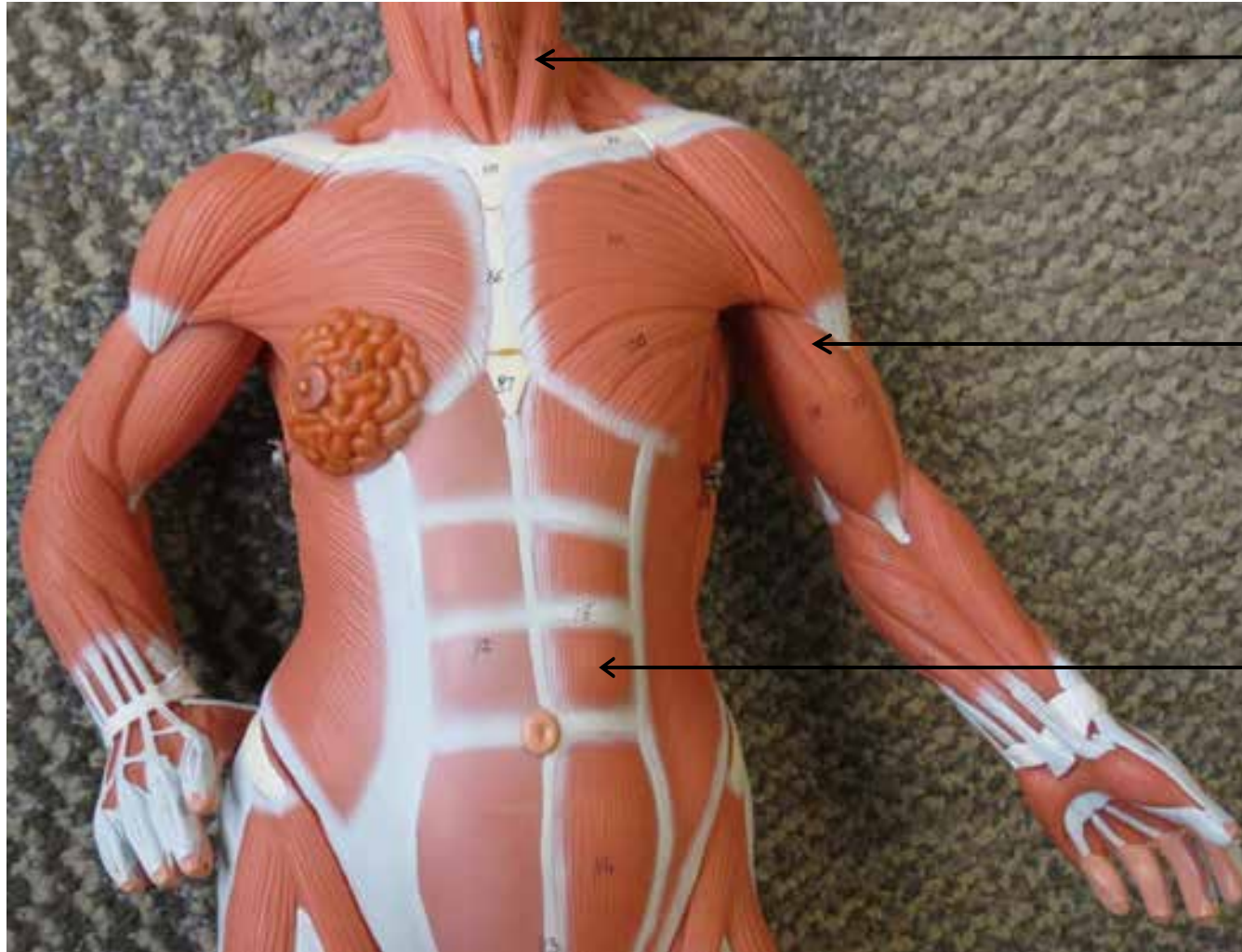
Tensor Fasciae Latae



SMALL MUSCULAR MODELS




SMALL MUSCULAR MODELS



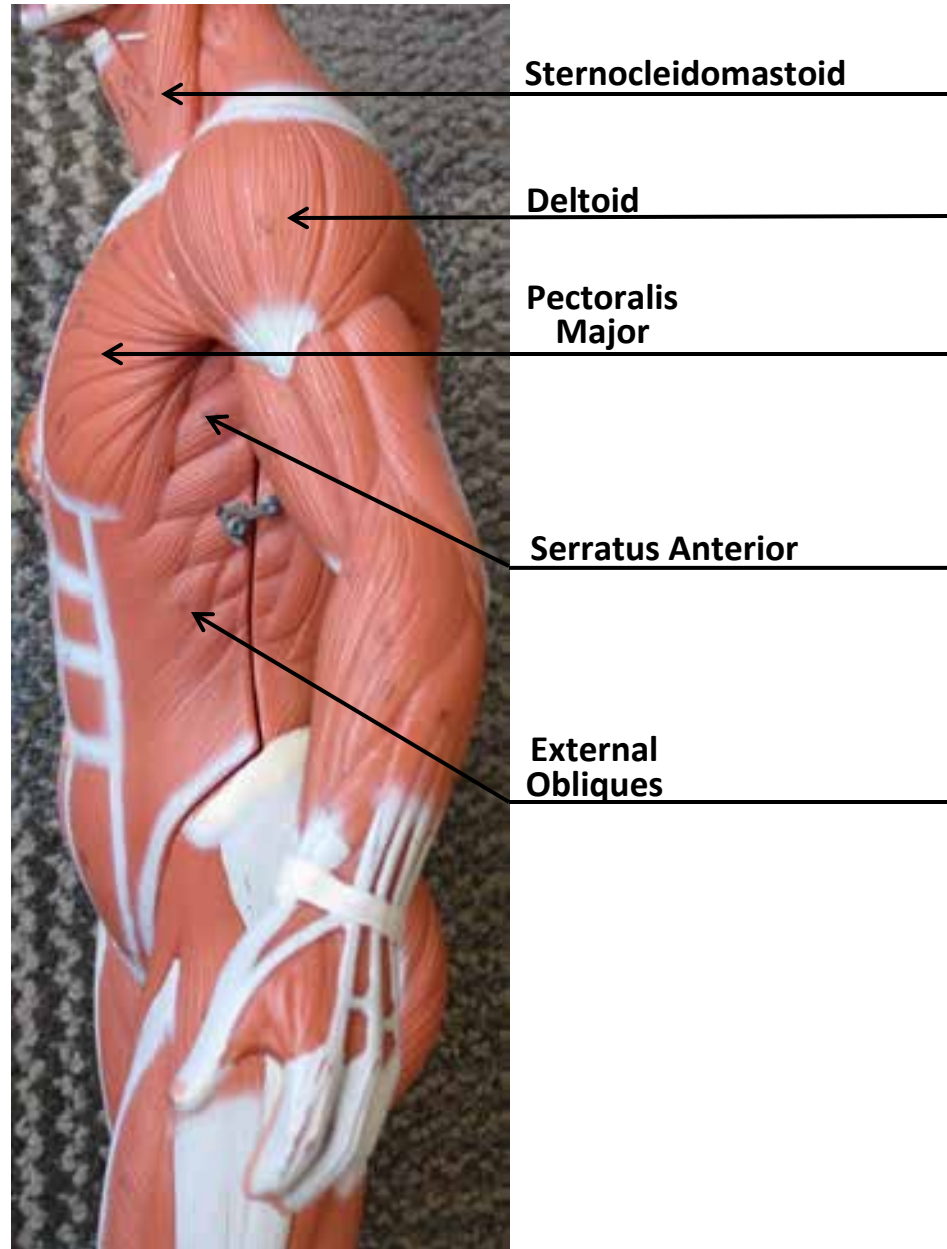
Sternocleidomastoid

Biceps Brachii

Rectus Abdominis



SMALL MUSCULAR MODELS



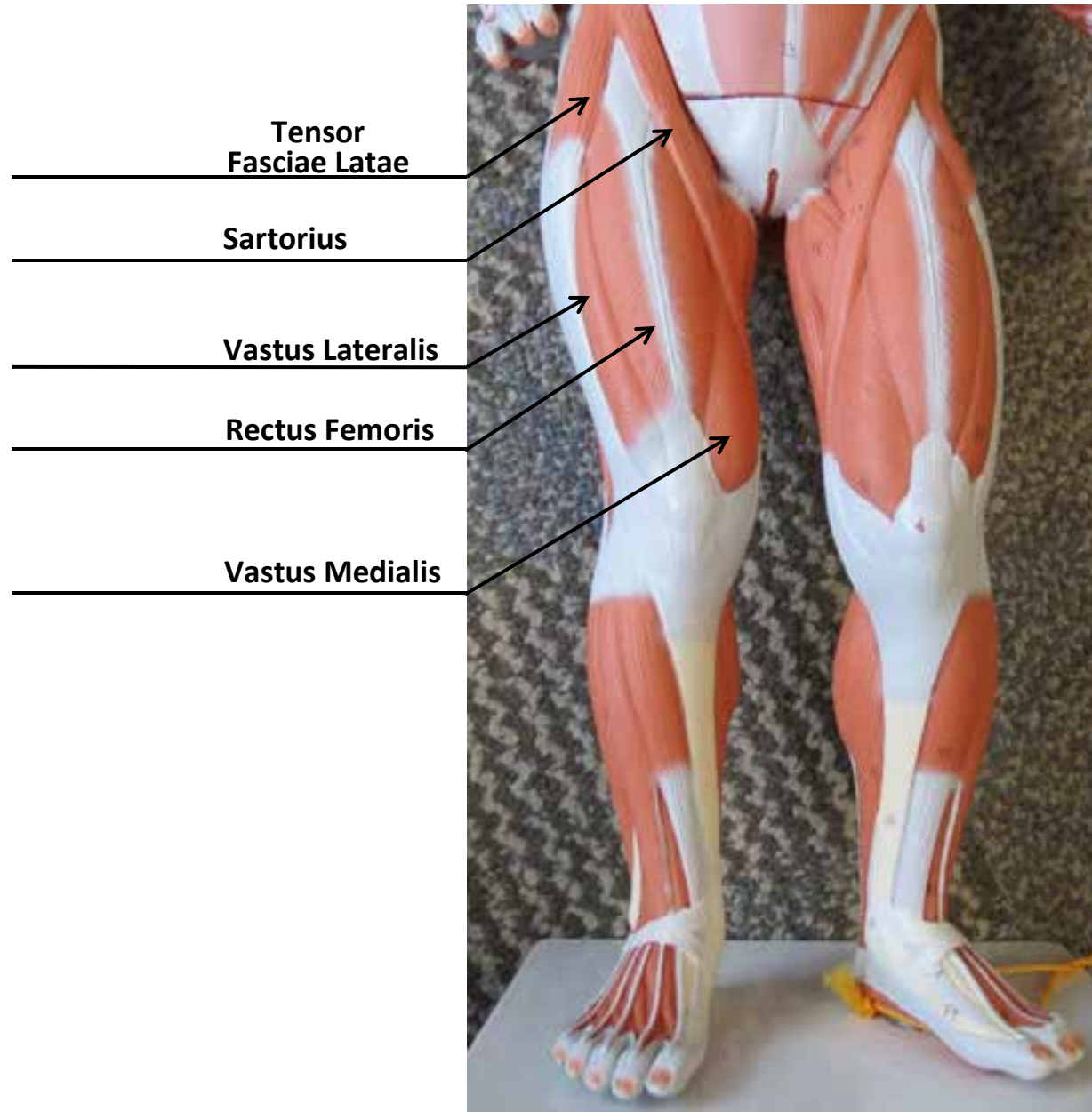
SMALL MUSCULAR MODELS



Tensor Fasciae Latae

Gastrocnemius

SMALL MUSCULAR MODELS



SMALL MUSCULAR MODELS




Trapezius

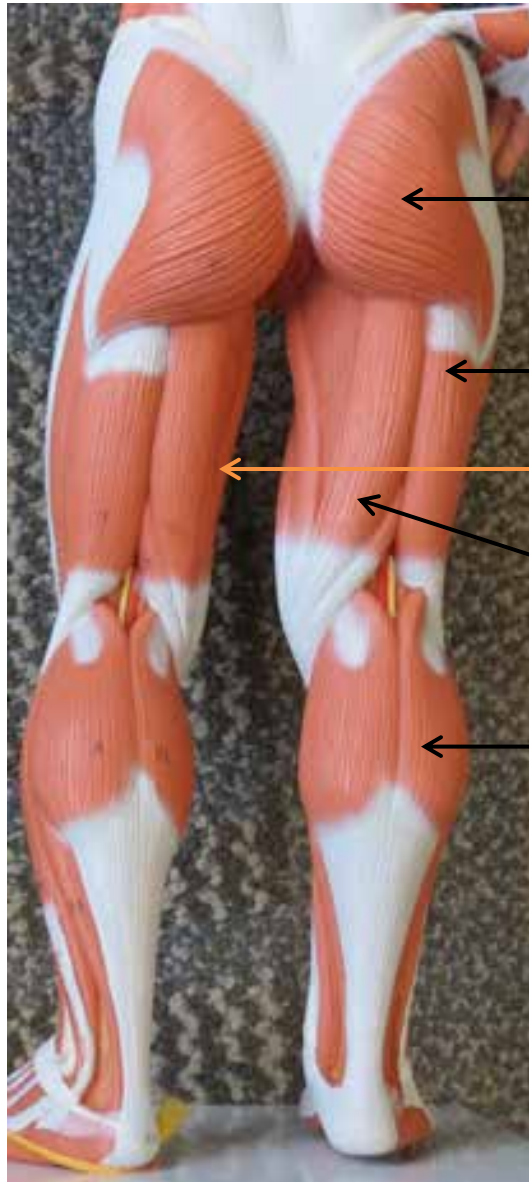
Deltoid

Teres
Major

Latissimus
Dorsi



SMALL MUSCULAR MODELS



Gluteus Maximus


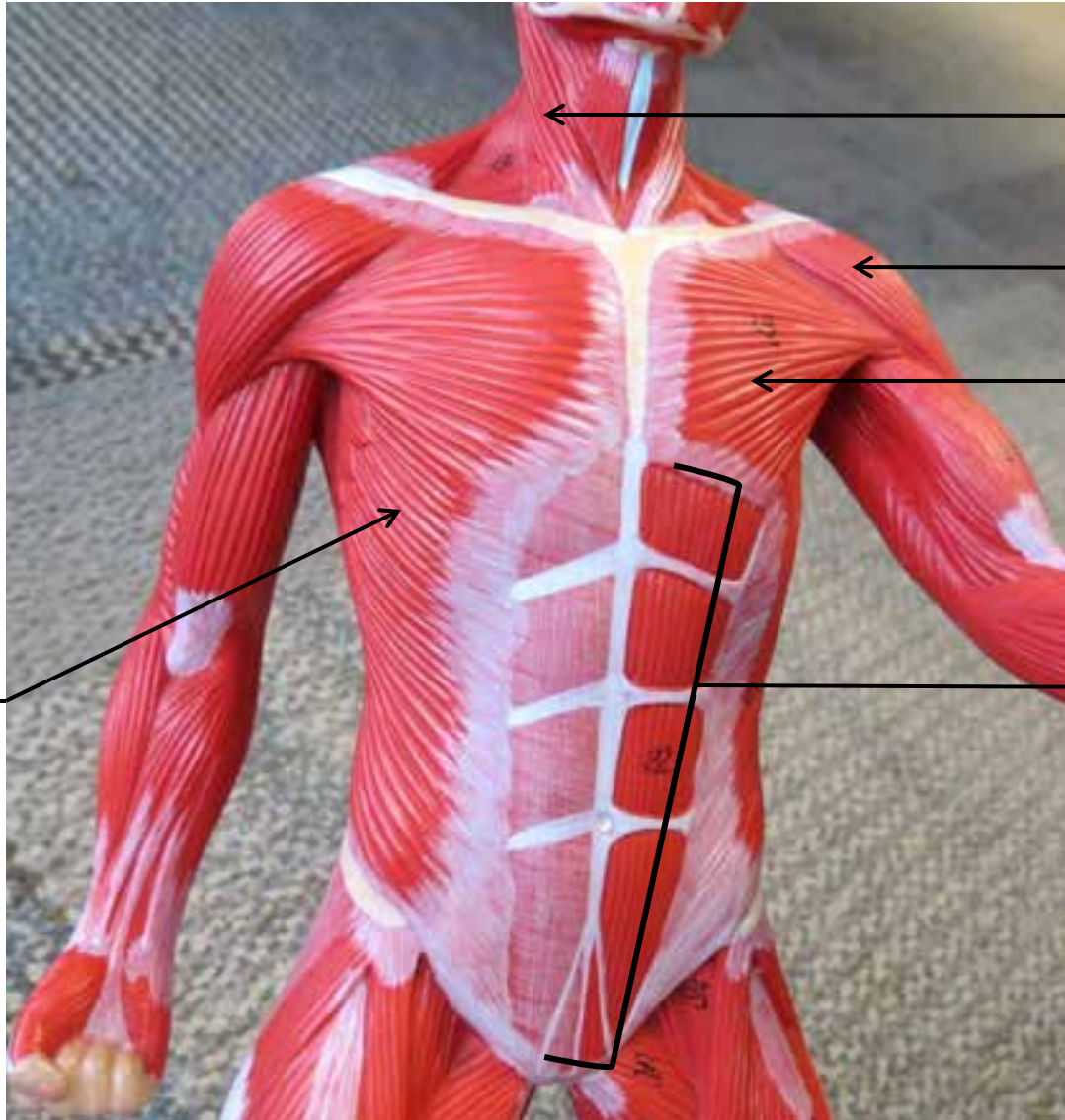
Biceps Femoris

Semimembranosus

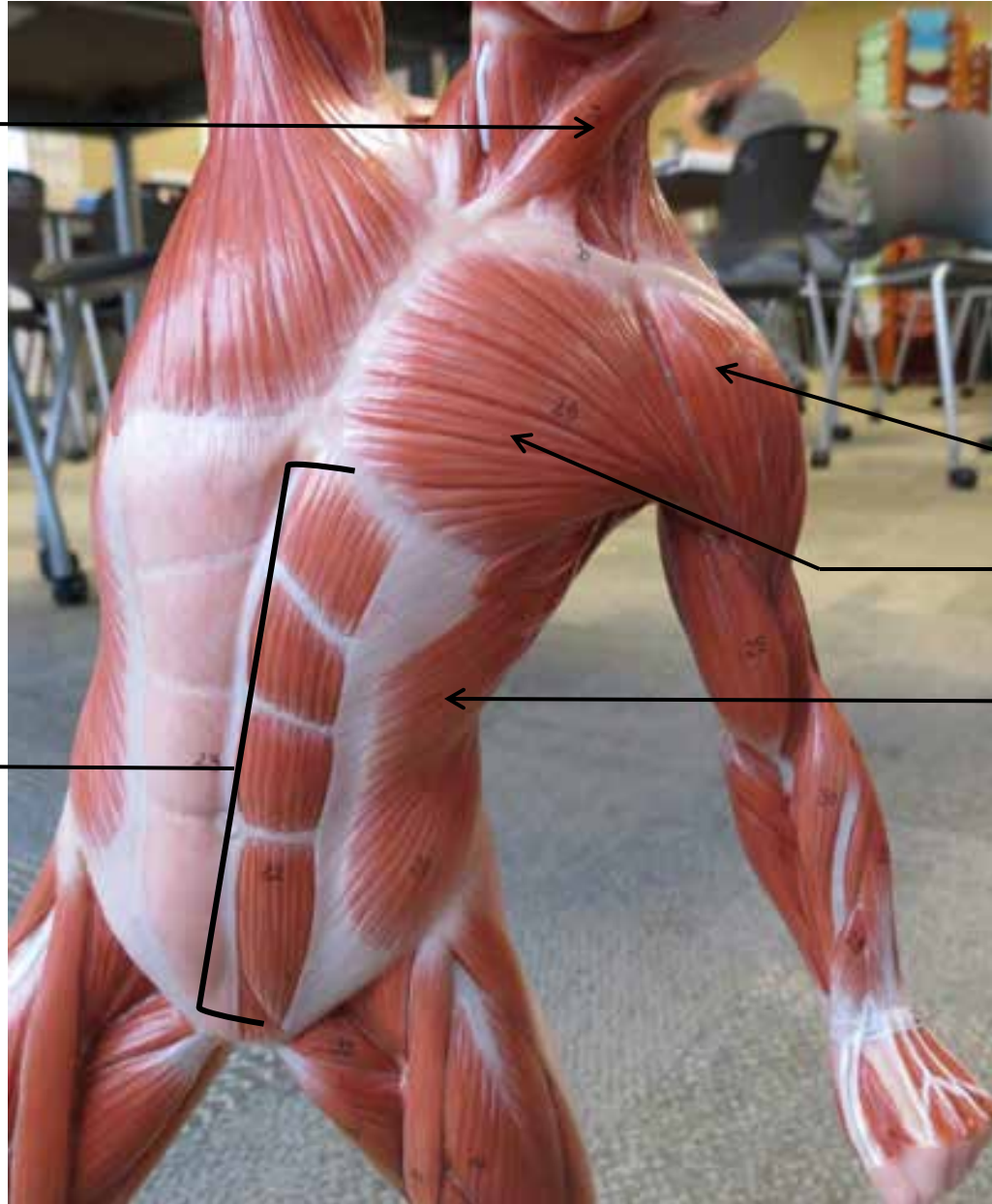
Semitendinosus

Gastrocnemius

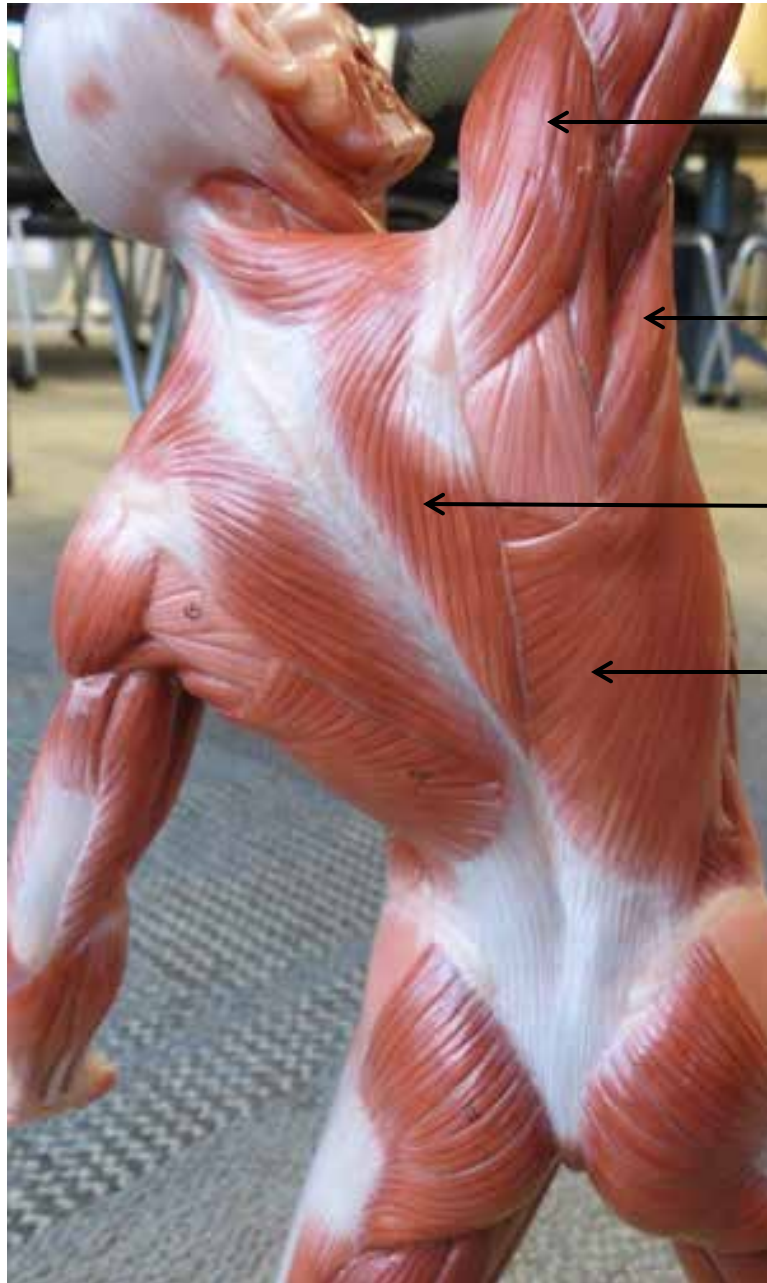
SMALL MUSCULAR MODELS




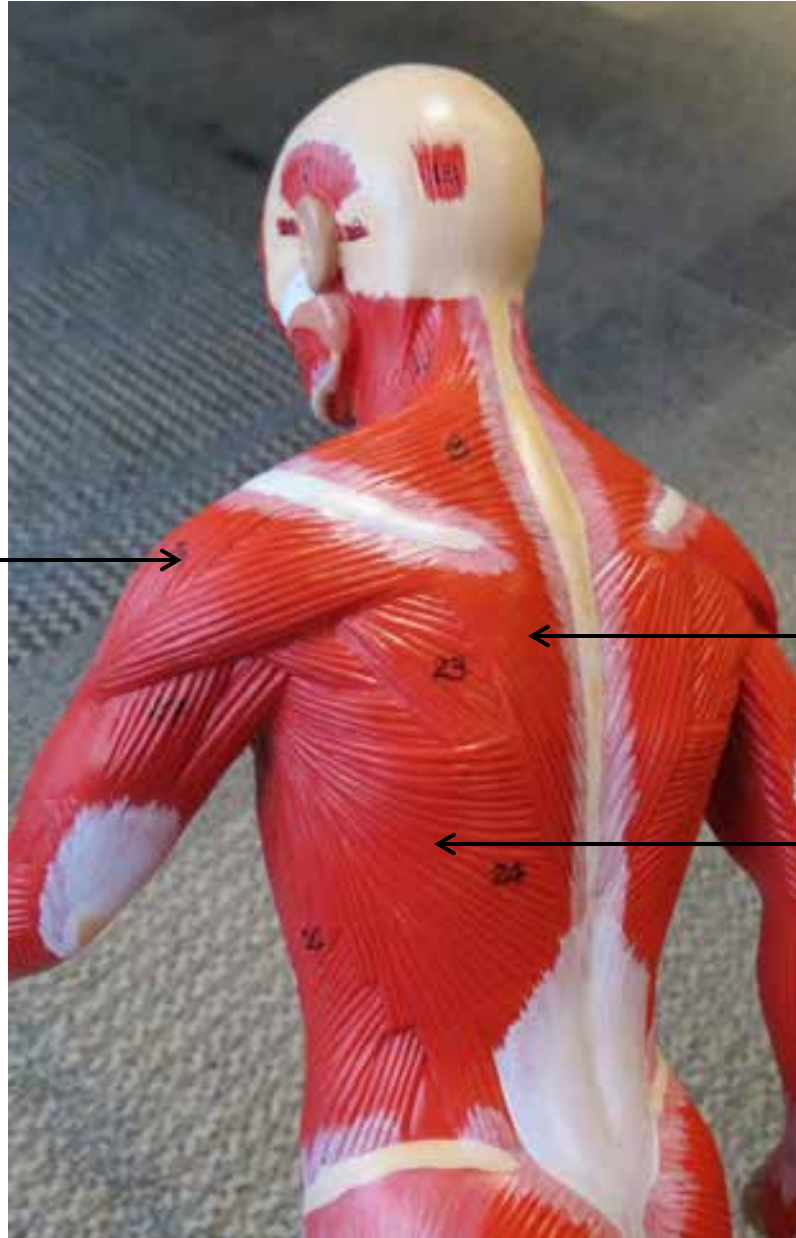
SMALL MUSCULAR MODELS



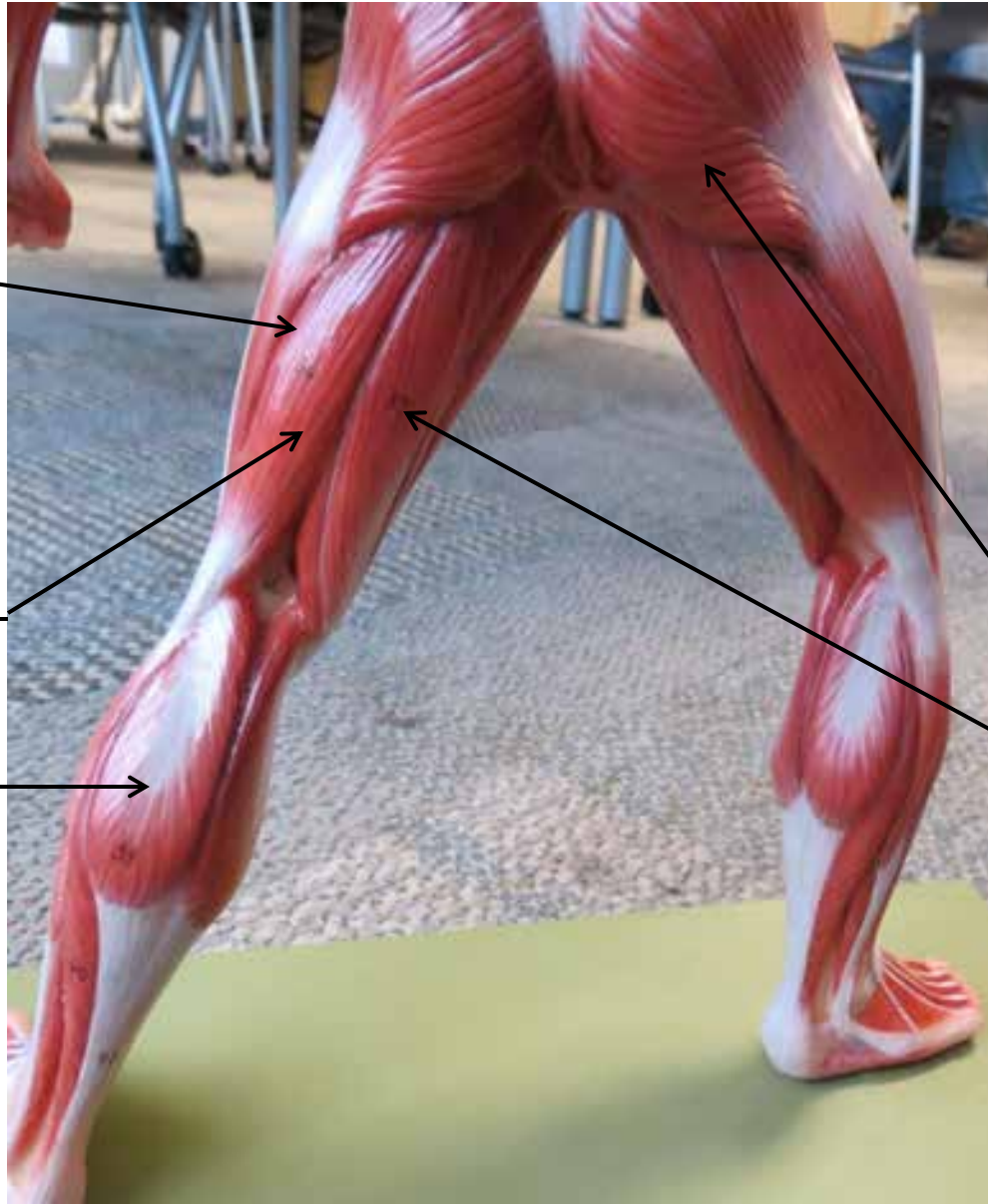
SMALL MUSCULAR MODELS




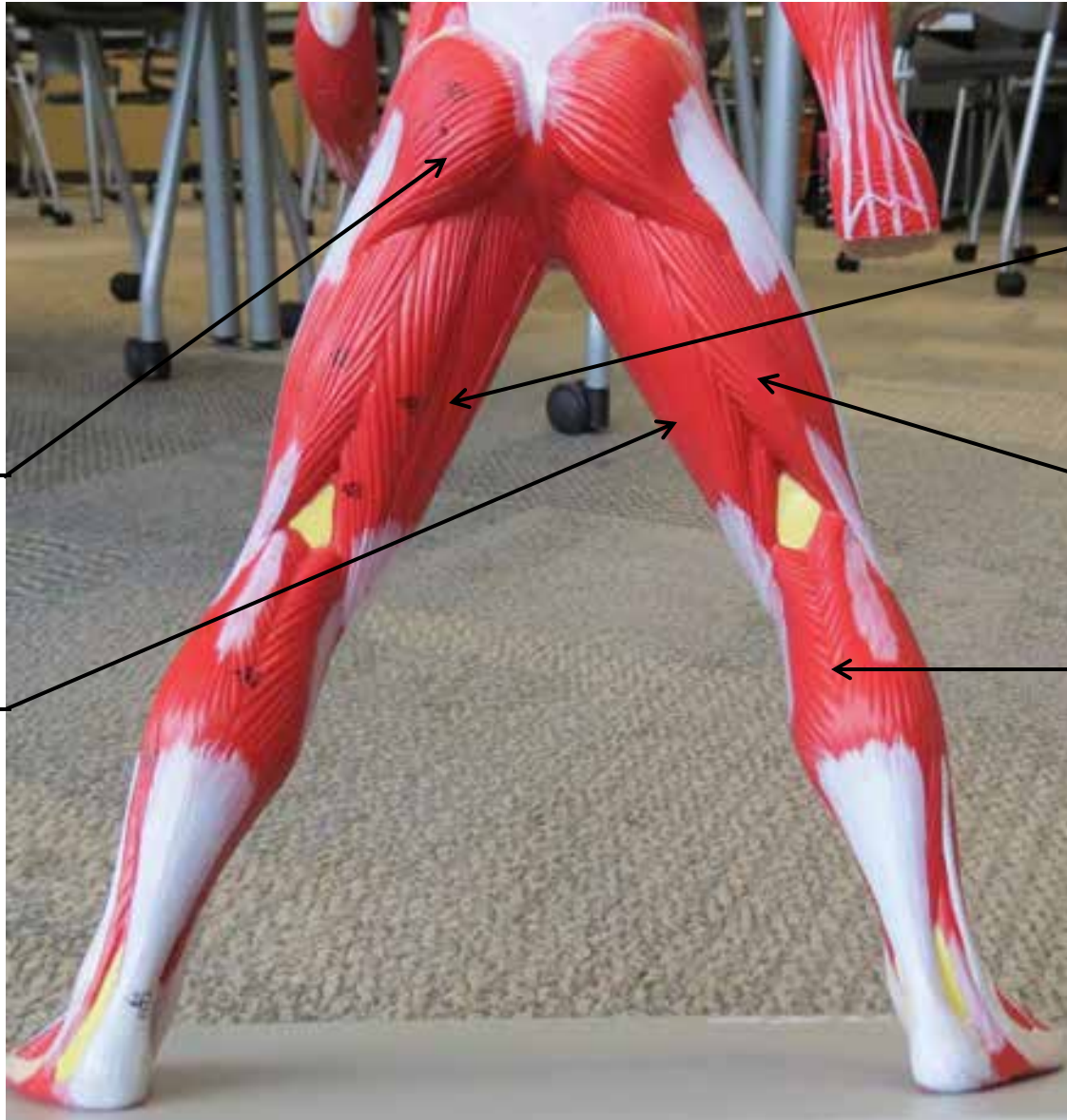
SMALL MUSCULAR MODELS




SMALL MUSCULAR MODELS



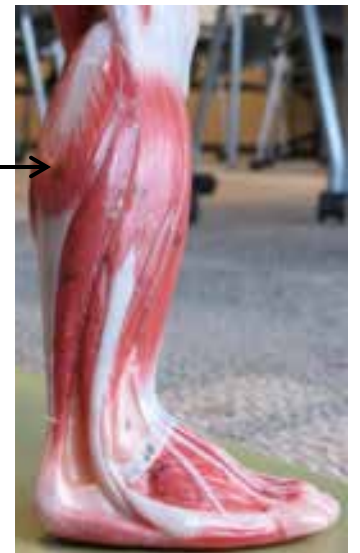
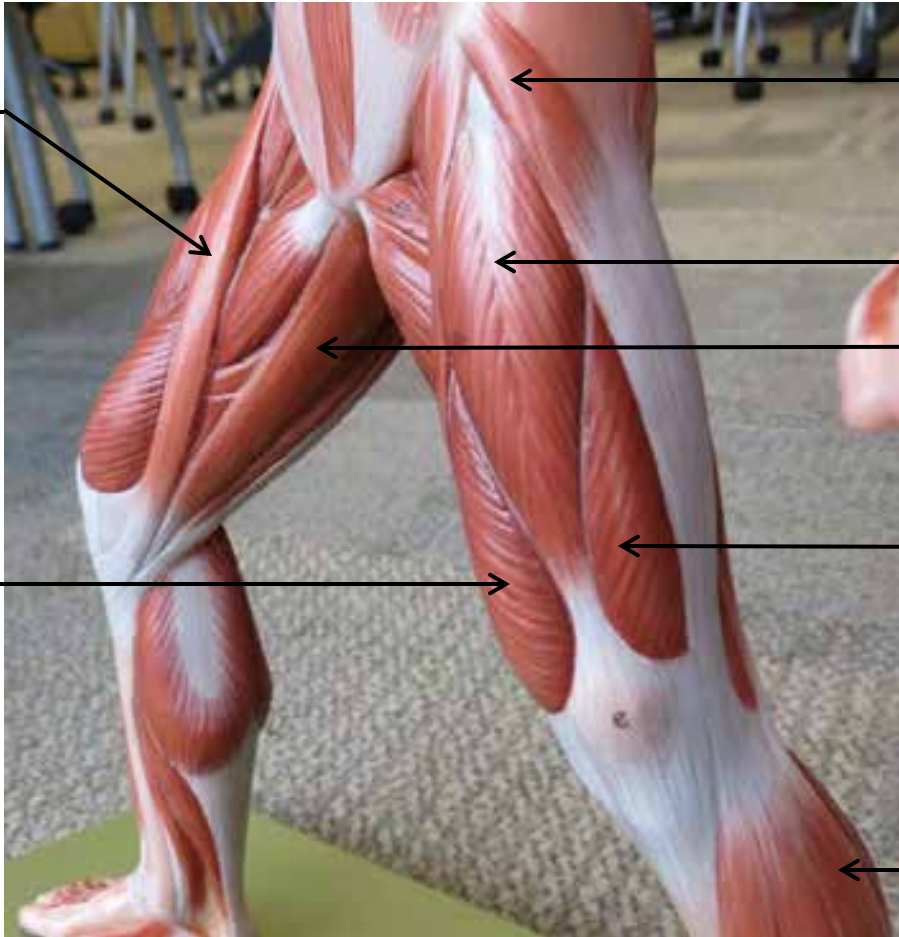
SMALL MUSCULAR MODELS



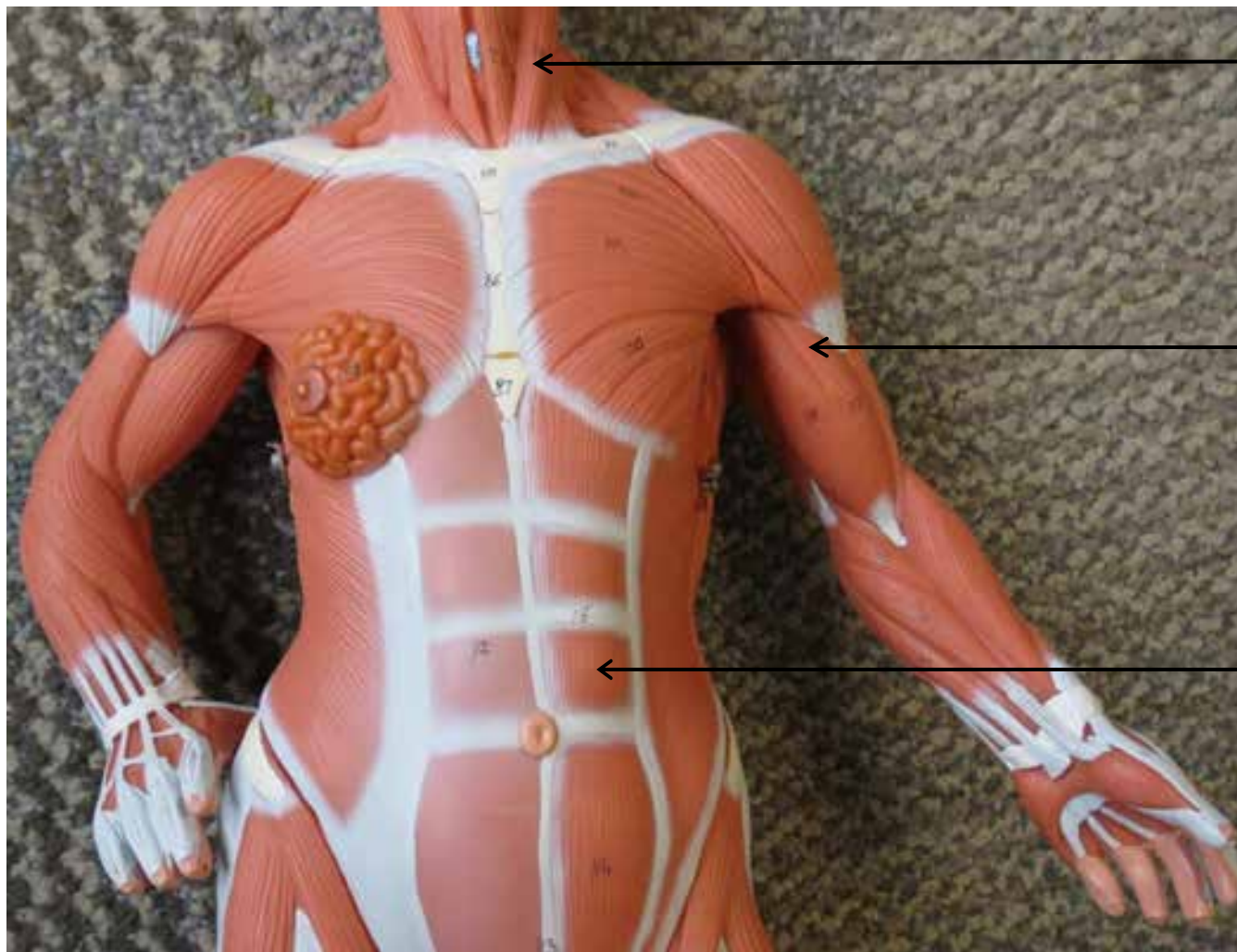SMALL MUSCULAR MODELS



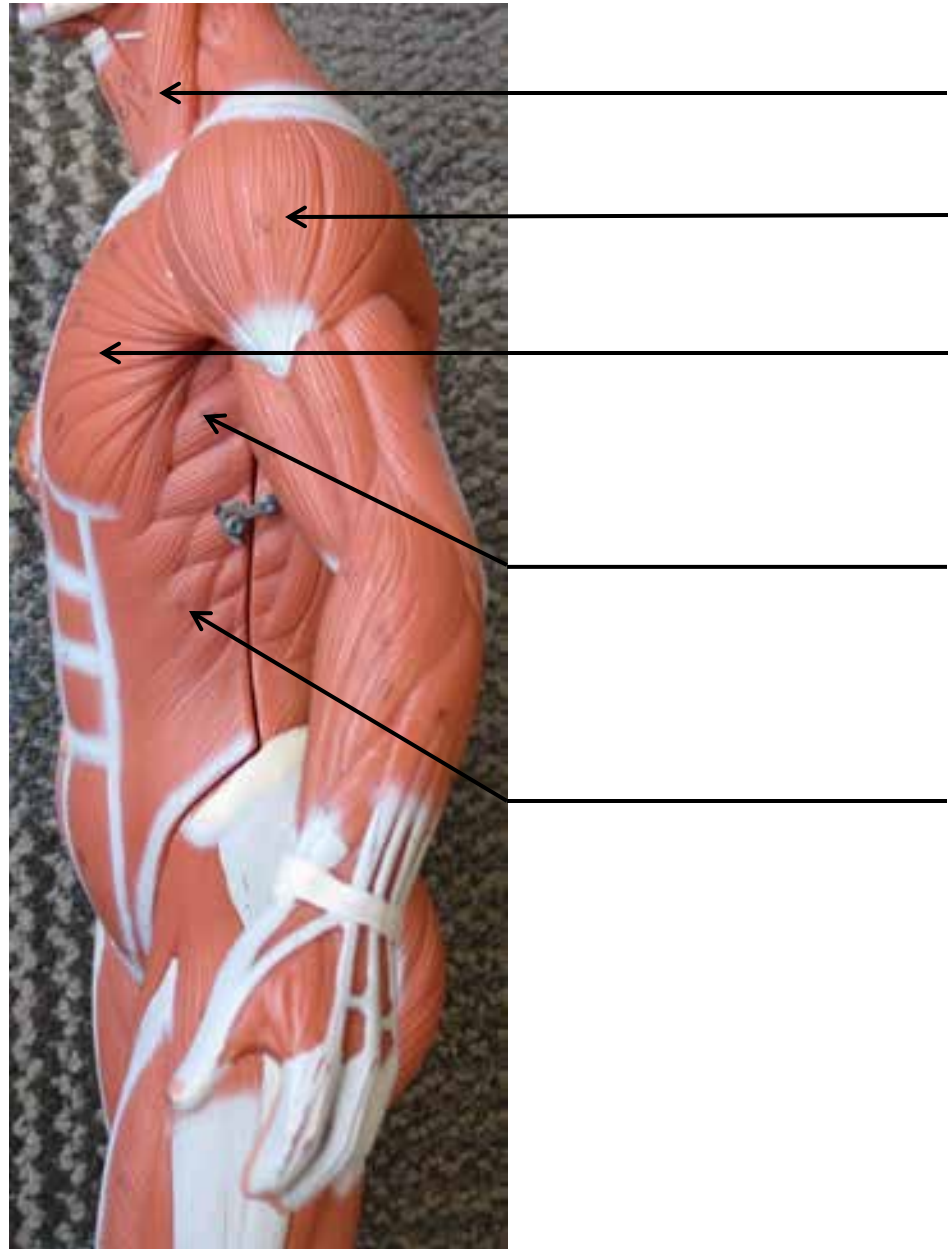
SMALL MUSCULAR MODELS



SMALL MUSCULAR MODELS




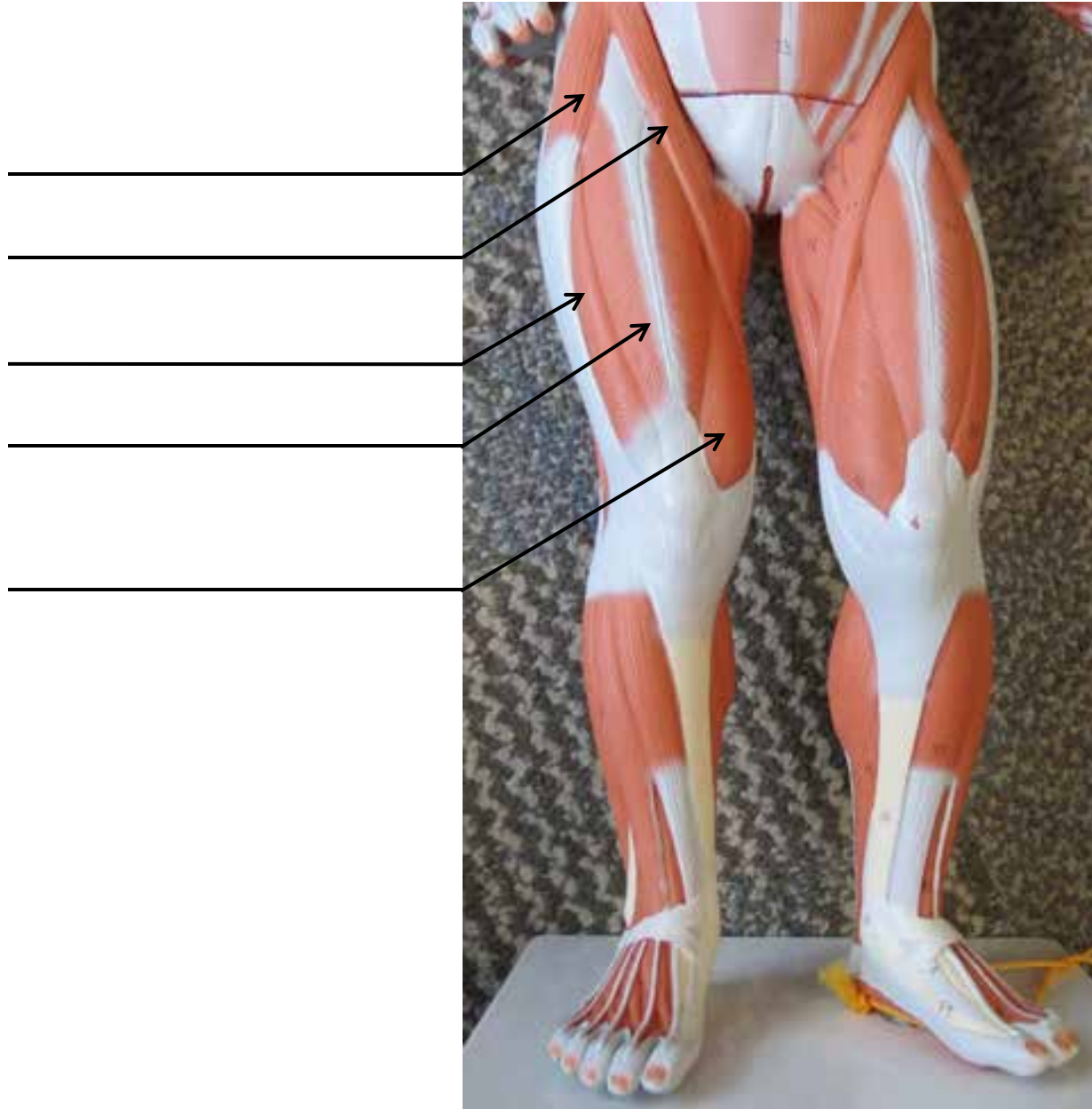
SMALL MUSCULAR MODELS




SMALL MUSCULAR MODELS




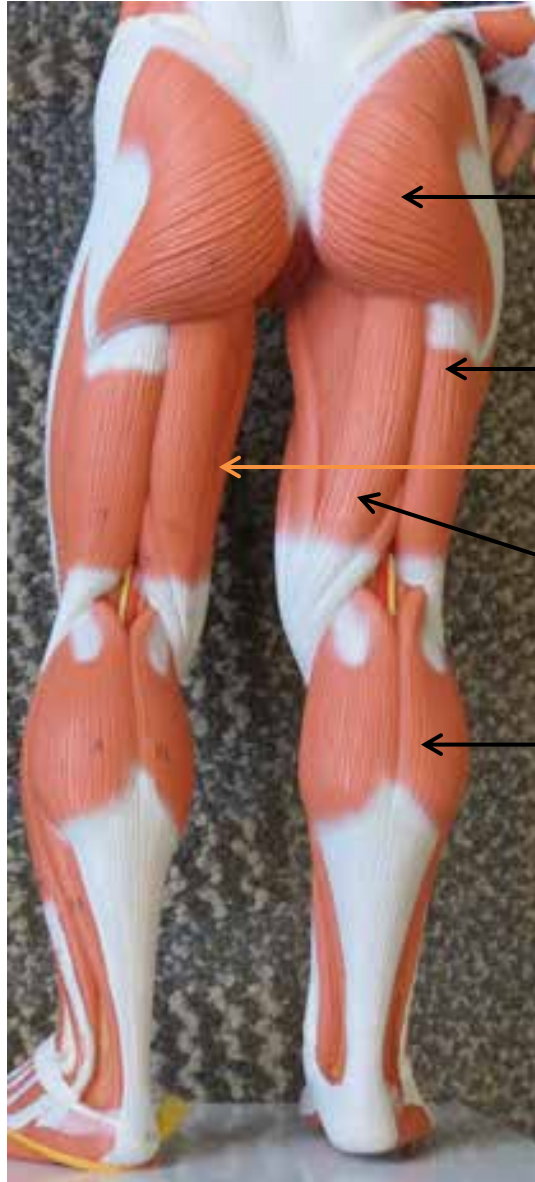
SMALL MUSCULAR MODELS



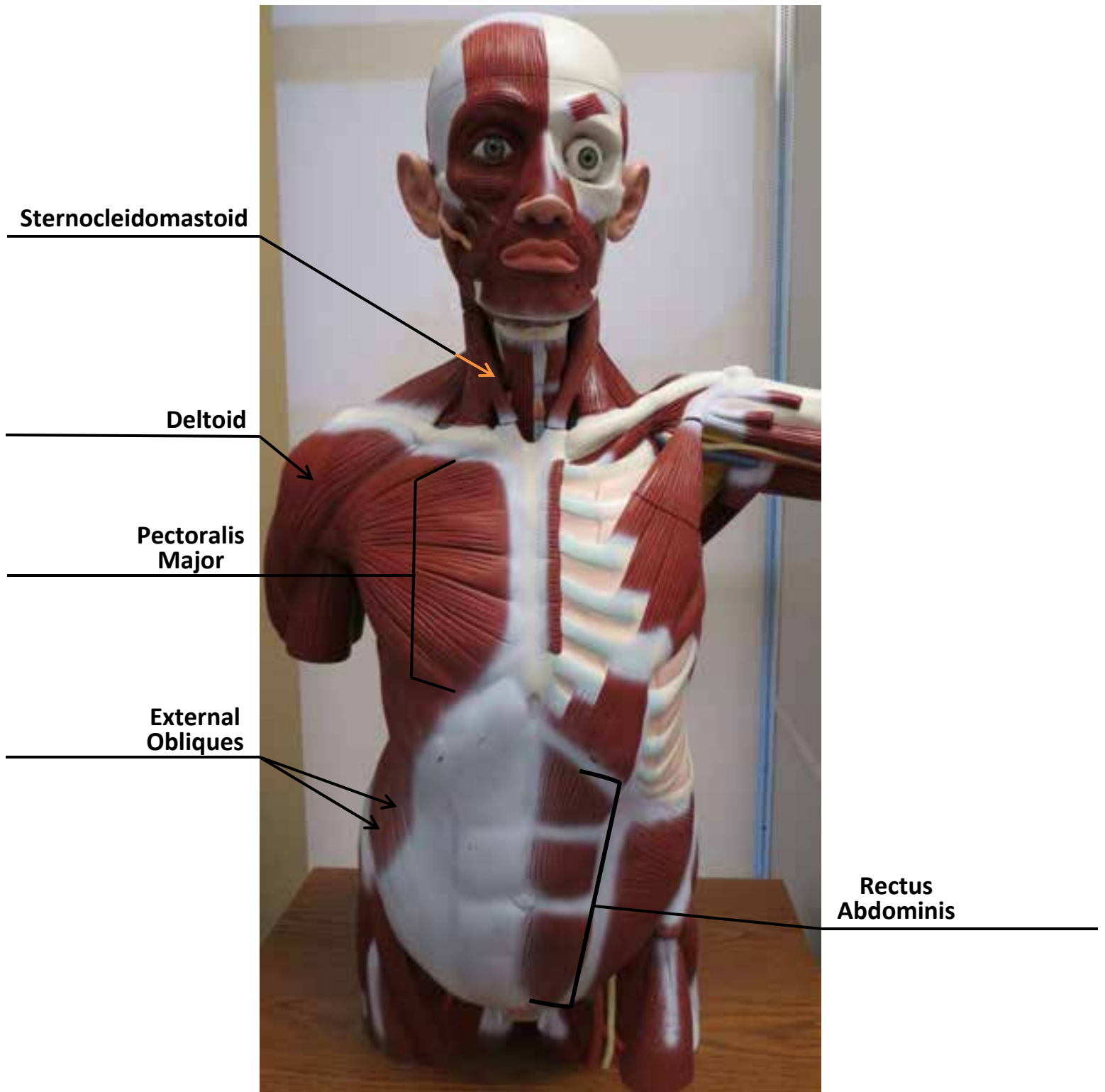
SMALL MUSCULAR MODELS



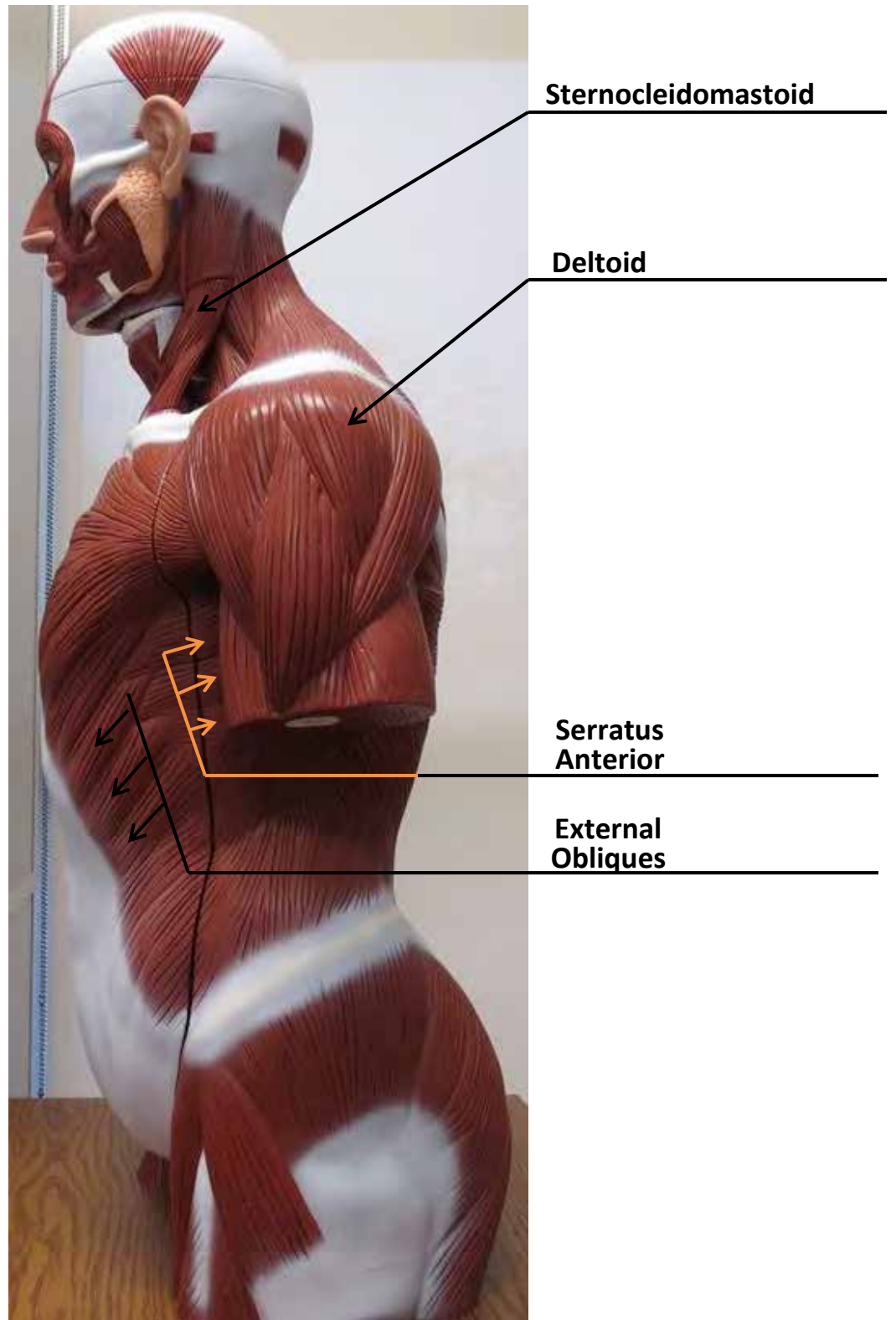
SMALL MUSCULAR MODELS



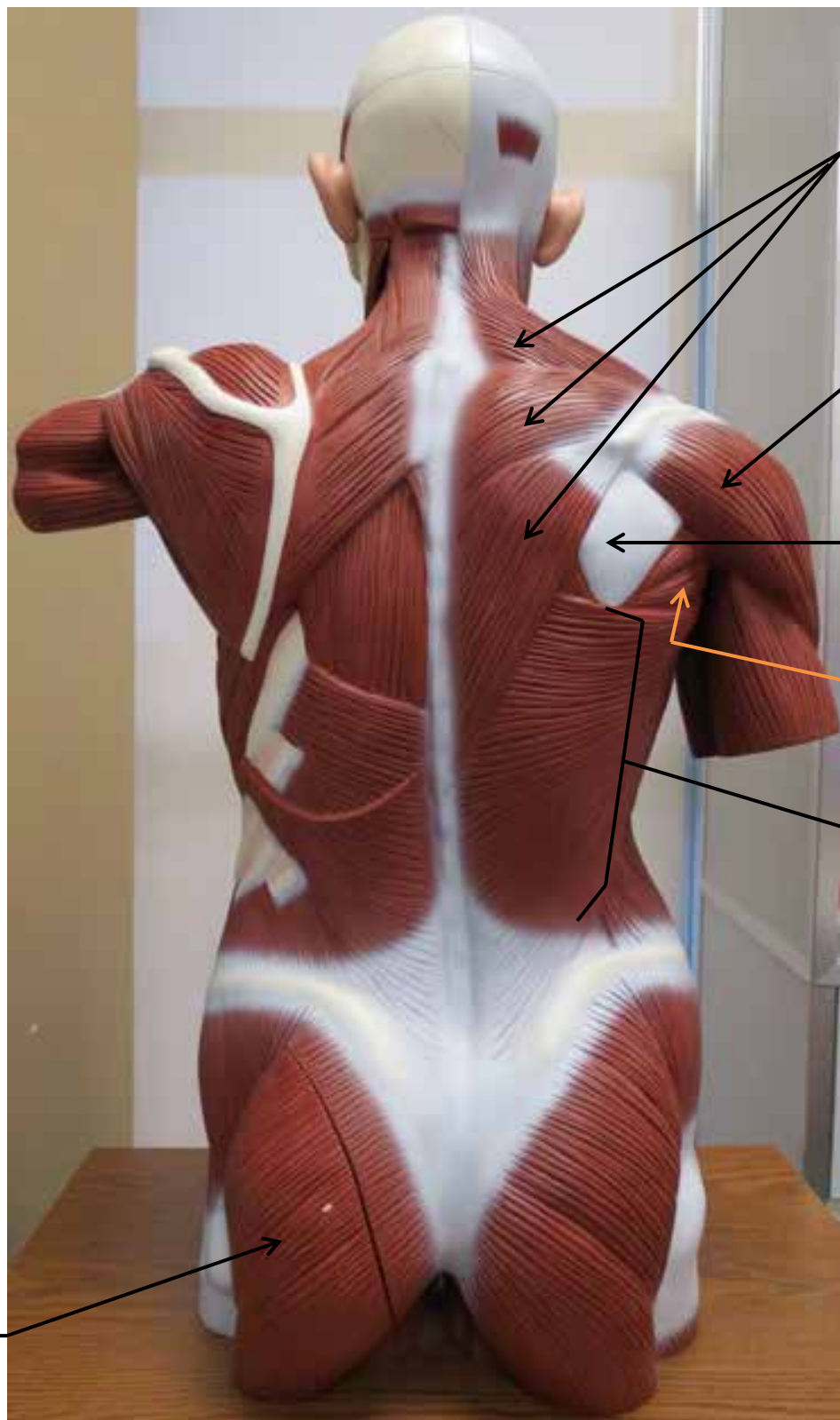LARGE MUSCLE MODEL



LARGE MUSCLE MODEL



LARGE MUSCLE MODEL



Trapezius

Deltoid

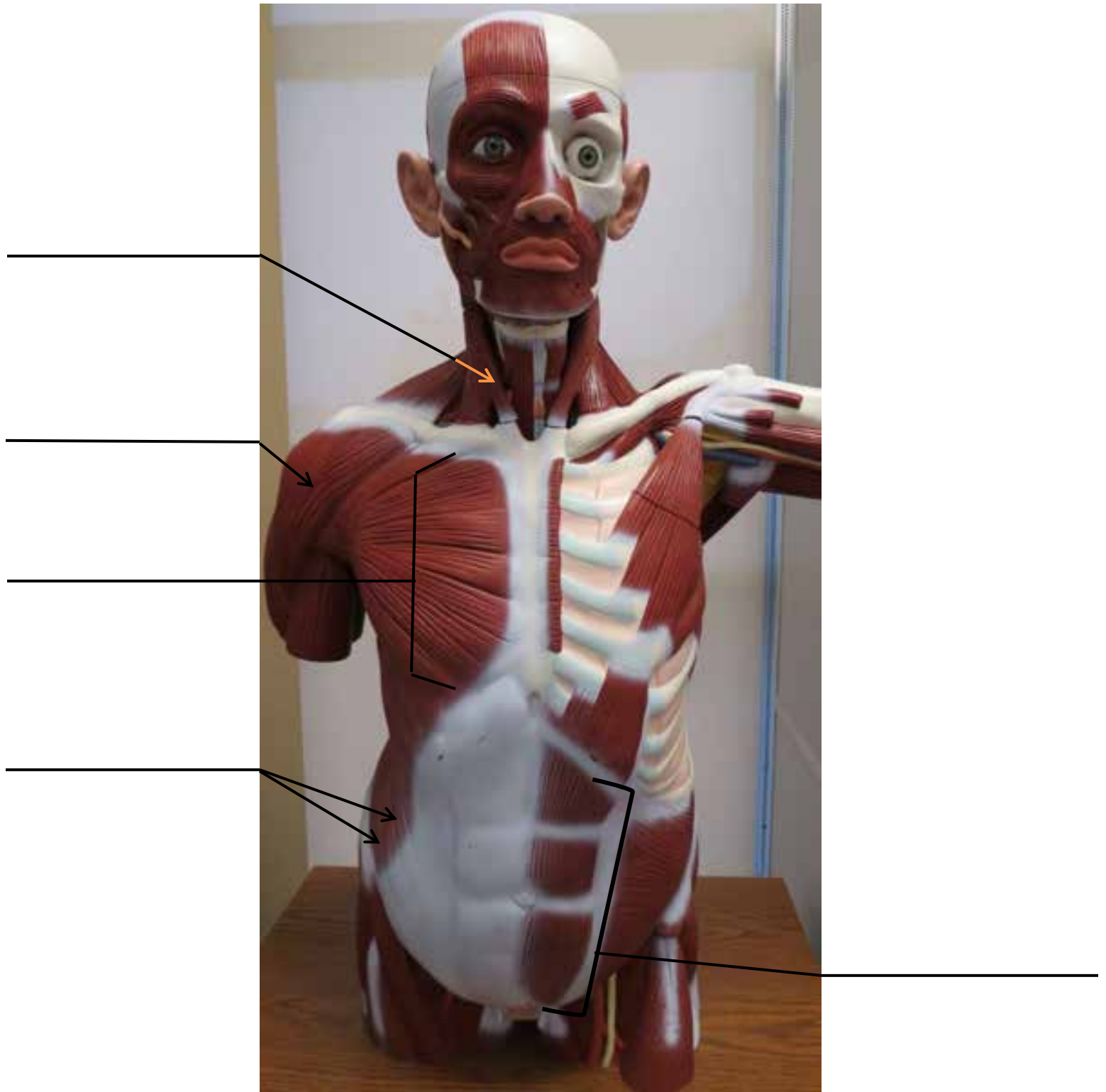
Infraspinatus

Teres Major

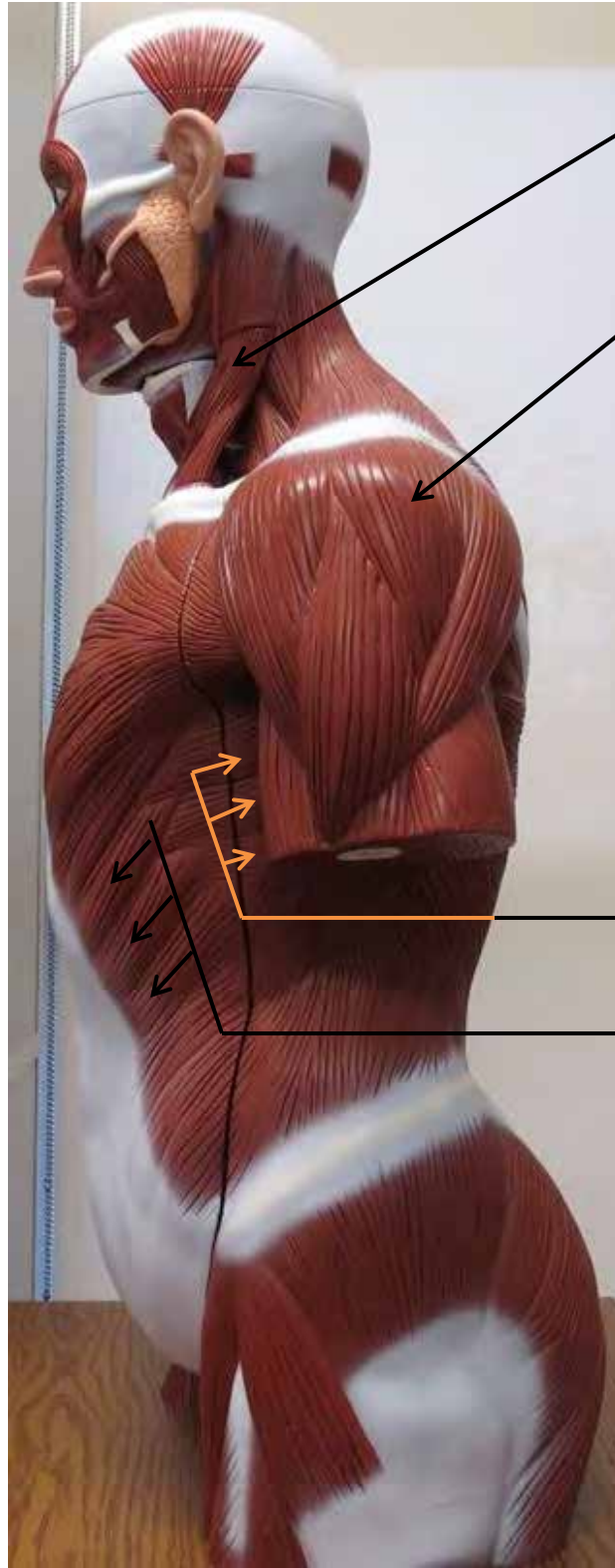
Latissimus Dorsi

Gluteus Maximus

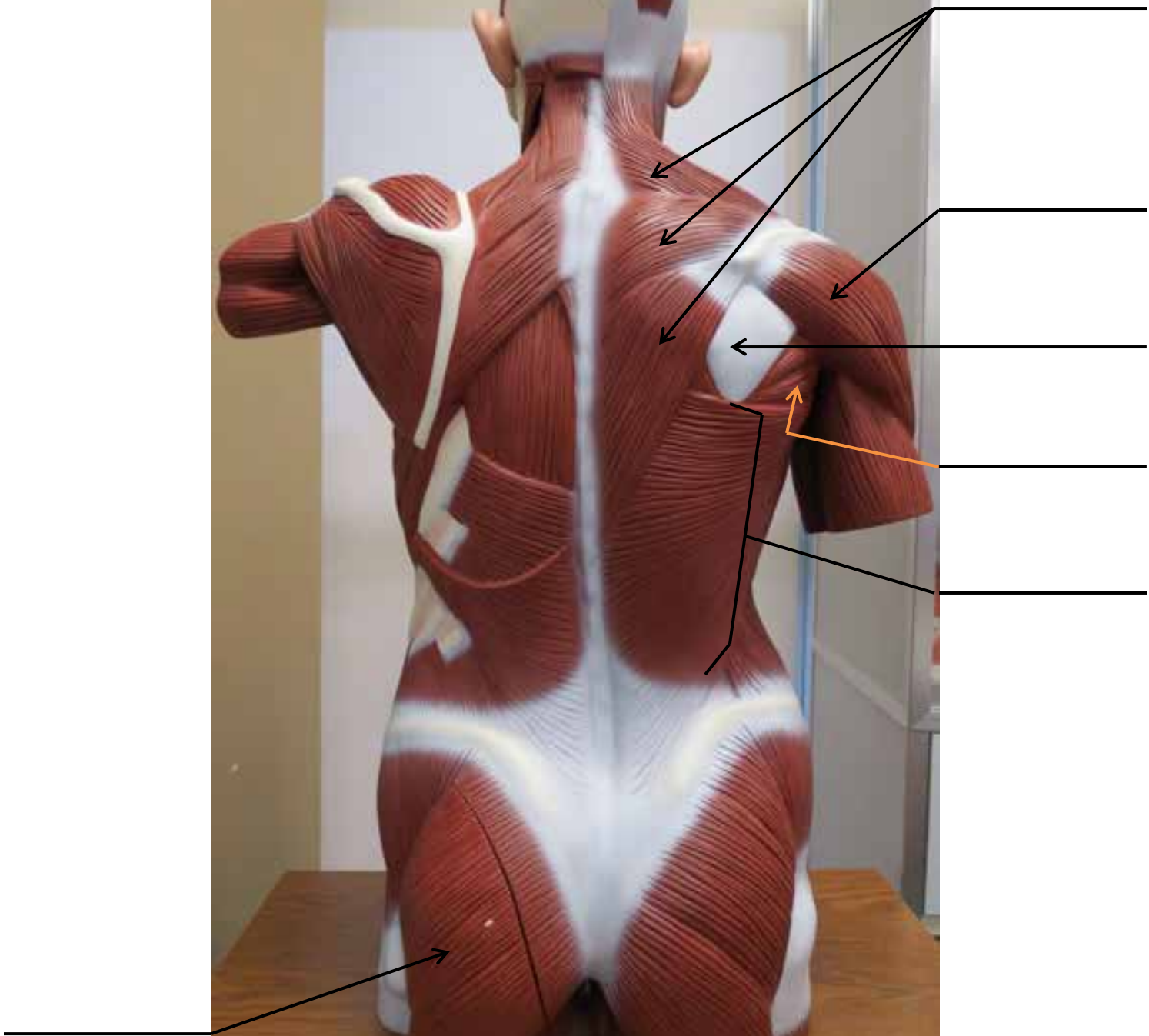
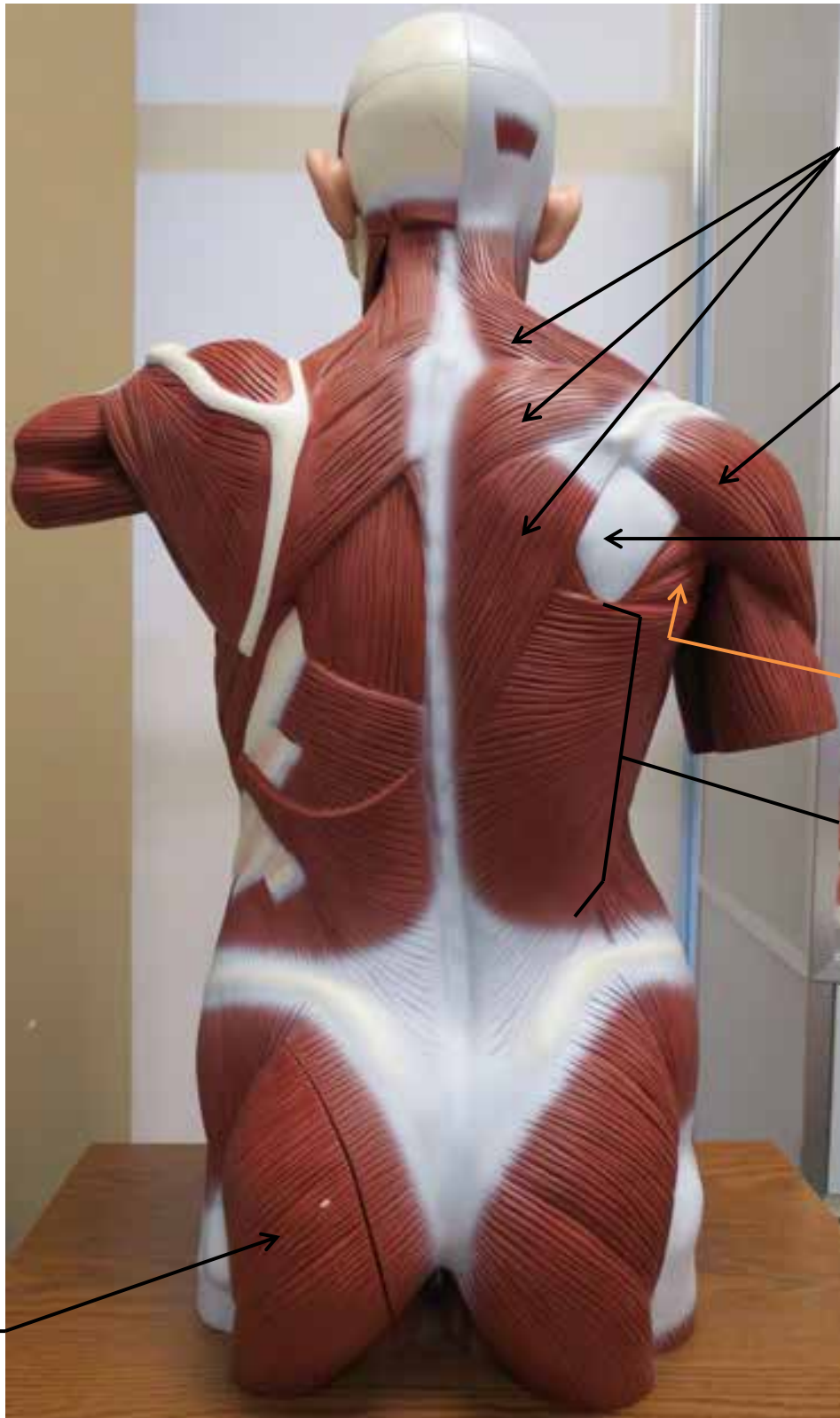LARGE MUSCLE MODEL



LARGE MUSCLE MODEL

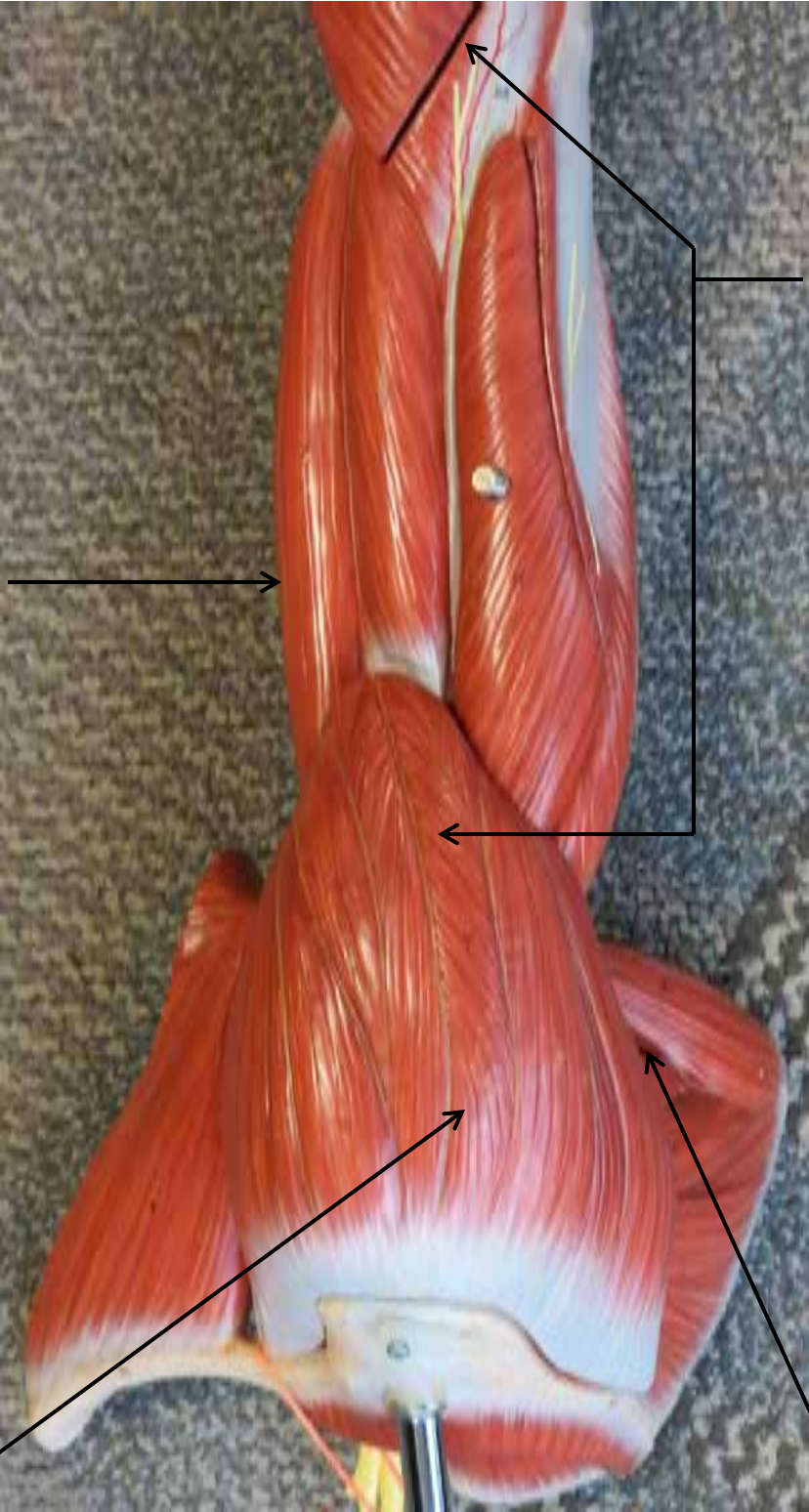


LARGE MUSCLE MODEL



ARM MODEL

Biceps Brachii



Triceps Brachii

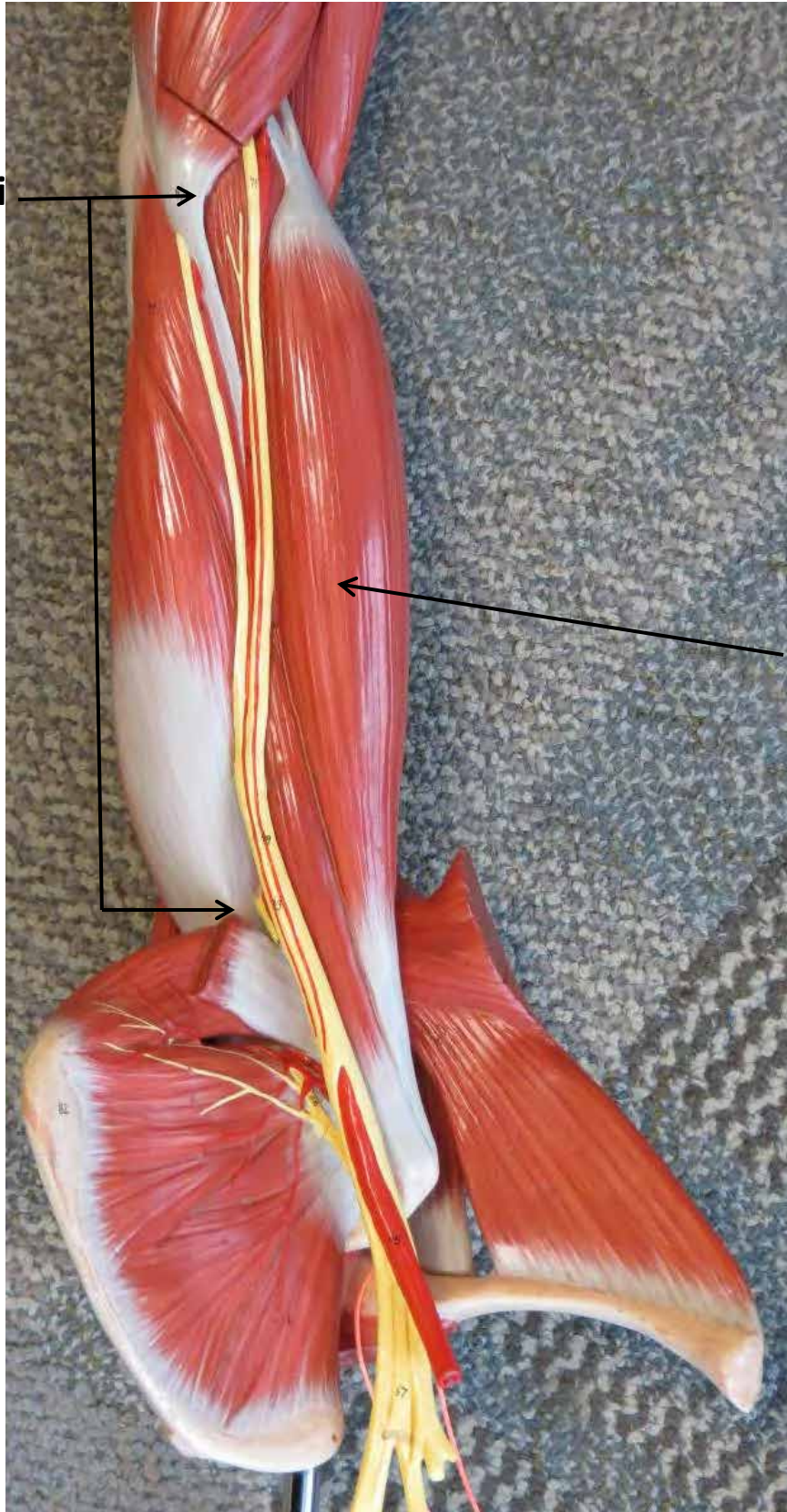

Deltoid

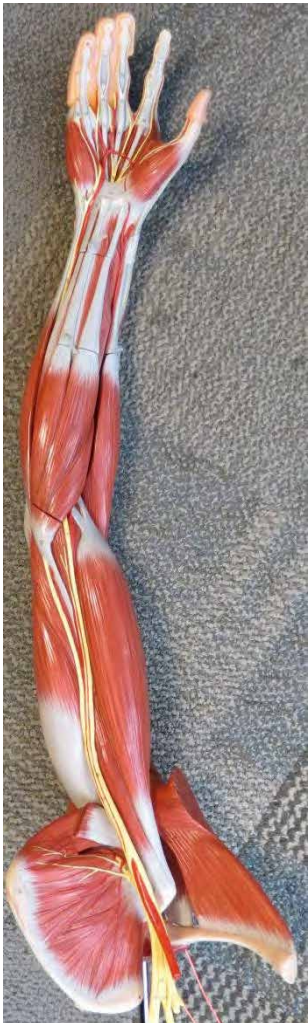Teres Major

ARM MODEL

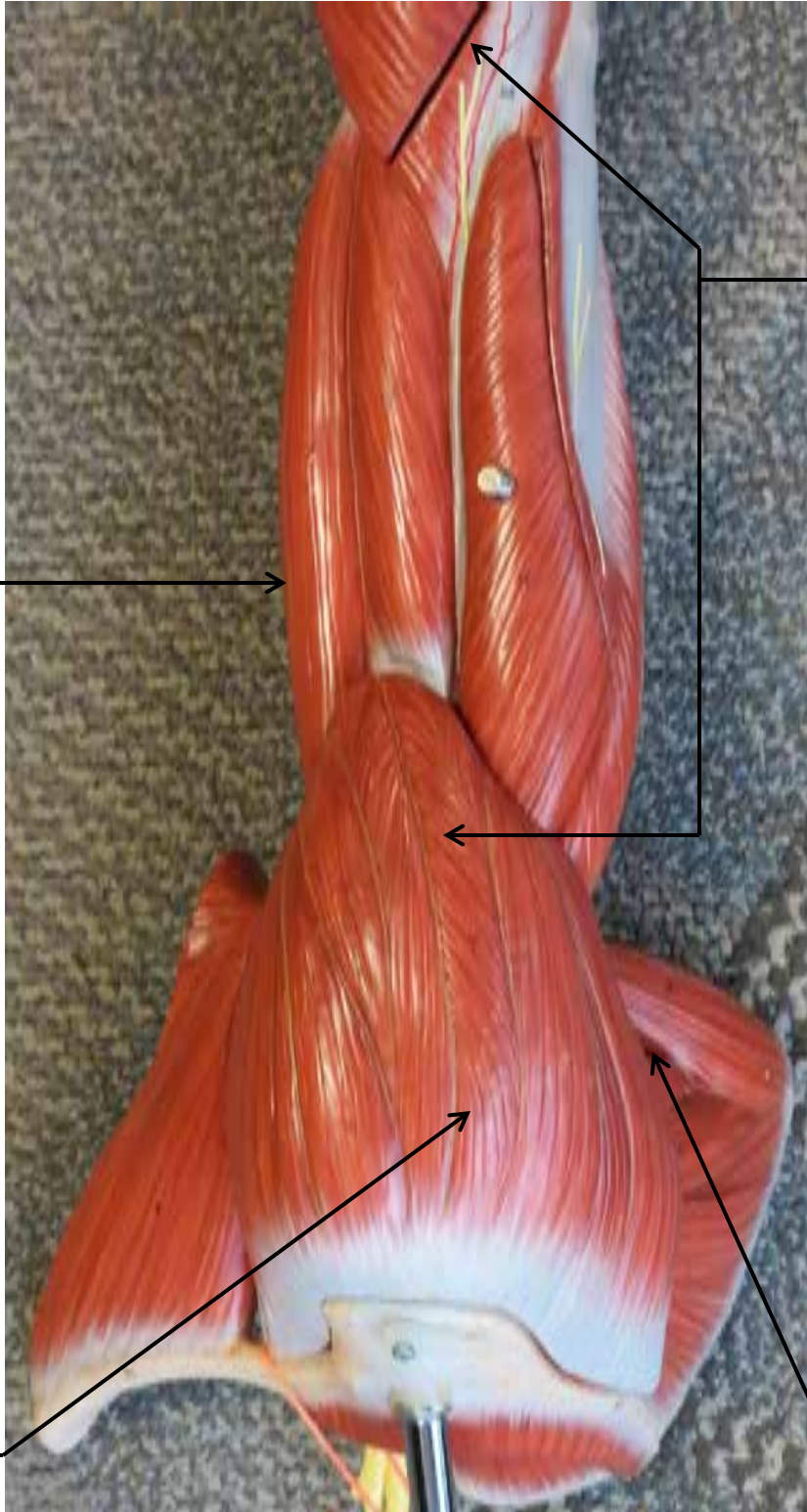
Triceps Brachii



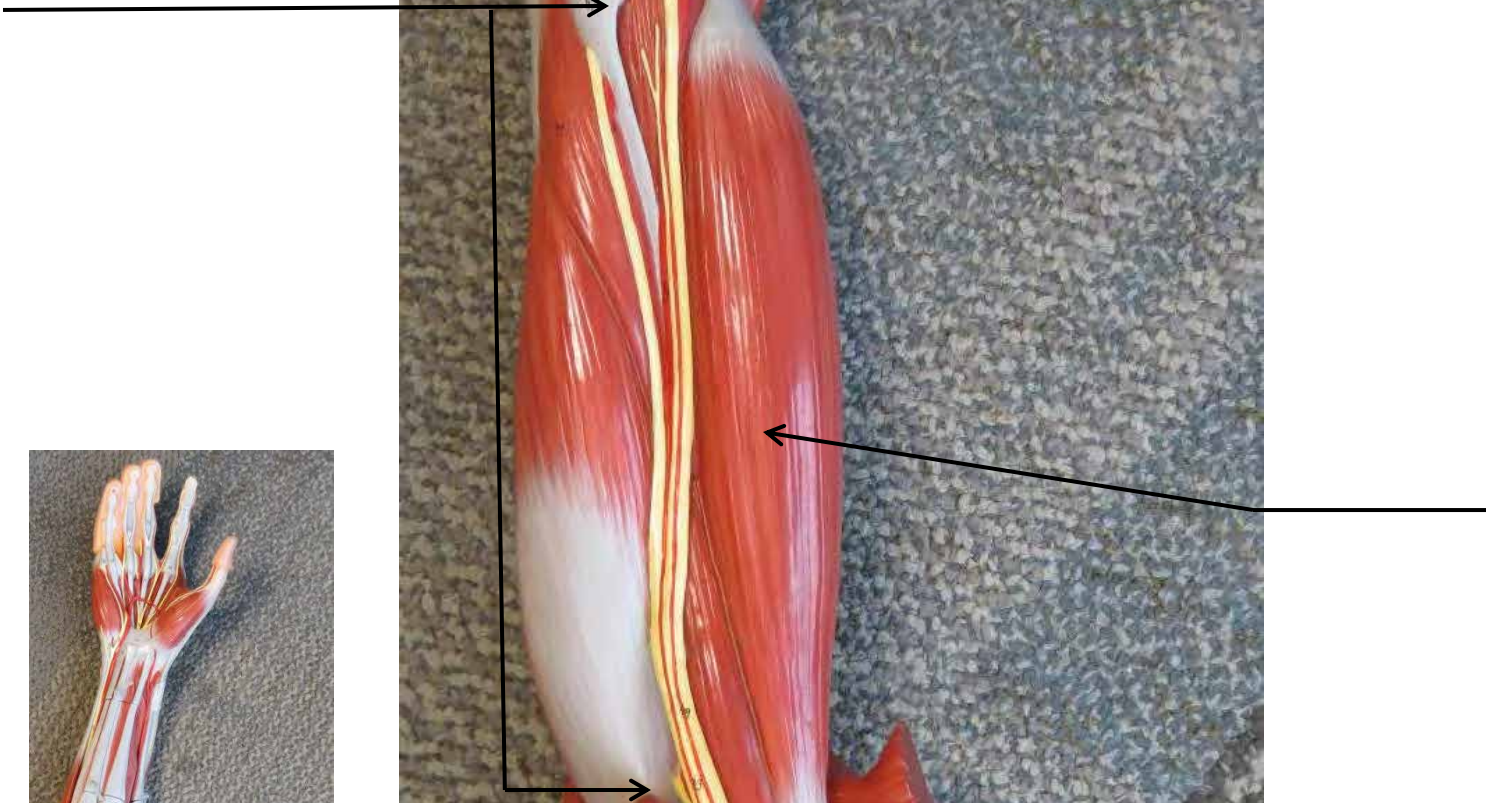
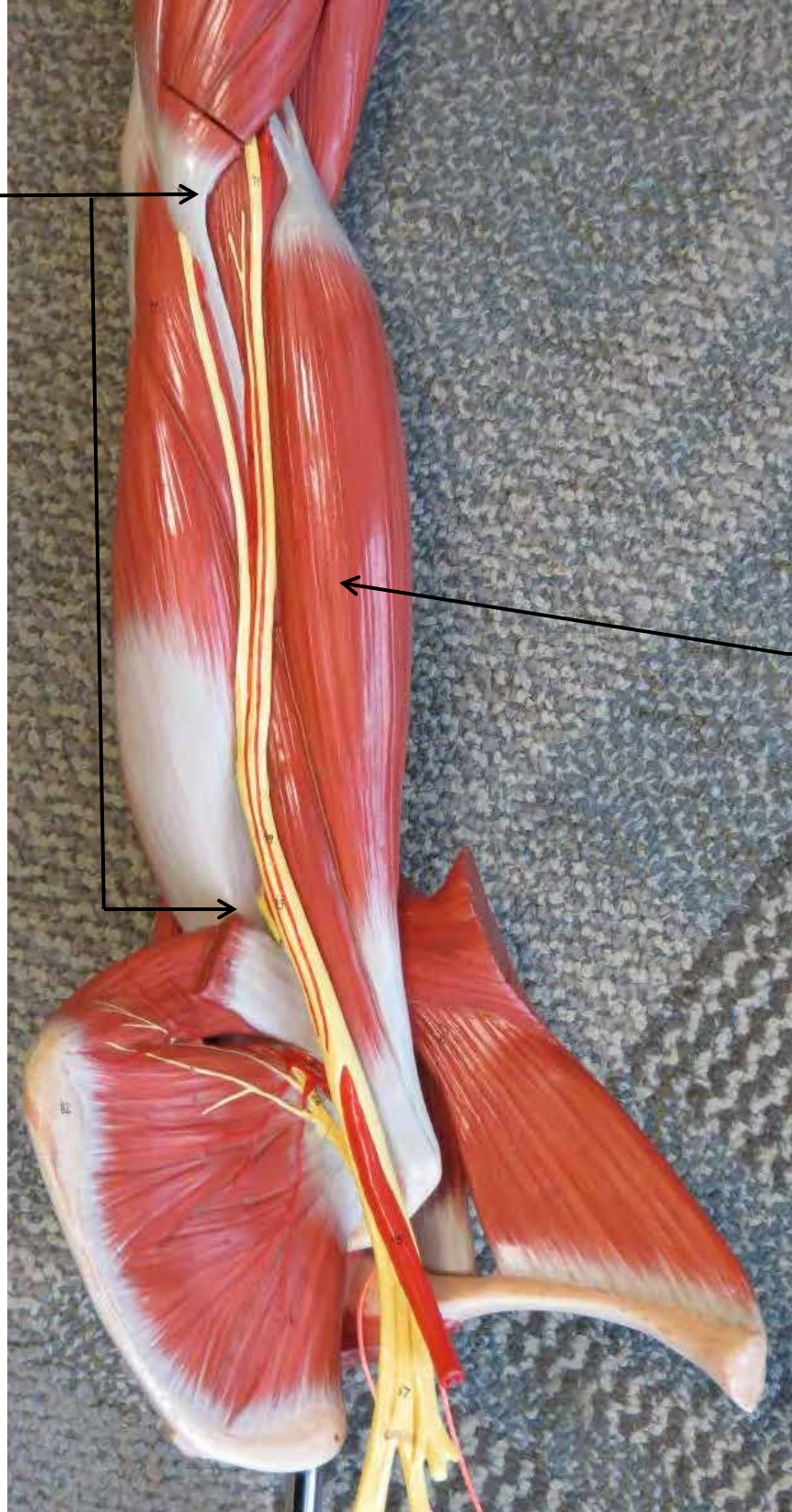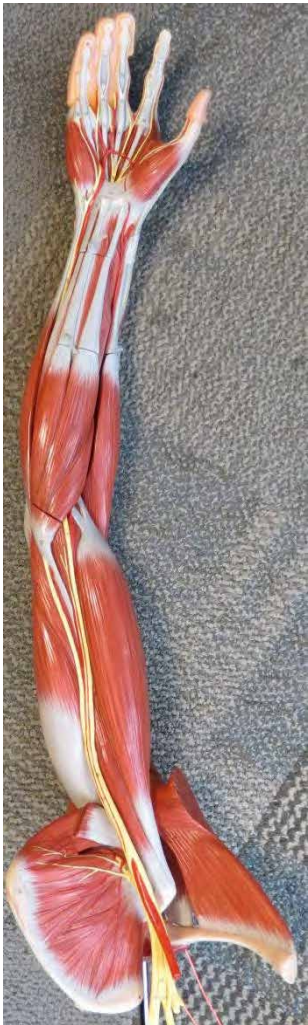**Biceps
Brachii**



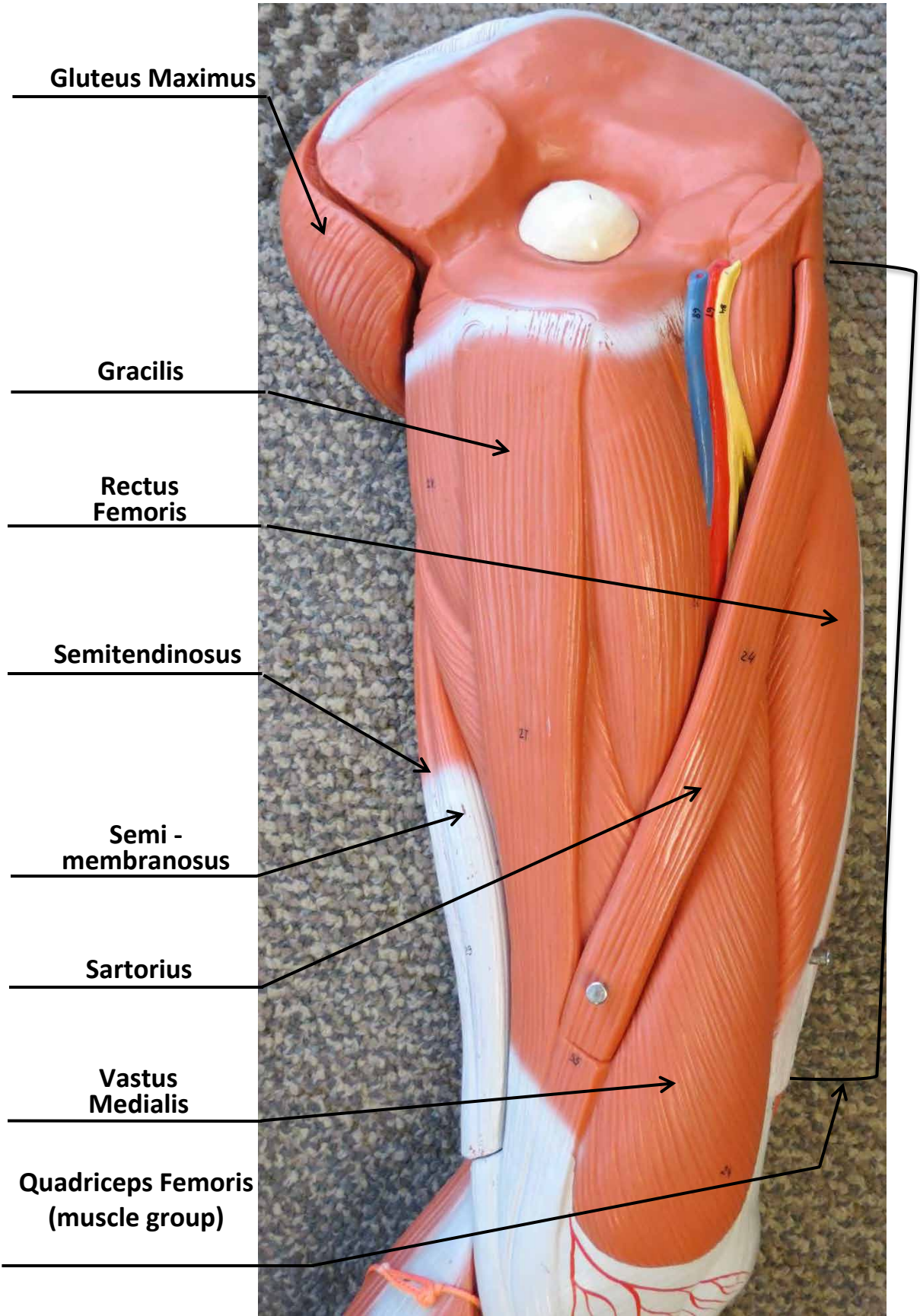
ARM MODEL



ARM MODEL



LEG MUSCLE MODEL



Gluteus Maximus

Gracilis

Rectus Femoris

Semitendinosus

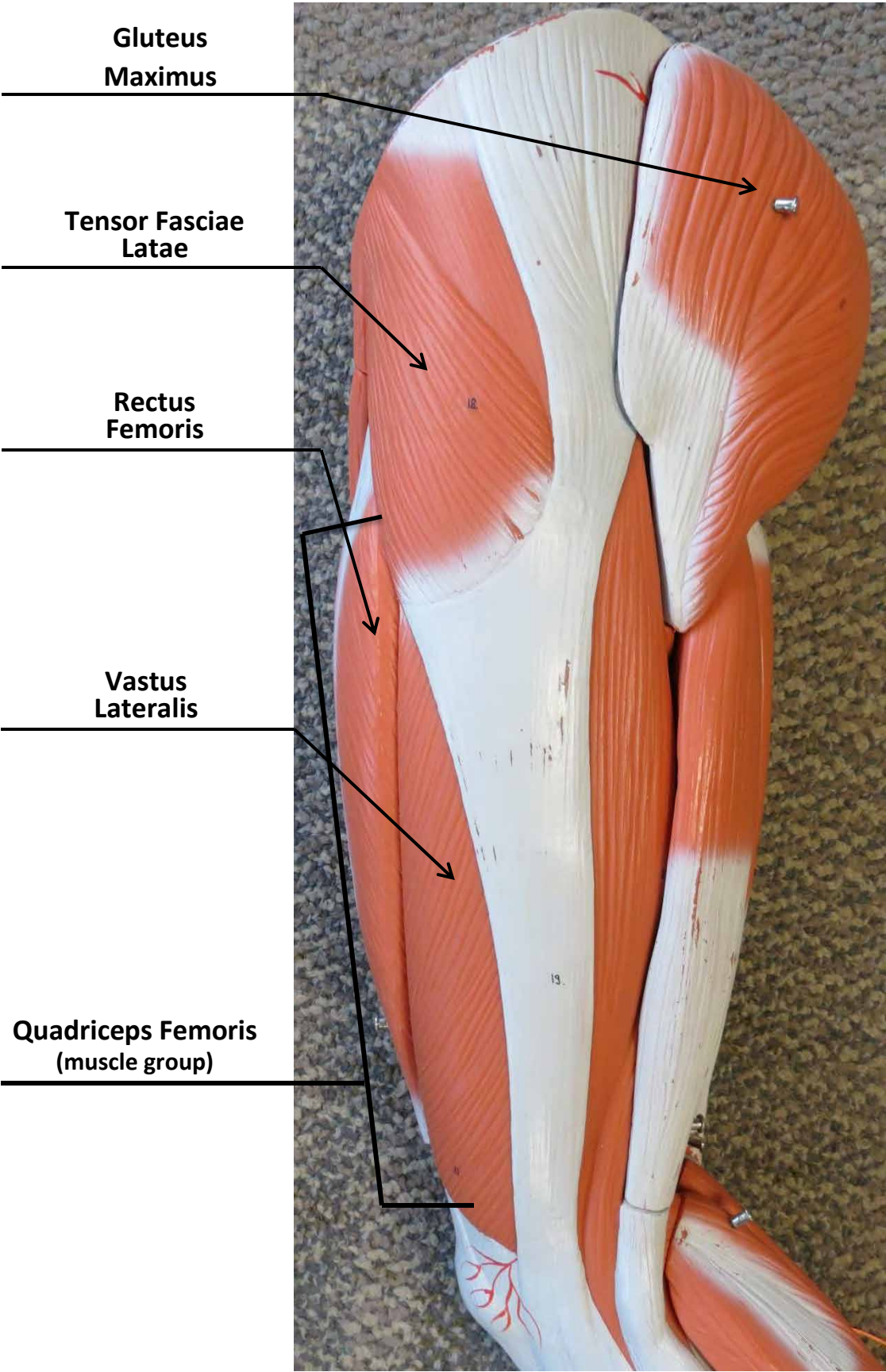
**Semi -
membranosus**

Sartorius


**Vastus
Medialis**

**Quadriceps Femoris
(muscle group)**

LEG MUSCLE MODEL



LEG MUSCLE MODEL



Gluteus Maximus




Biceps Femoris

Semimembranosus

Semitendinosus

Hamstring Muscle Group


Gastrocnemius



LEG MUSCLE MODEL

Sartorius

Tensor Fasciae Latae



Rectus Femoris



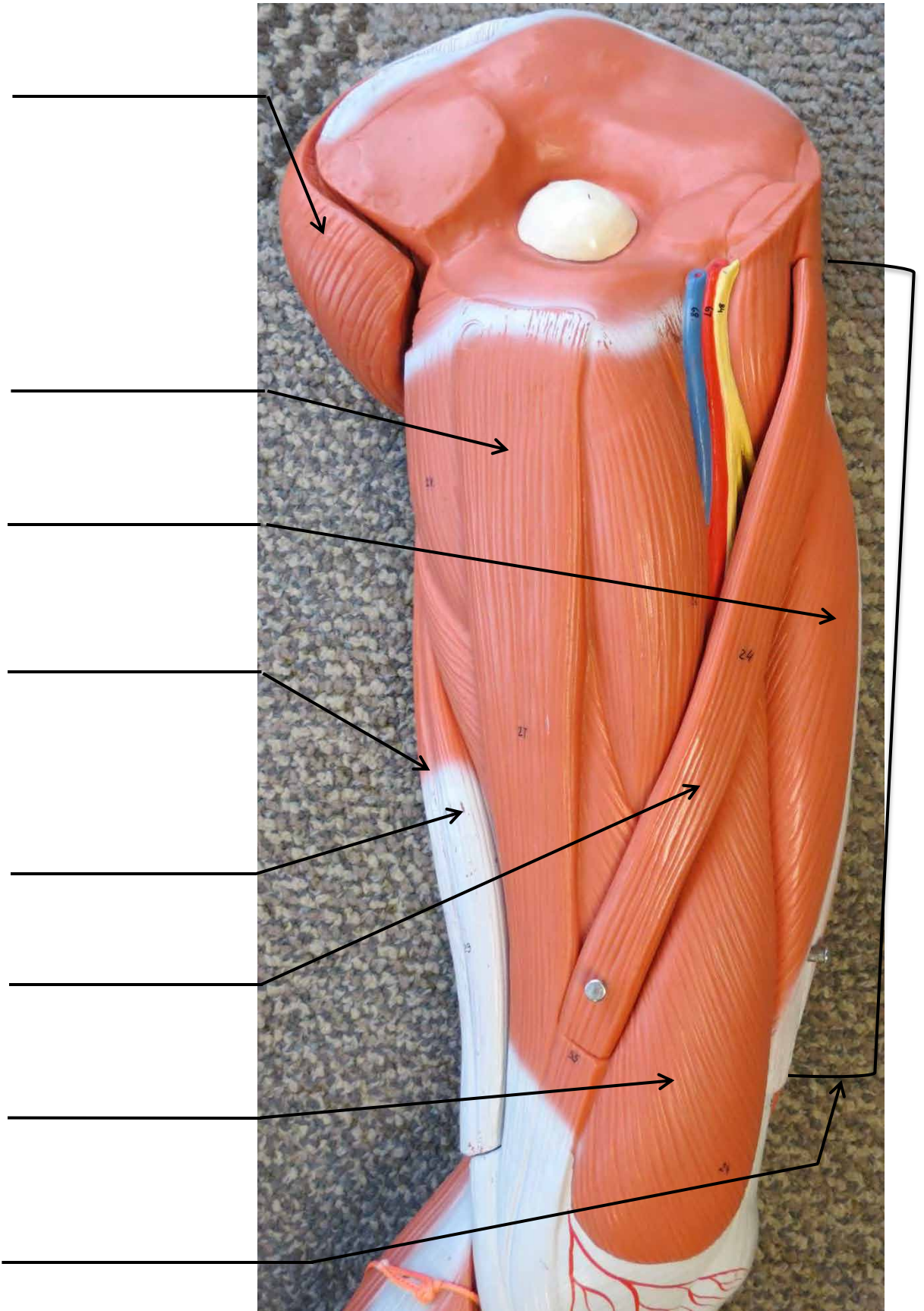
Quadriceps Femoris

Vastus Lateralis

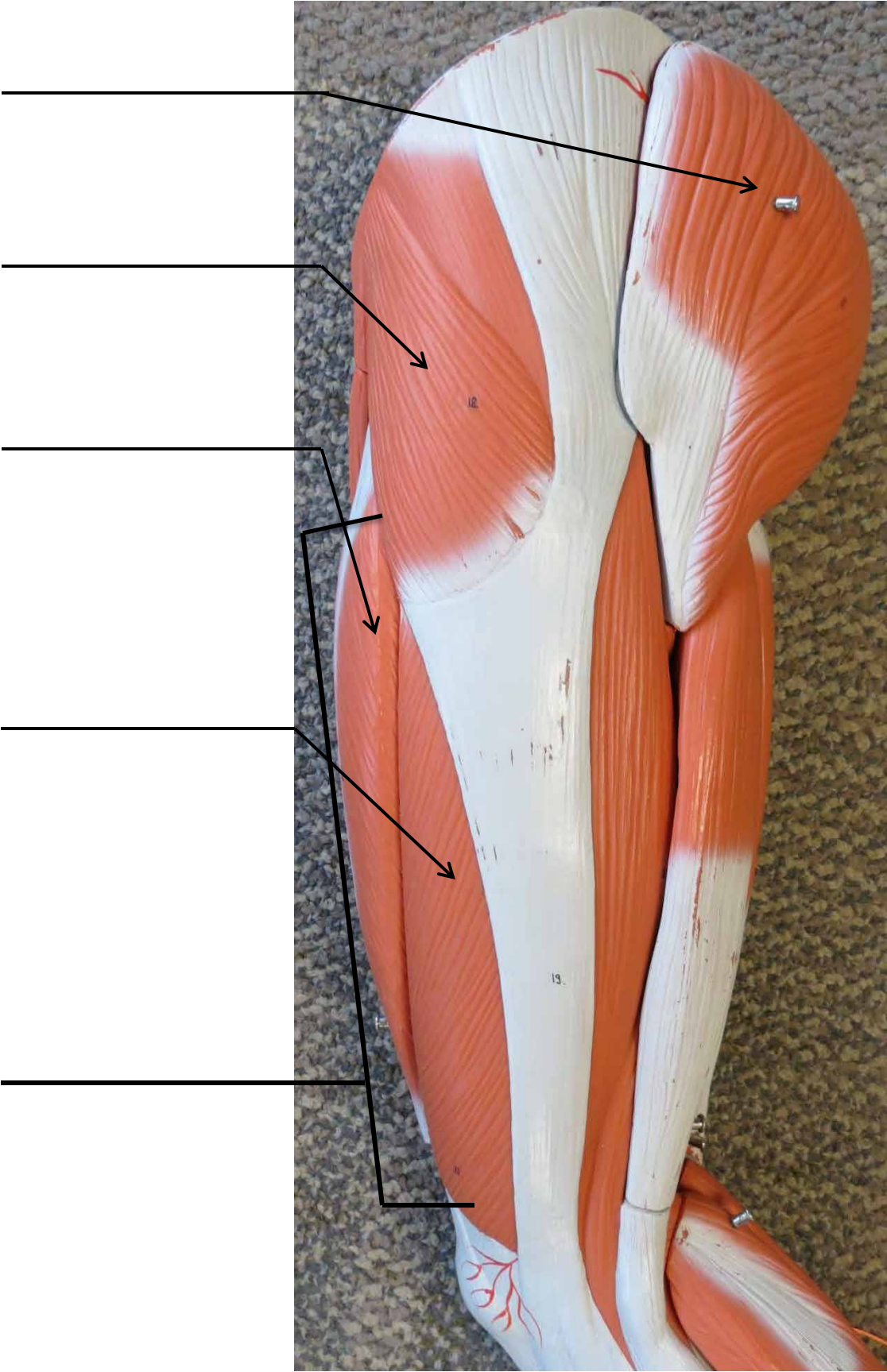
Vastus Medialis



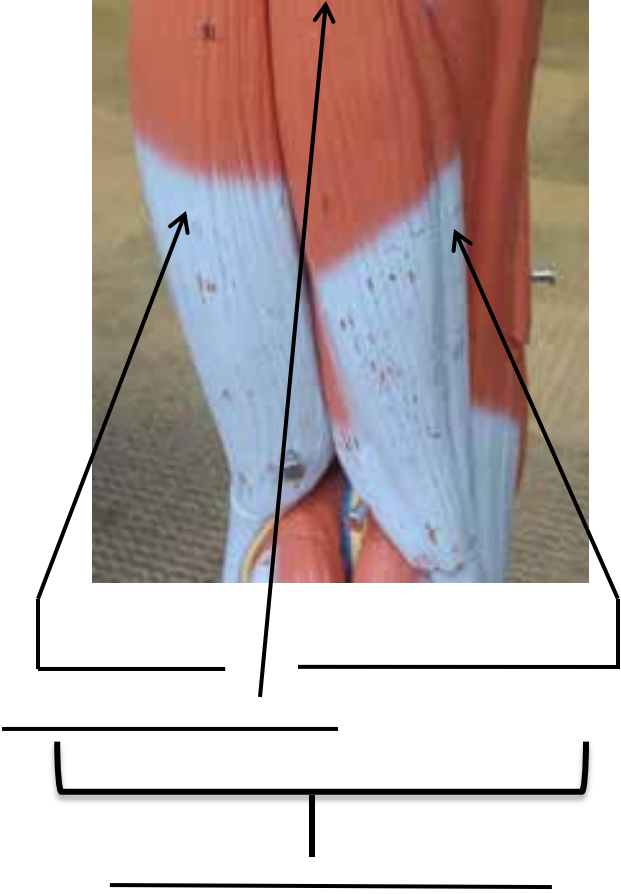

LEG MUSCLE MODEL



LEG MUSCLE MODEL



LEG MUSCLE MODEL



LEG MUSCLE MODEL

