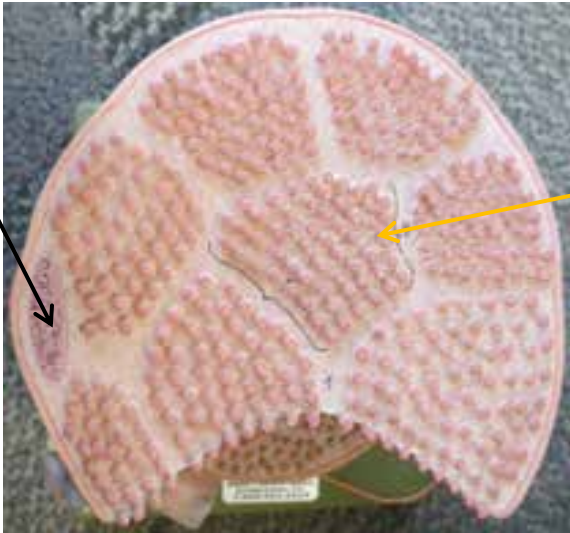
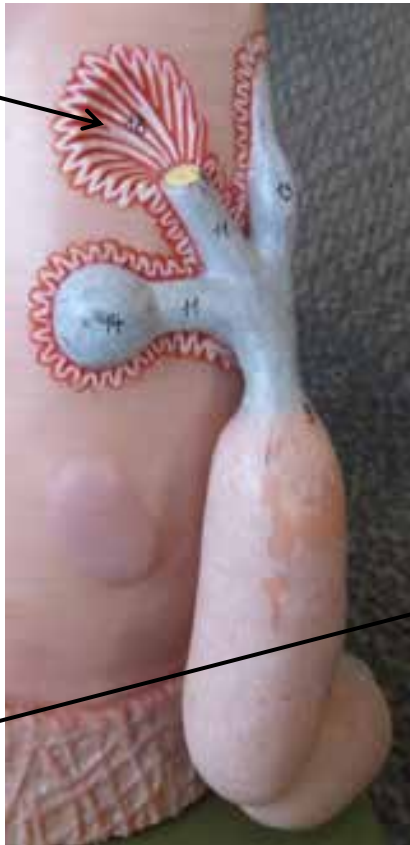

# MUSCLE FIBER MODEL


Nucleus



Motor Endplate



Motor Neuron



Myofibrils

A Band  
(dark band on myofibril)

I Band  
(light band on myofibril)

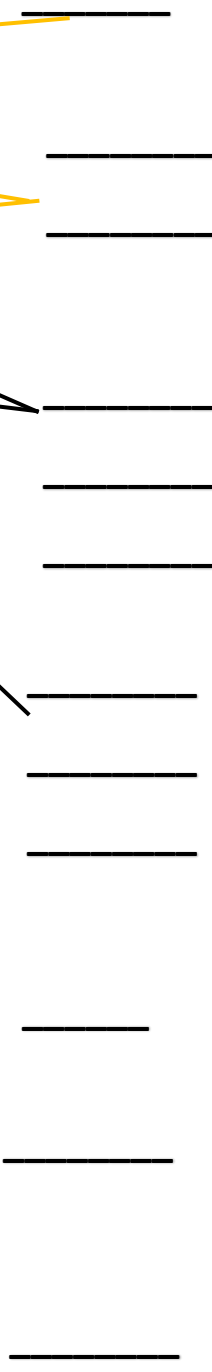
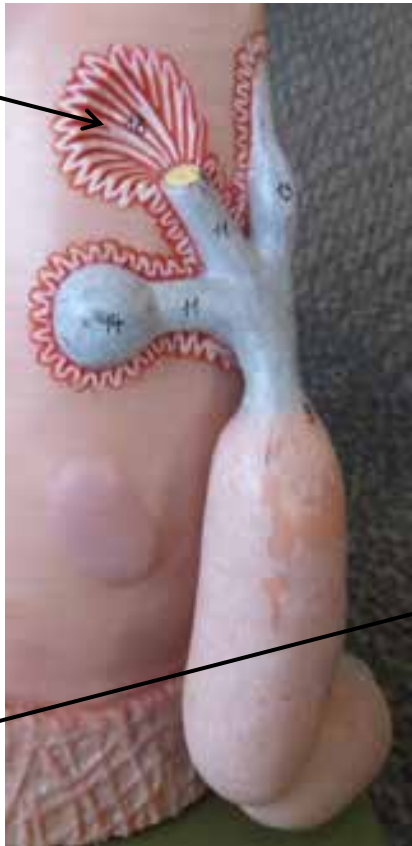
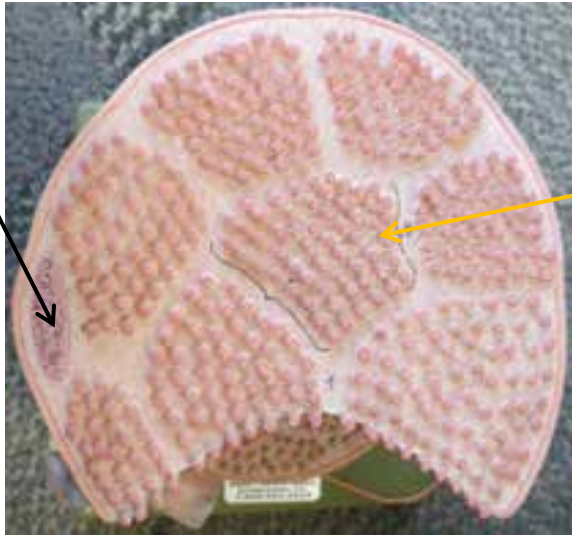
Z - Disk  
(lines moving through I Bands)

Nucleus


Endomysium

Sarcolemma

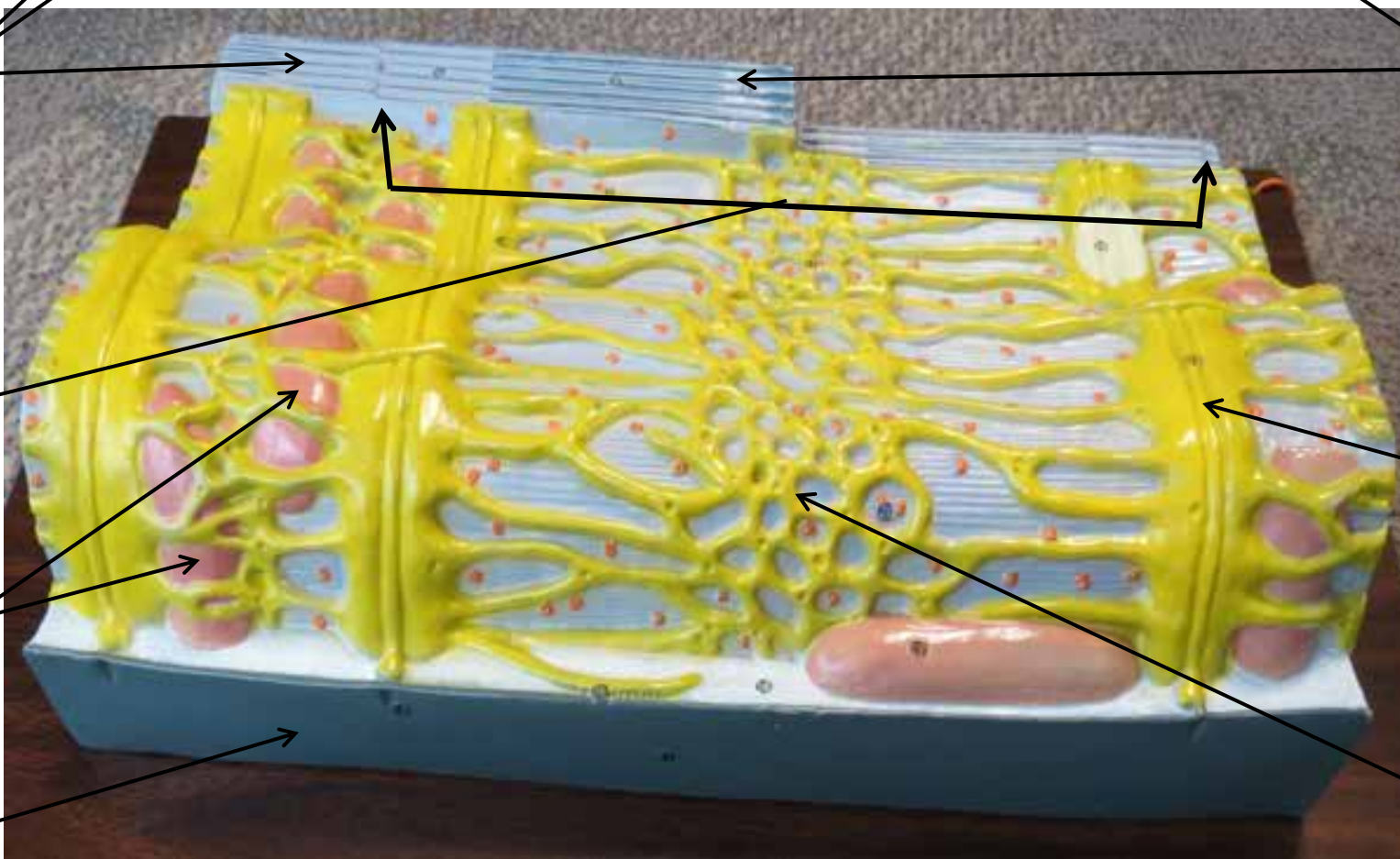
# MUSCLE FIBER MODEL



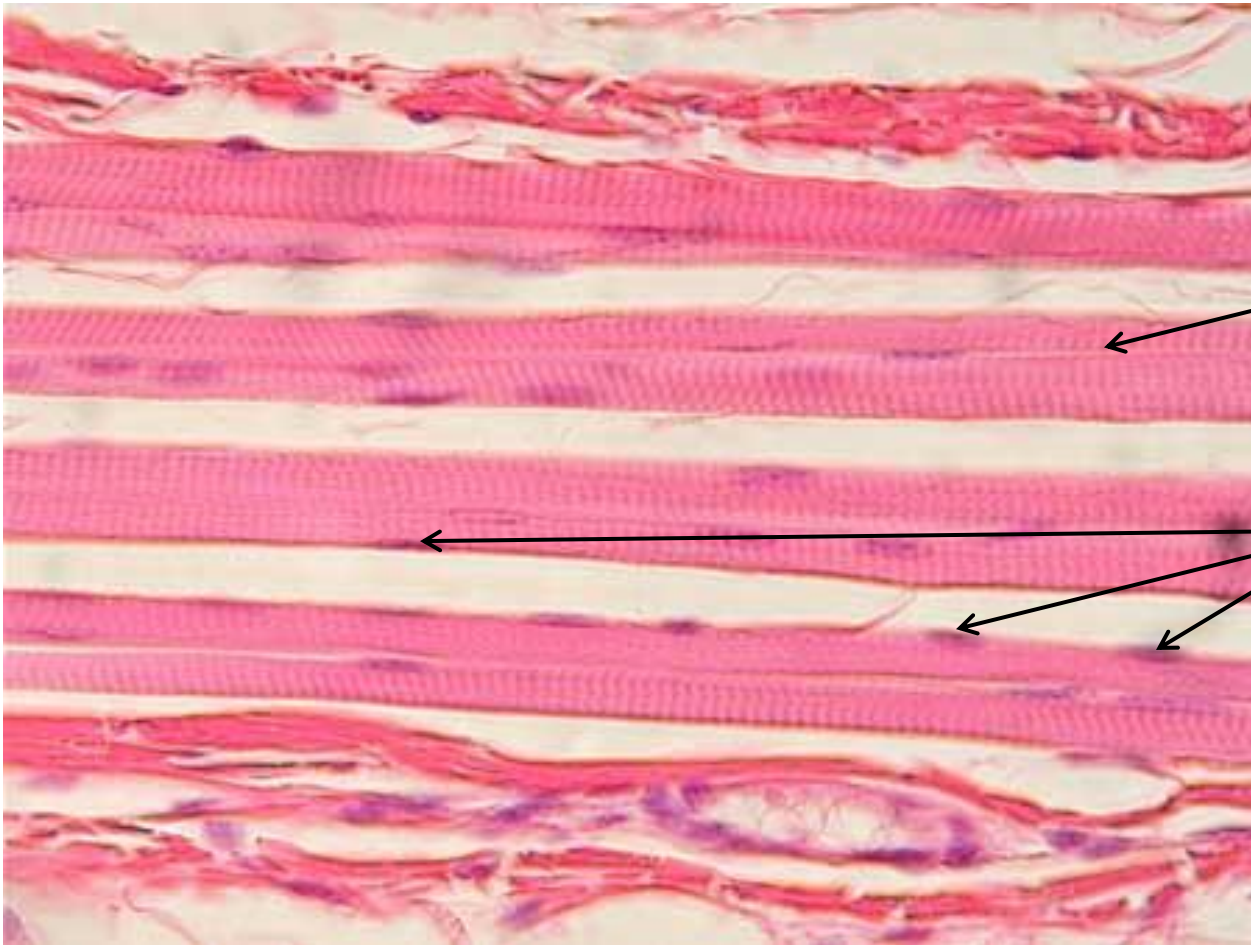
# Muscle Fiber Model With Sacroplasmic Reticulum



# Muscle Fiber Model With Sacroplasmic Reticulum

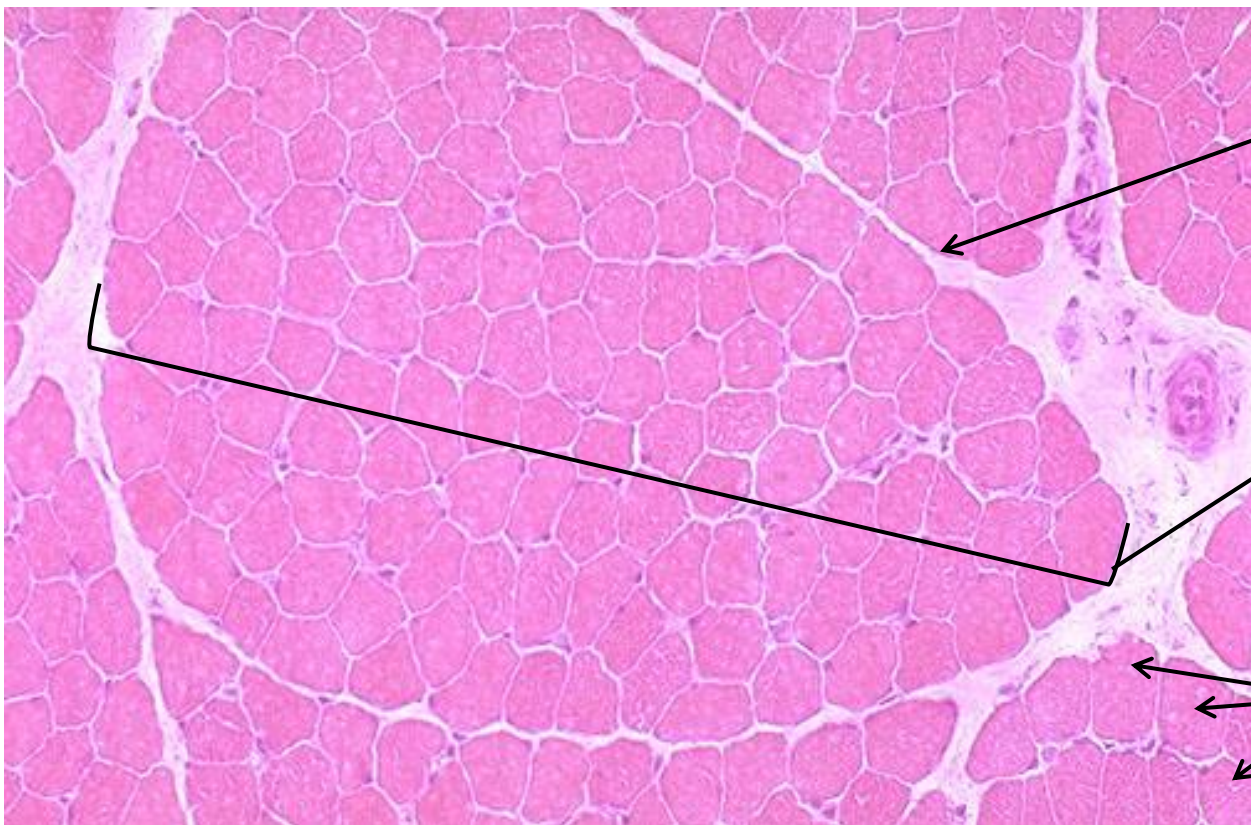


# SKELETAL MUSCLE SLIDE



Striations  
(alternating  
dark and  
light lines)

Nuclei

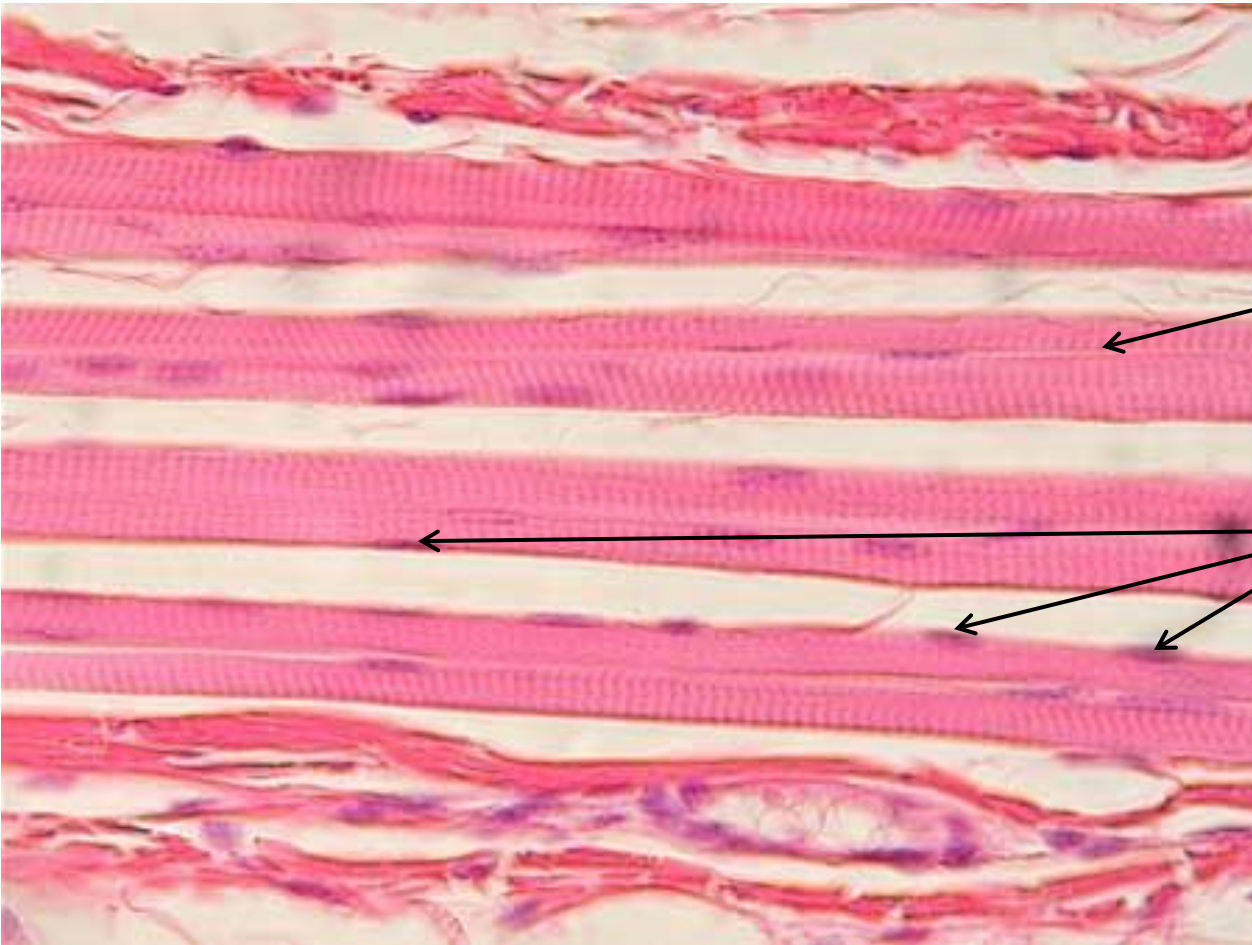


Perimysium  
(connective  
tissue  
surrounding  
fasciculi)

Fasciculi  
(bundle  
of muscle  
fibers)

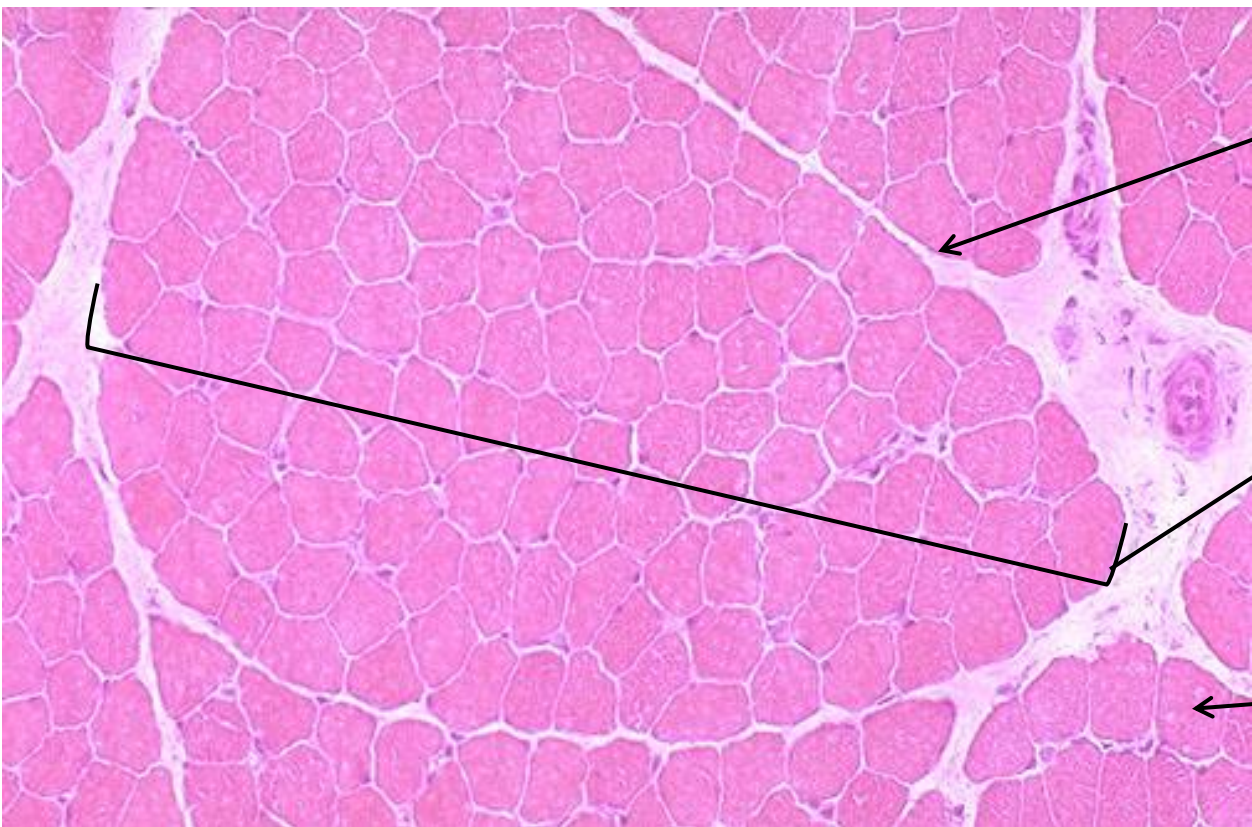
Muscle  
Fibers

# SKELETAL MUSCLE SLIDE



\_\_\_\_\_  
\_\_\_\_\_  
\_\_\_\_\_

\_\_\_\_\_



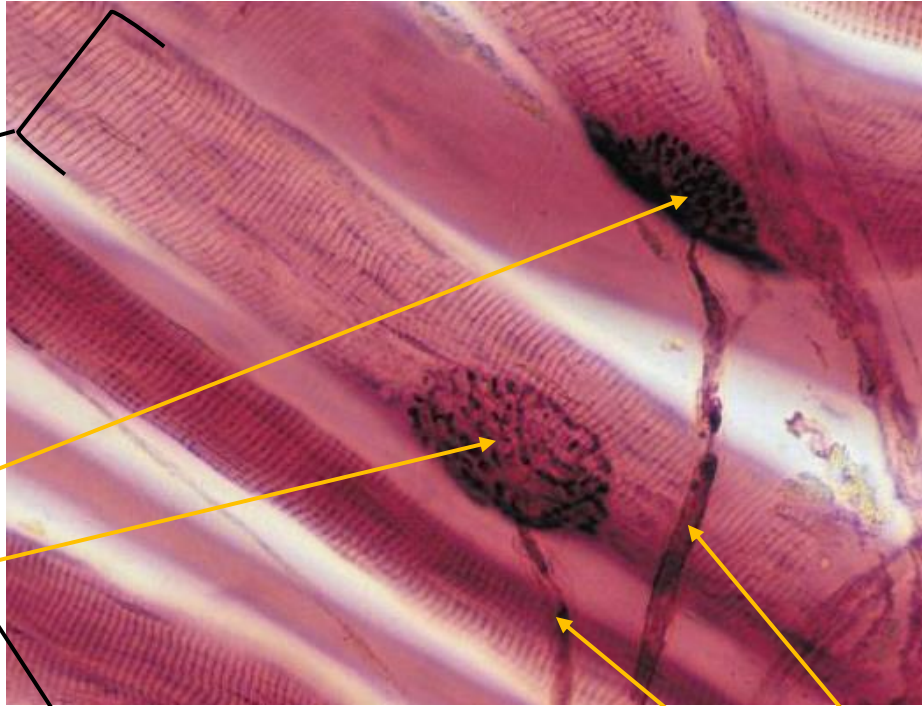
\_\_\_\_\_  
\_\_\_\_\_  
\_\_\_\_\_

\_\_\_\_\_  
\_\_\_\_\_  
\_\_\_\_\_

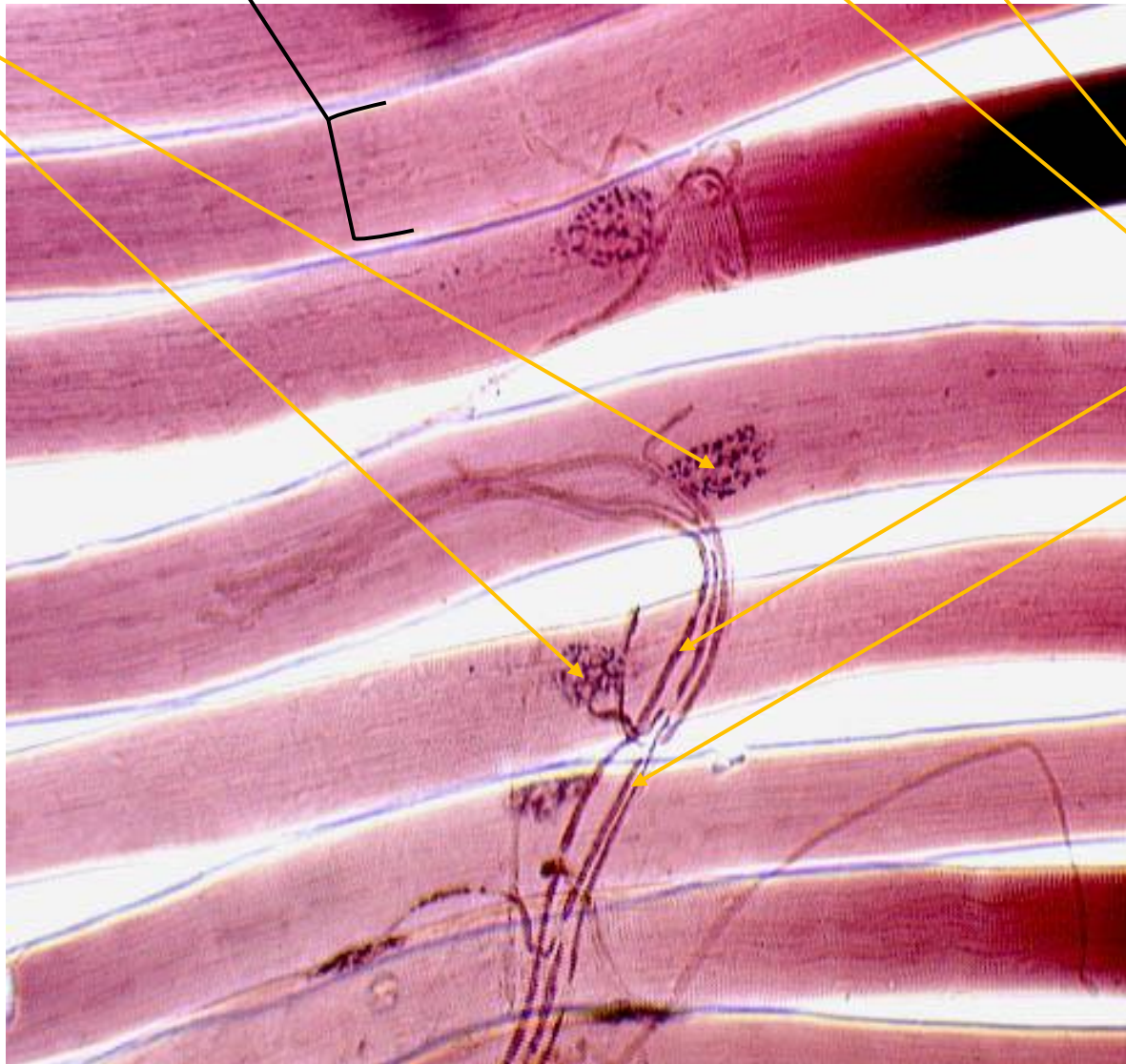
\_\_\_\_\_  
\_\_\_\_\_

# MOTOR END PLATE SLIDES

Skeletal  
Muscle  
Fibers  
(note  
striations)

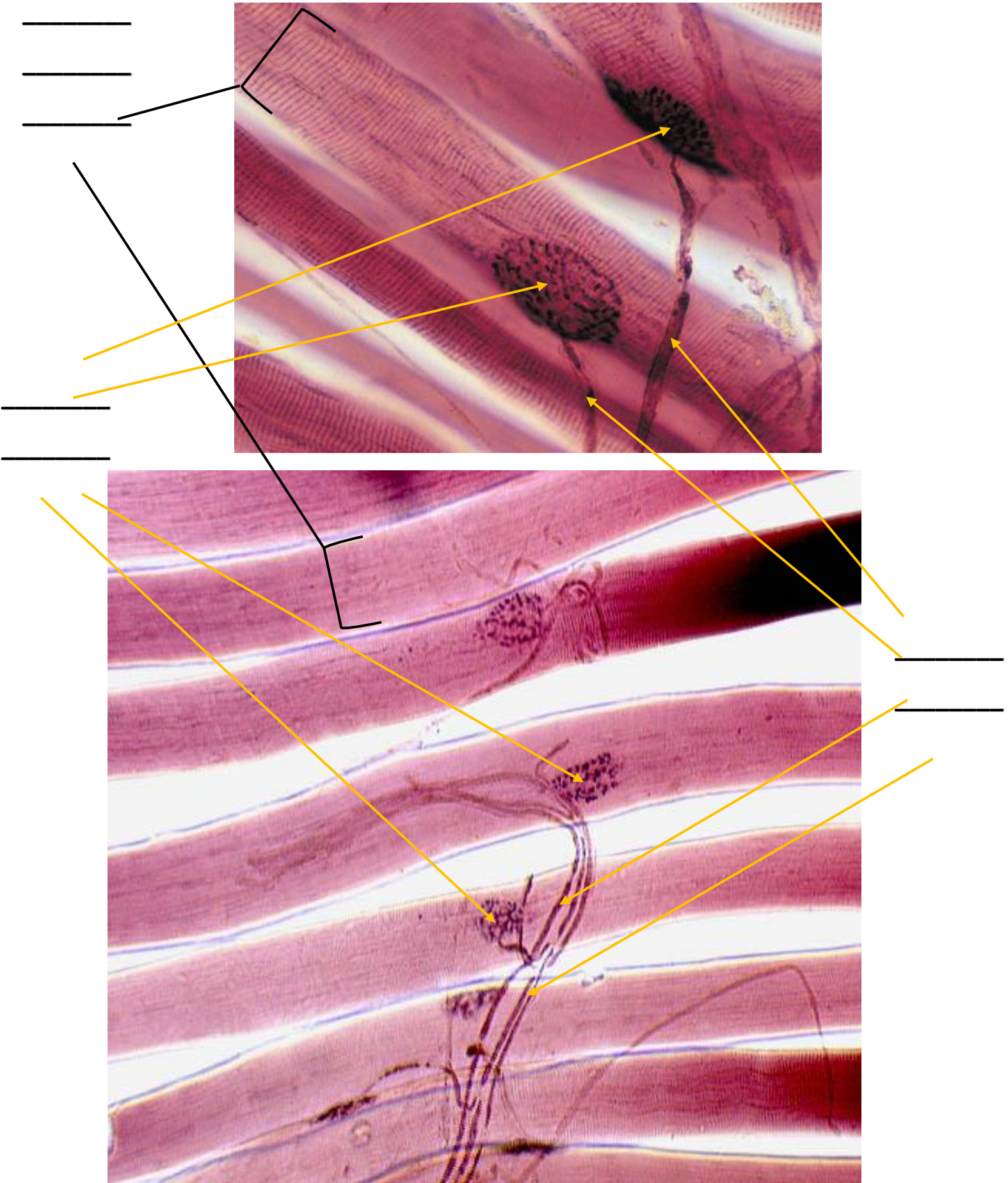


Motor  
End  
Plate



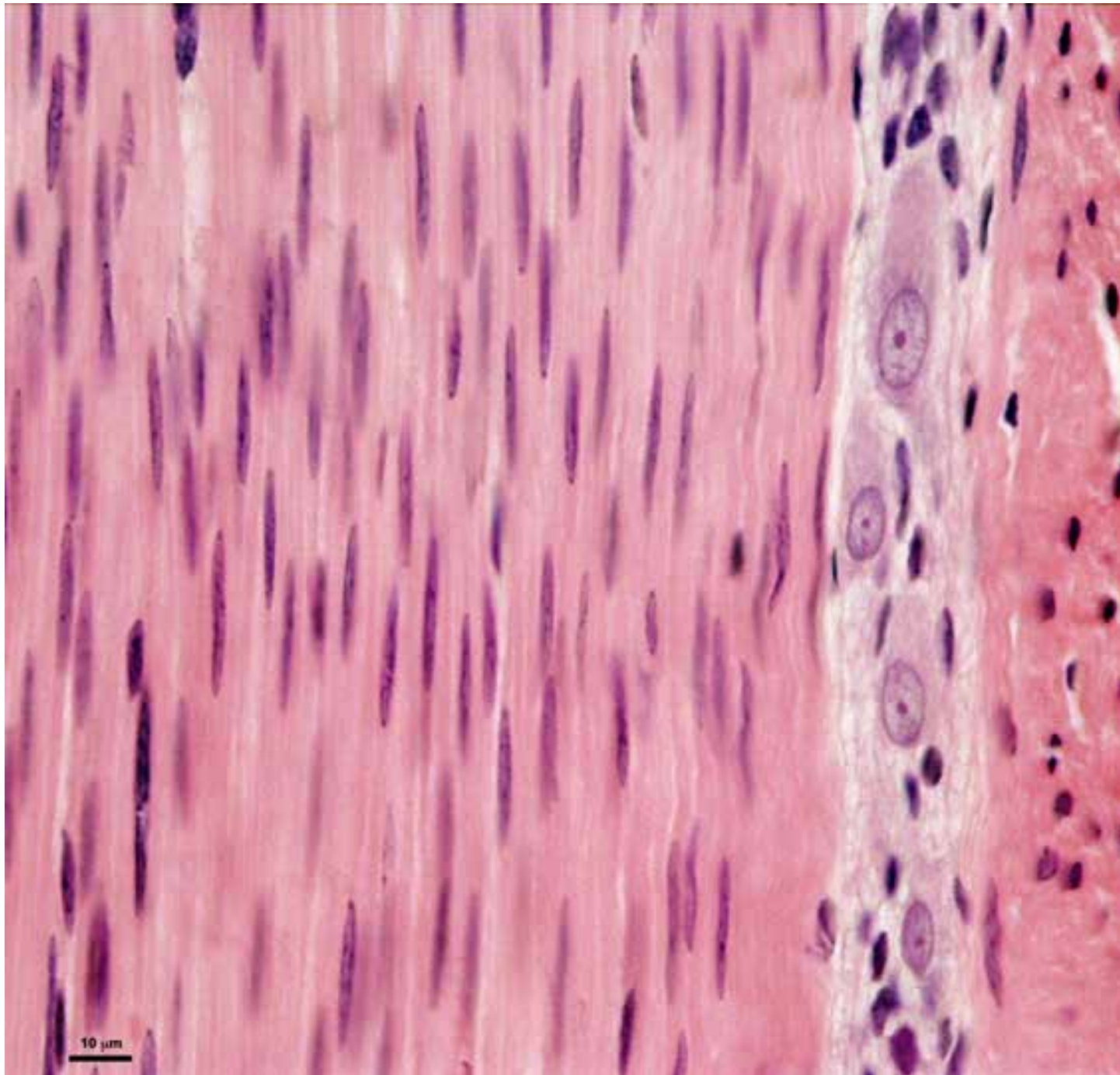
Motor  
Nerve  
Fibers

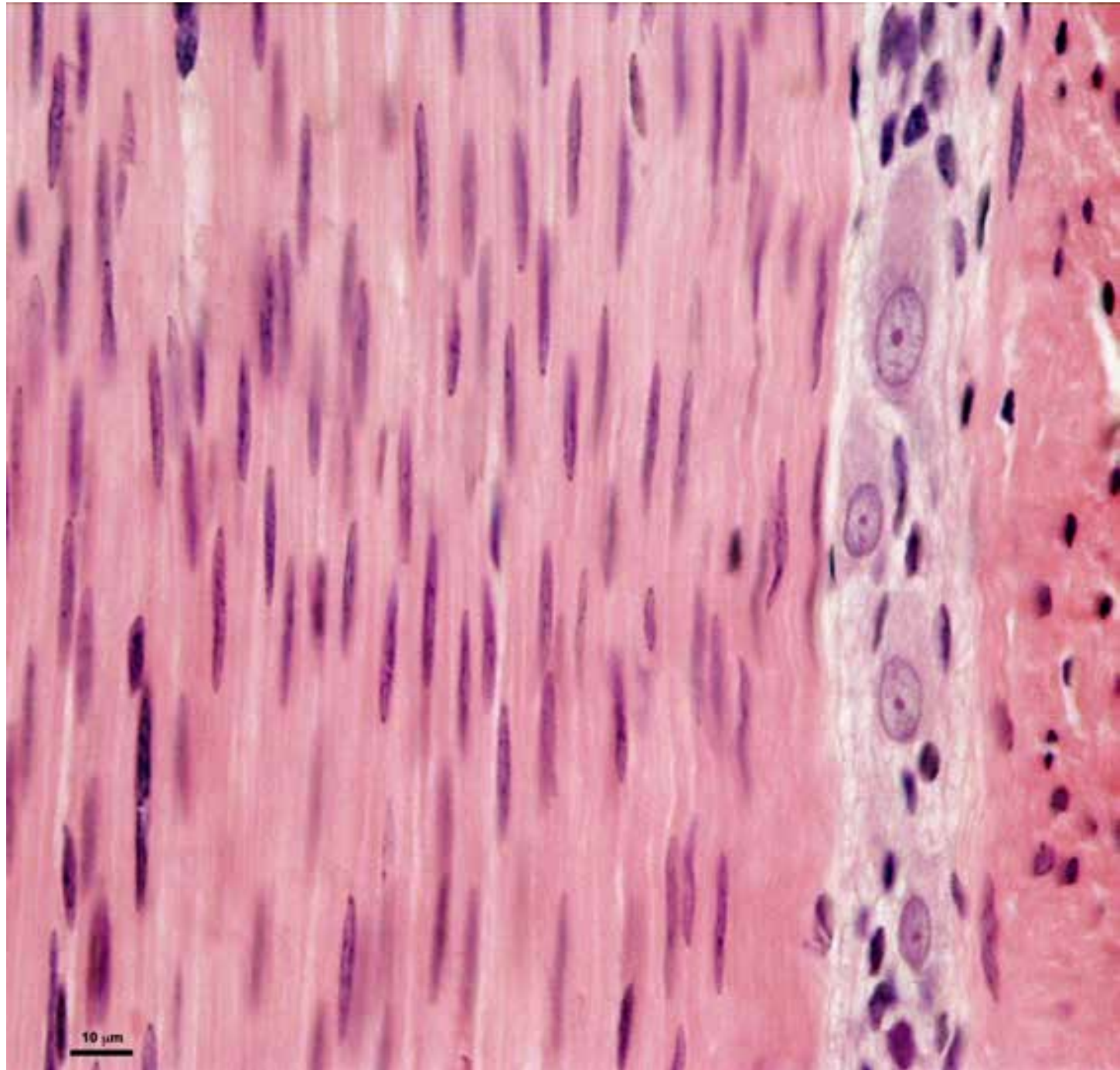
# MOTOR END PLATE SLIDES



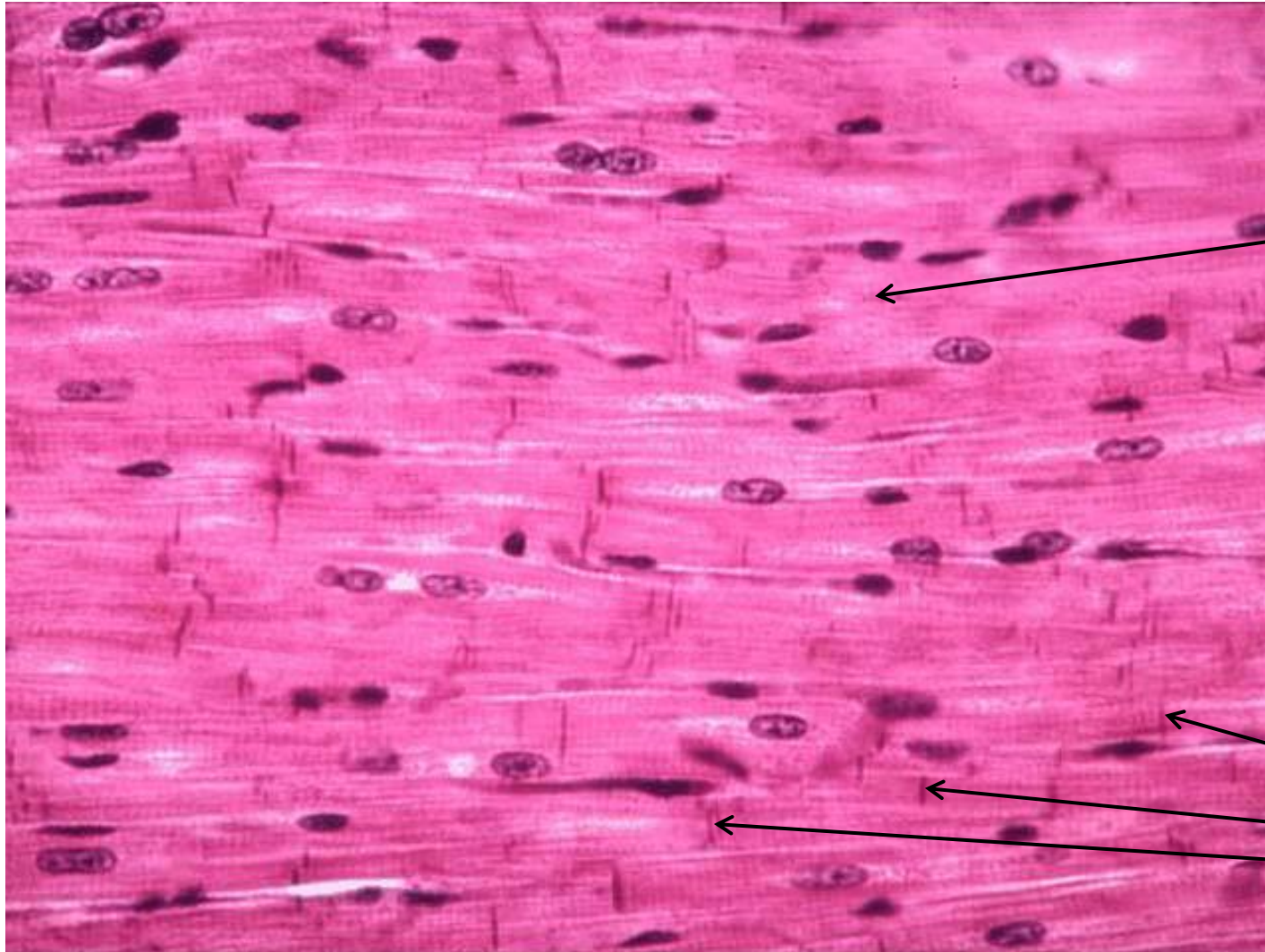


# SMOOTH MUSCLE SLIDE





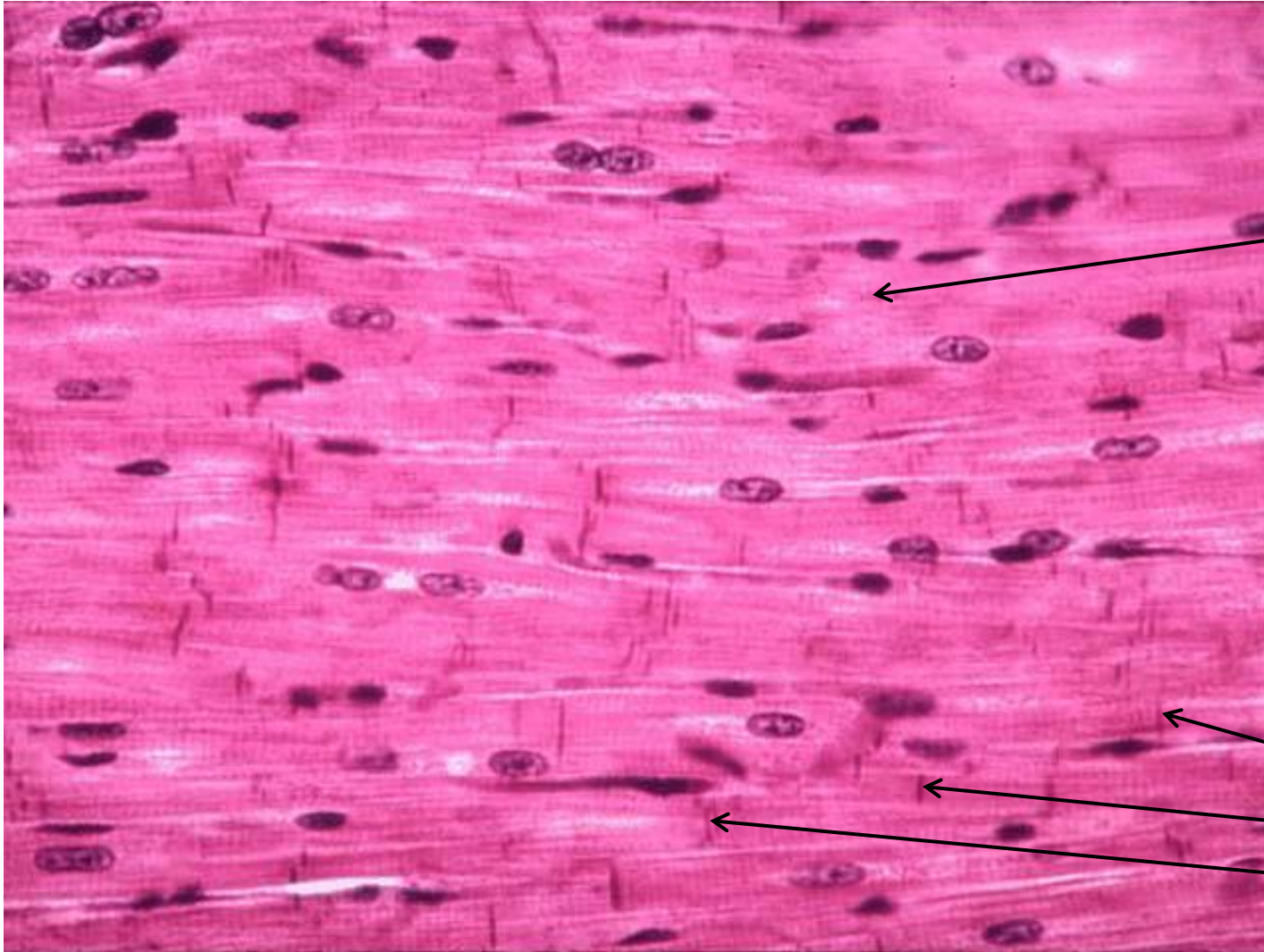
# CARDIAC MUSCLE SLIDE



Striations  
(alternating dark & light  
lines) (difficult to see)

Intercalated  
Disks

# CARDIAC MUSCLE SLIDE



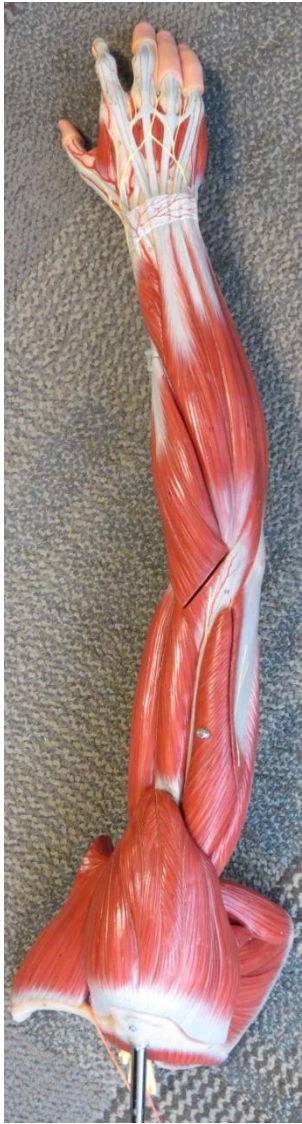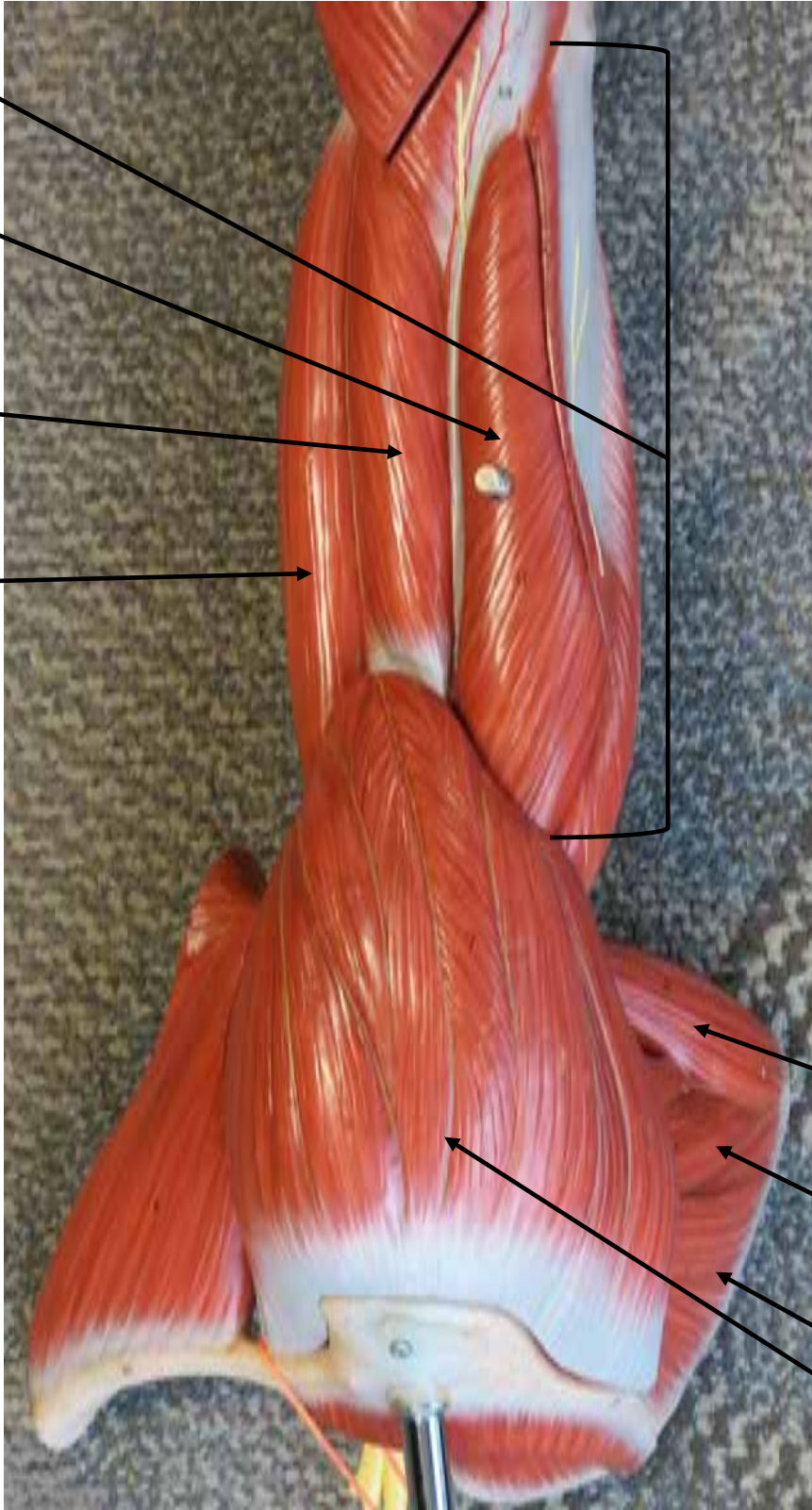
# ARM MODEL

Triceps  
Brachii

Lateral Head  
(of triceps brachii)

Brachialis

Biceps  
Brachii



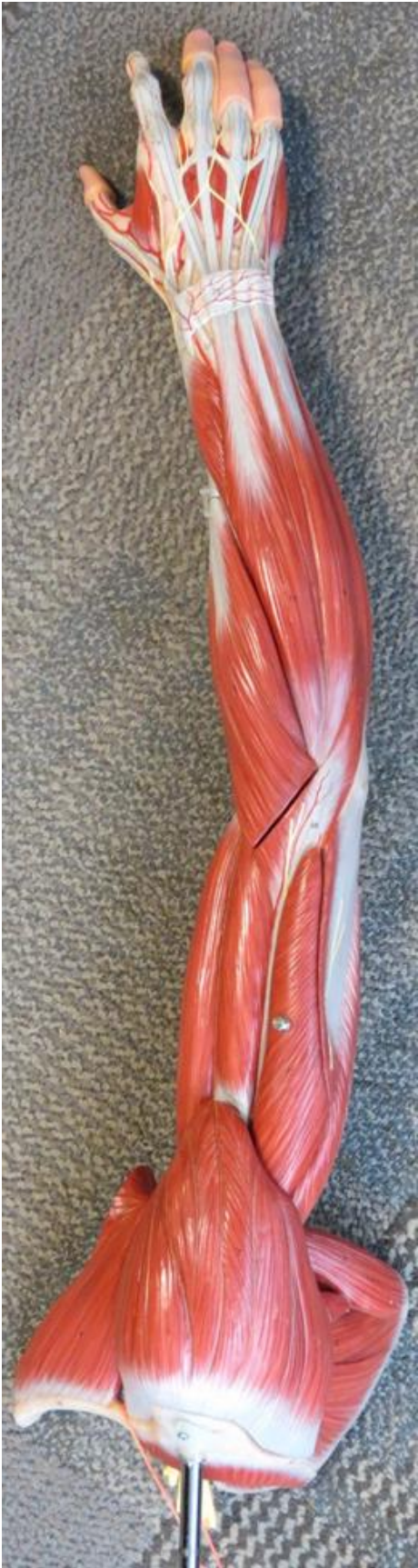Teres  
Major

Teres  
Minor

Infraspinatus

Deltoid

# ARM MODEL



Extensor Digitorum

Brachioradialis

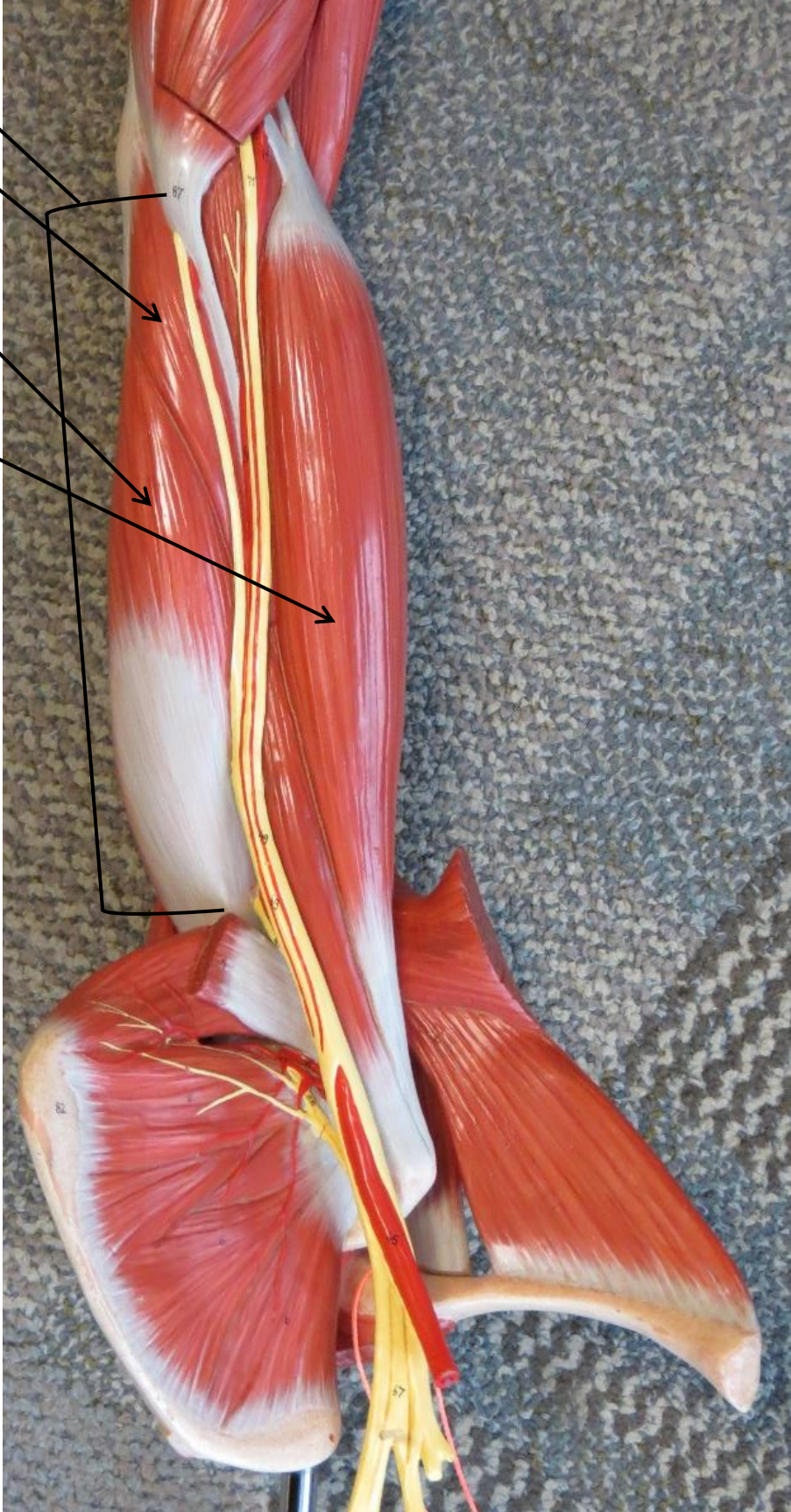
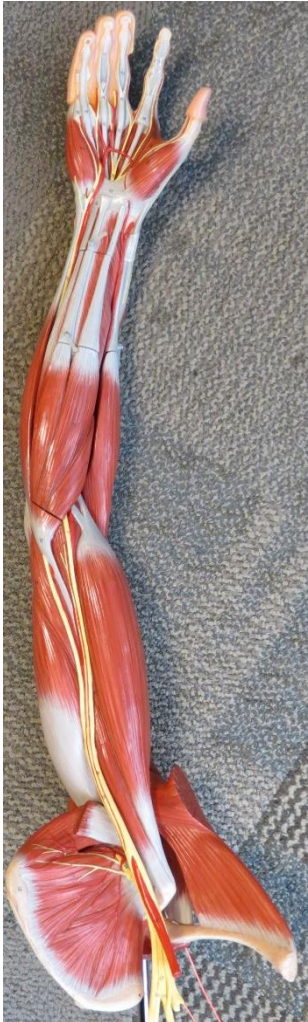# ARM MODEL

Triceps  
Brachii

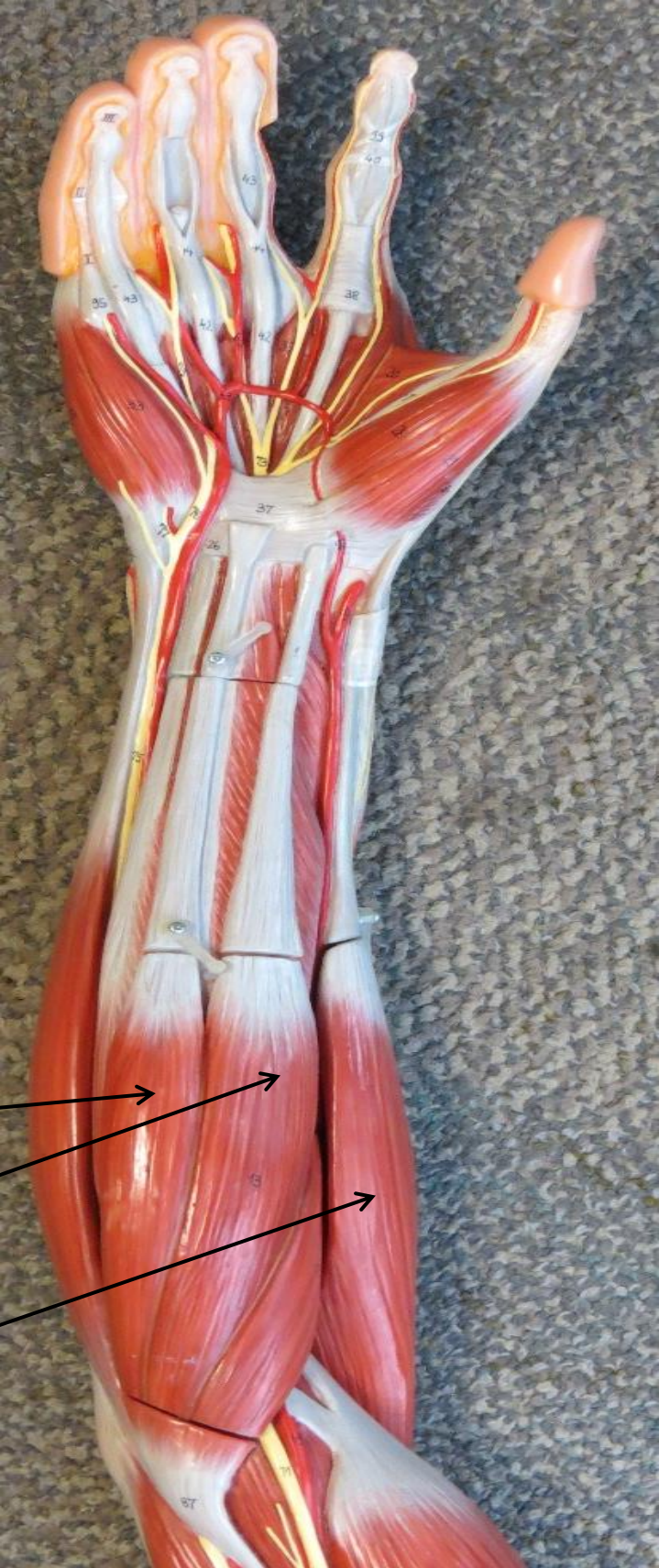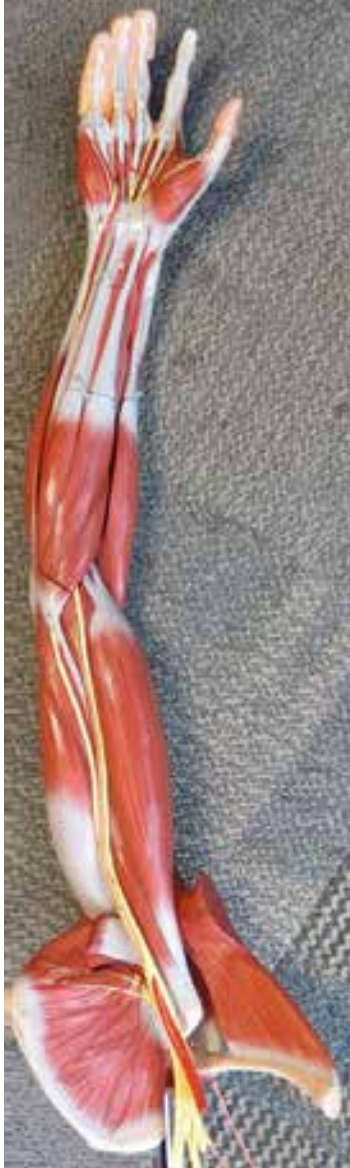Medial Head  
(of triceps brachii)

Long Head  
(of triceps brachii)

Biceps  
Brachii



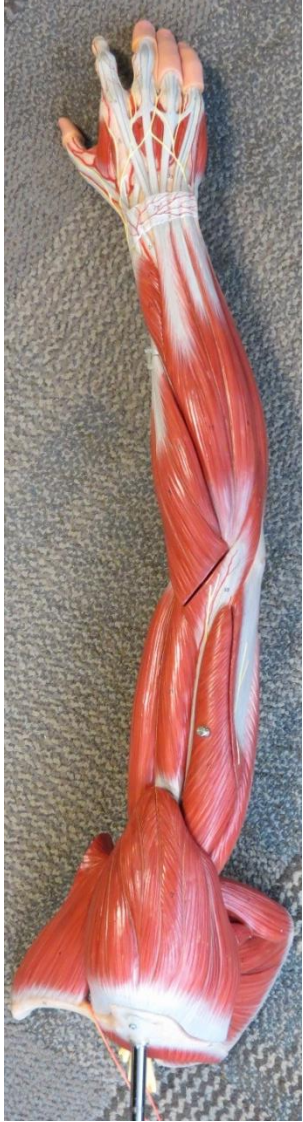
# ARM MODEL



- Palmaris Longus
- Flexor Carpi Radialis
- Brachioradialis



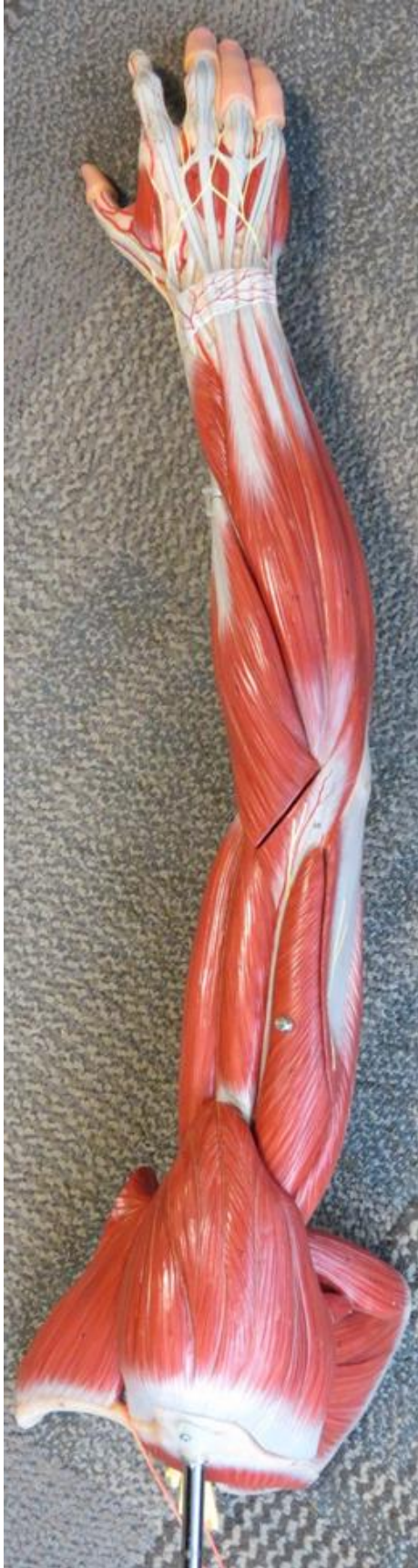# ARM MODEL



- 
- 
- 
- 
- 
- 
- 

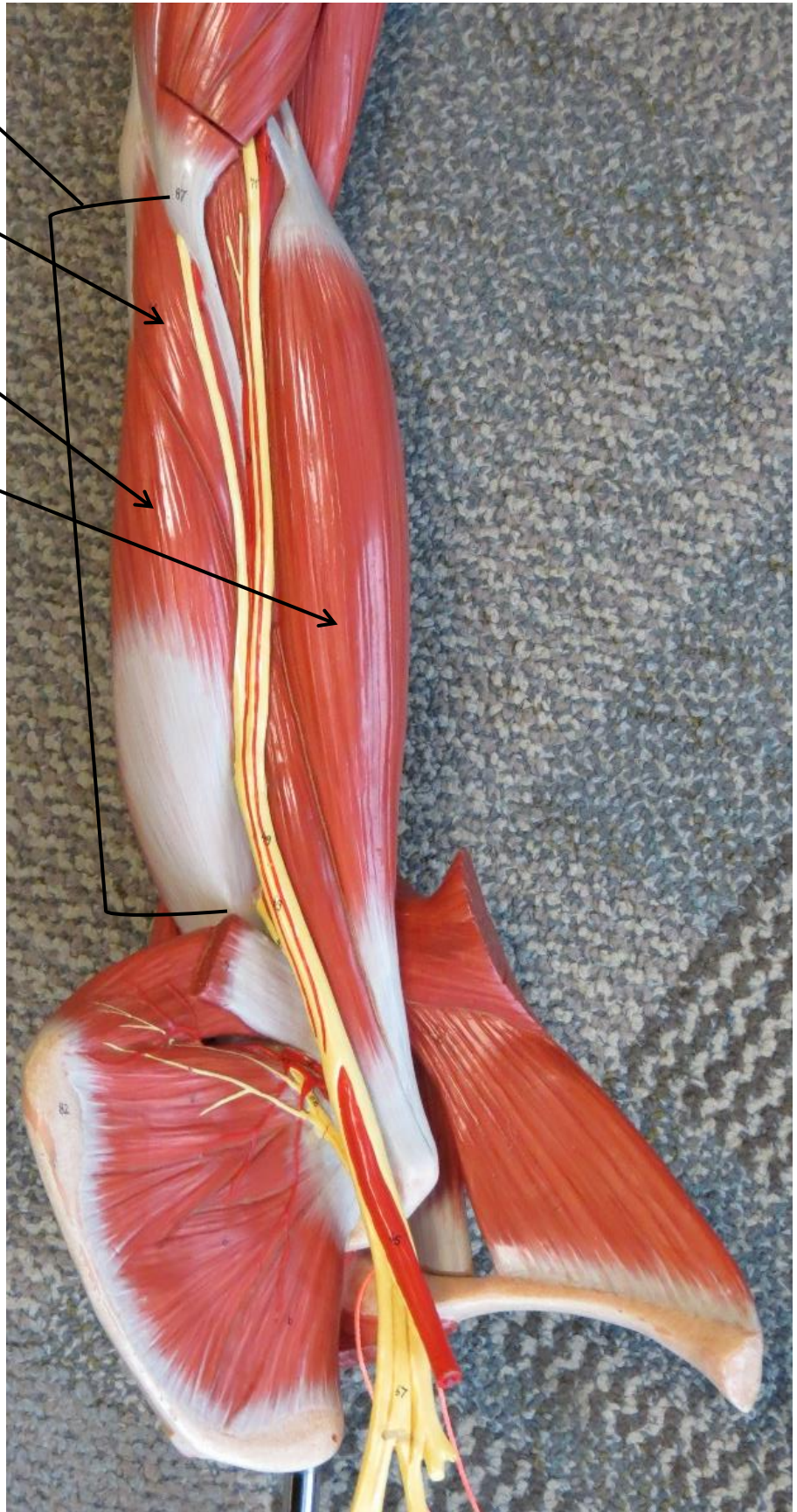
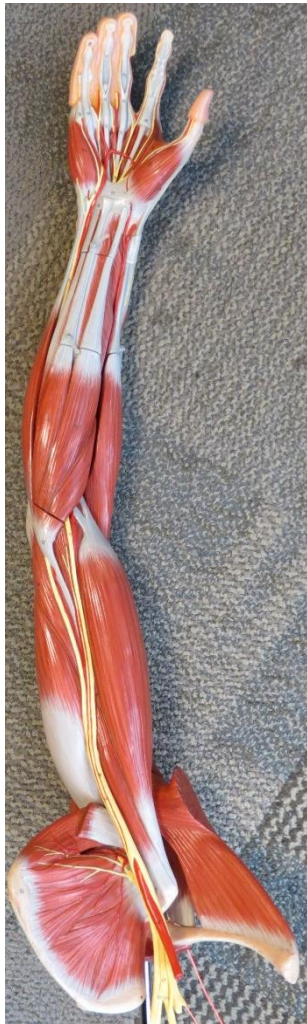- 
- 
- 
- 
- 
-

# ARM MODEL

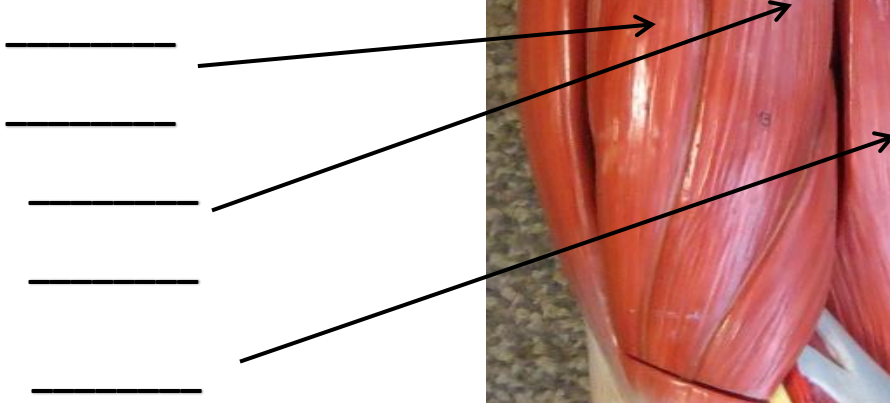
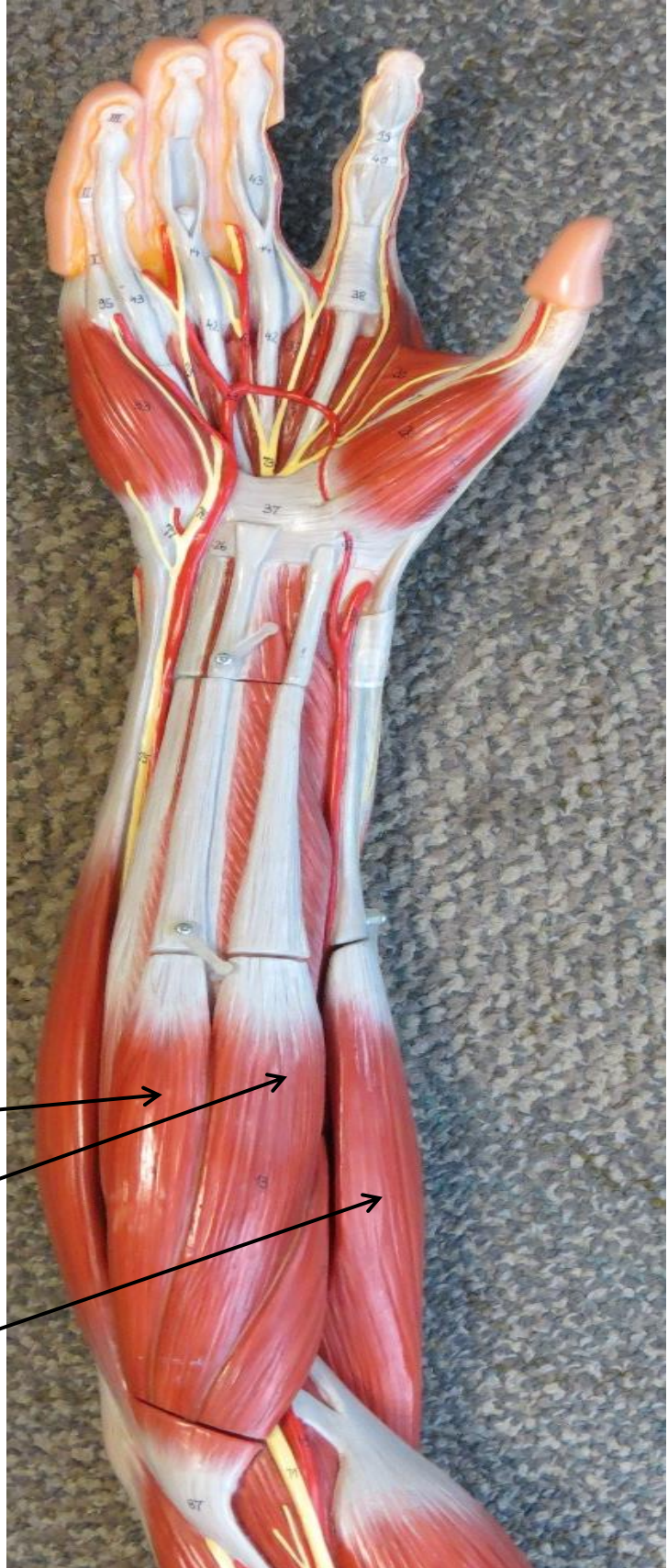
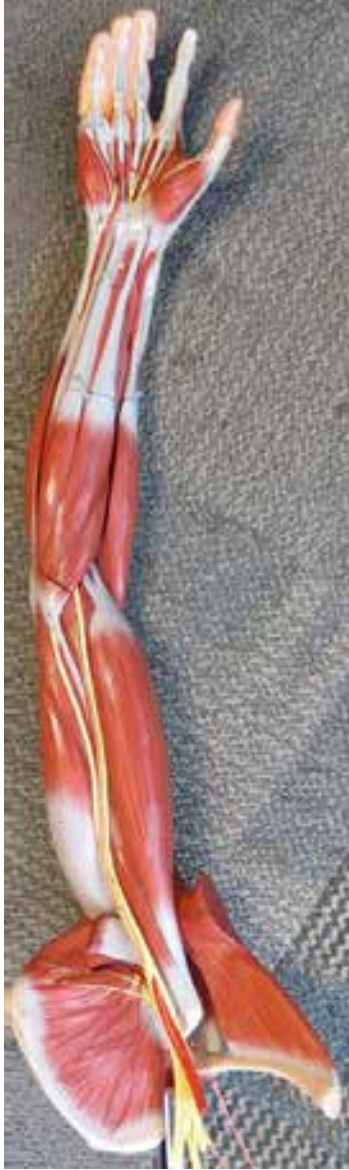
# ARM MODEL

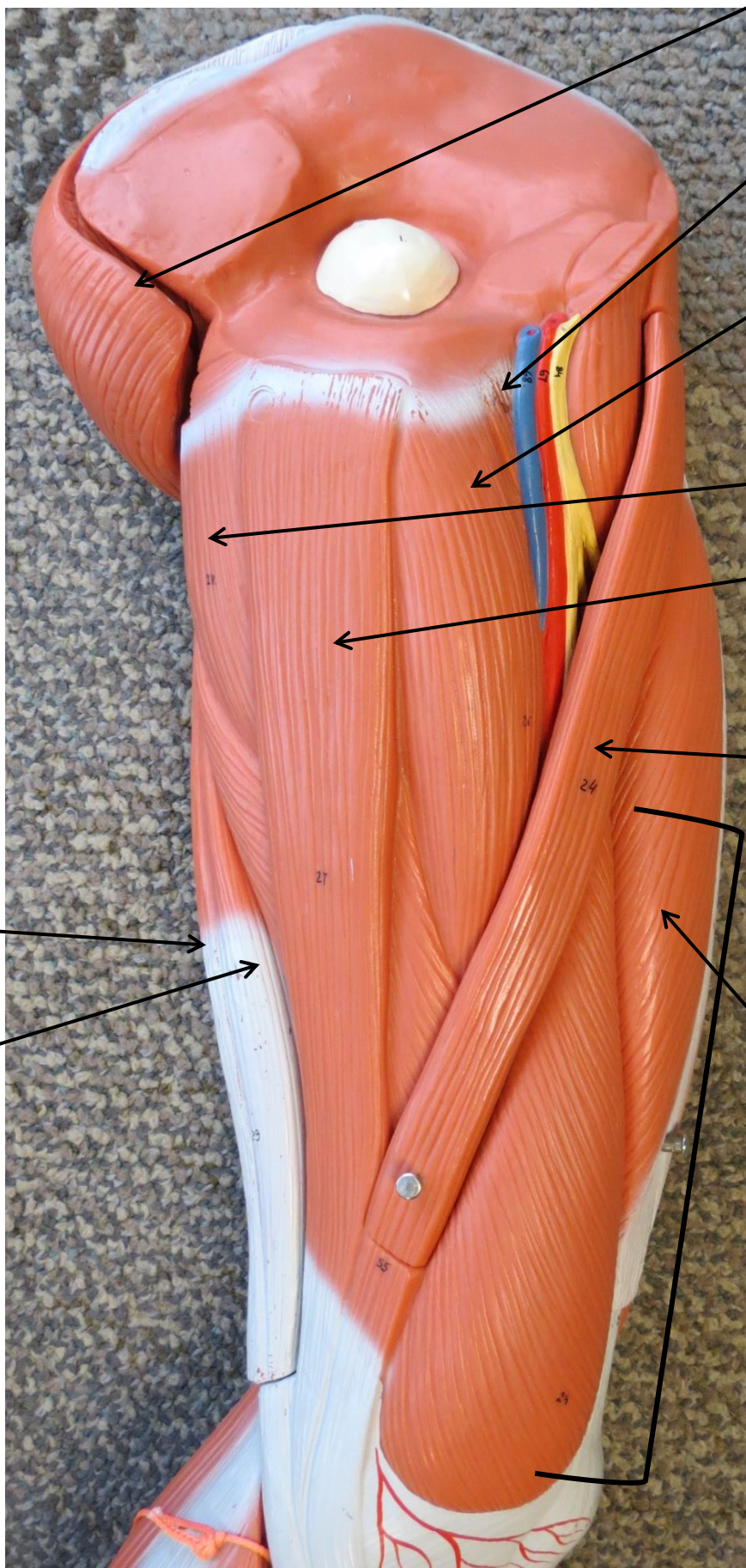

- \_\_\_\_\_
- \_\_\_\_\_
- \_\_\_\_\_
- \_\_\_\_\_
- \_\_\_\_\_
- \_\_\_\_\_
- \_\_\_\_\_
- \_\_\_\_\_



# ARM MODEL



# LEG MUSCLE MODEL



Gluteus Maximus

Pectineus

Adductor Longus

Adductor Magnus

Gracilis

Sartorius

Rectus Femoris

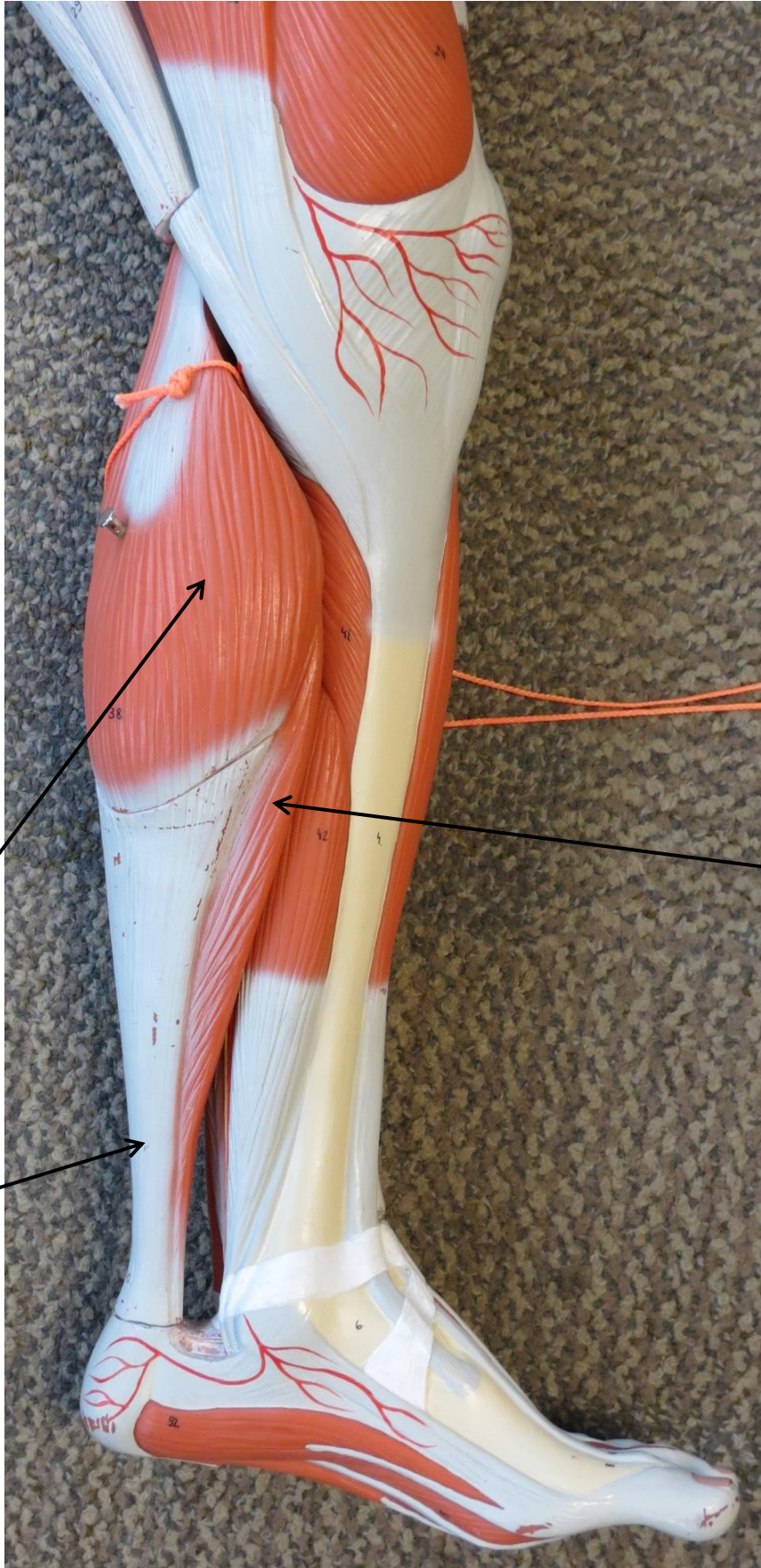
Vastus Medialis

Quadriceps Femoris

Semitendinosus

Semimembranosus

# LEG MUSCLE MODEL



Gastrocnemius

Tendon of  
Gastrocnemius

Soleus

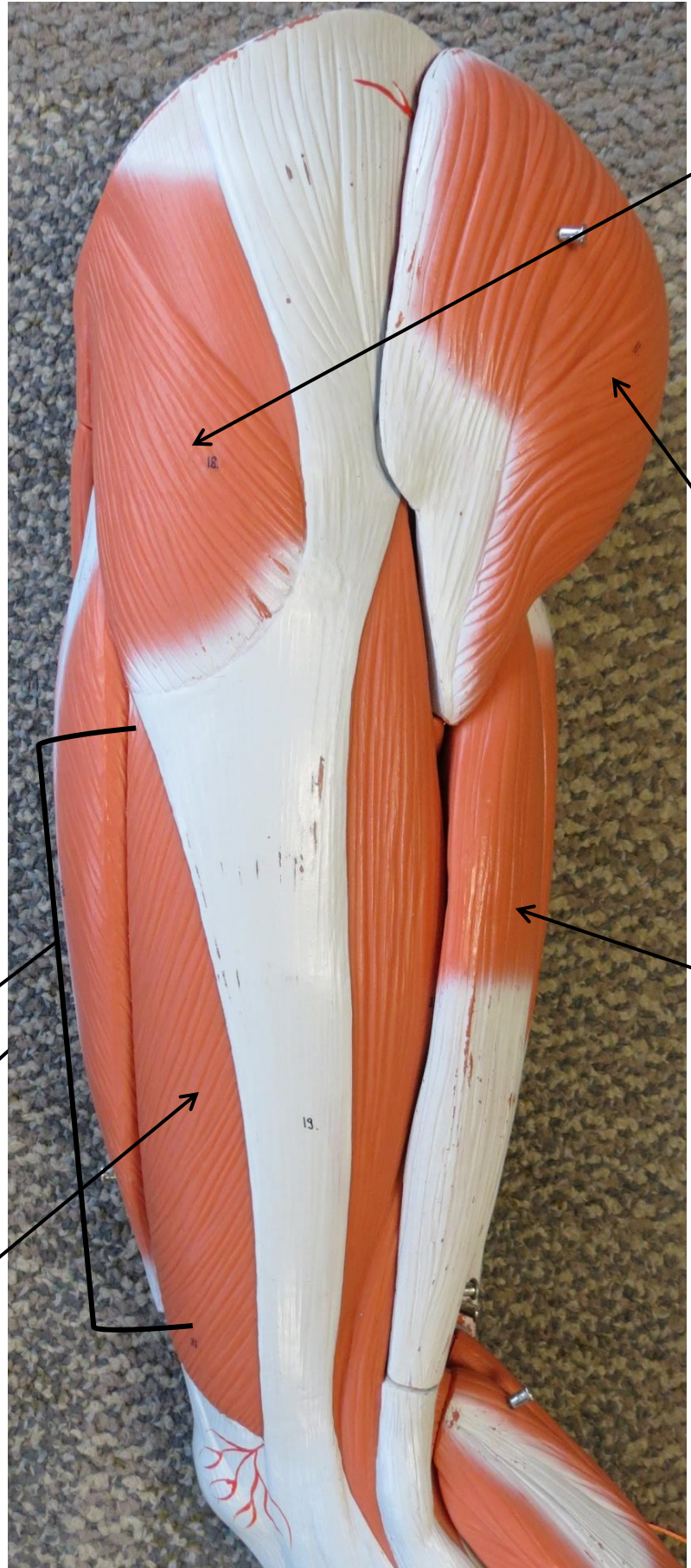
# LEG MUSCLE MODEL



Quadriceps  
Femoris

Rectus  
Femoris

Vastus  
Lateralis

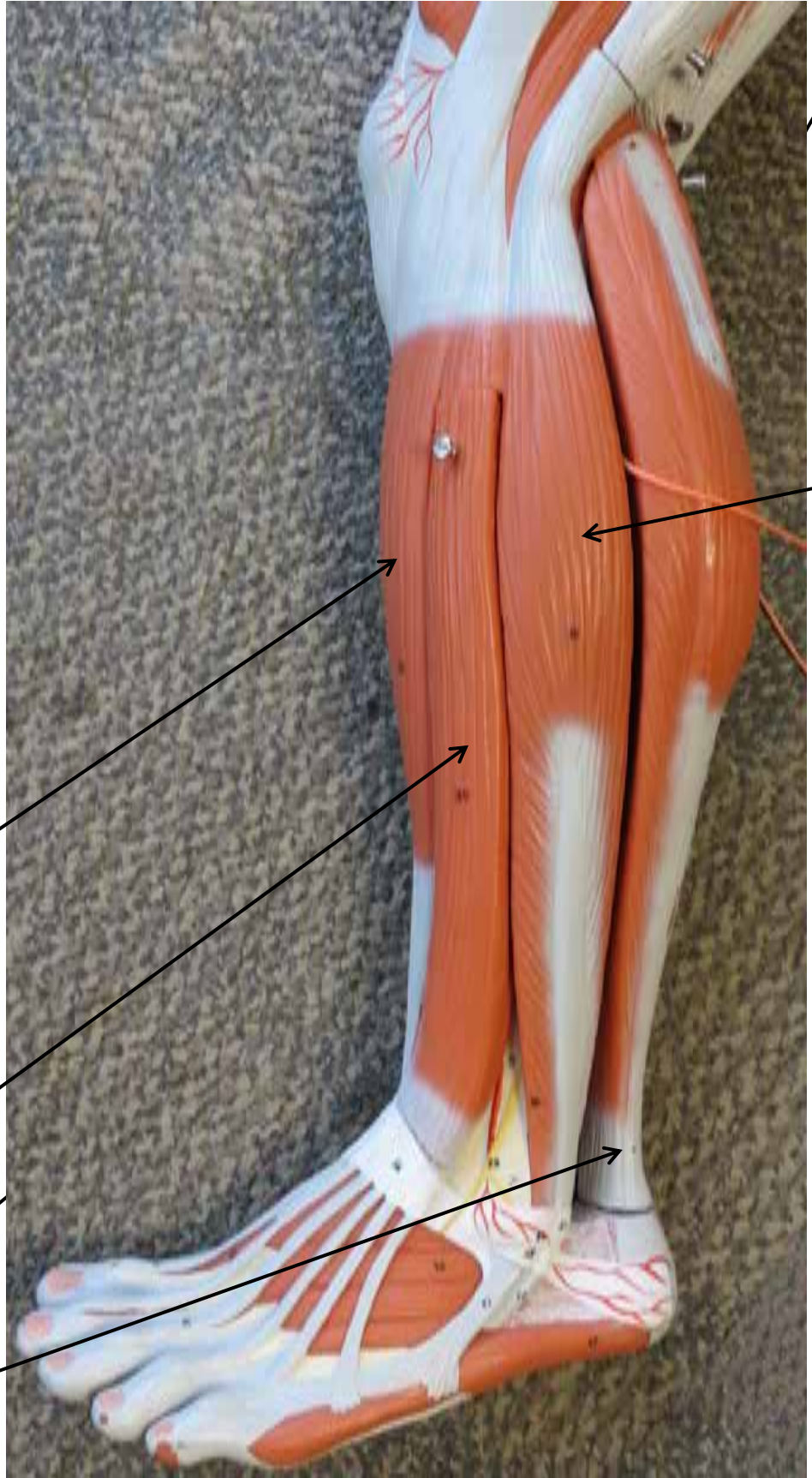


Tensor  
Fasciae  
Latae

Gluteus  
Maximus

Biceps  
Femoris

# LEG MUSCLE MODEL



Soleus

Fibularis Longus

Tibialis Anterior

Extensor Digitorum Longus

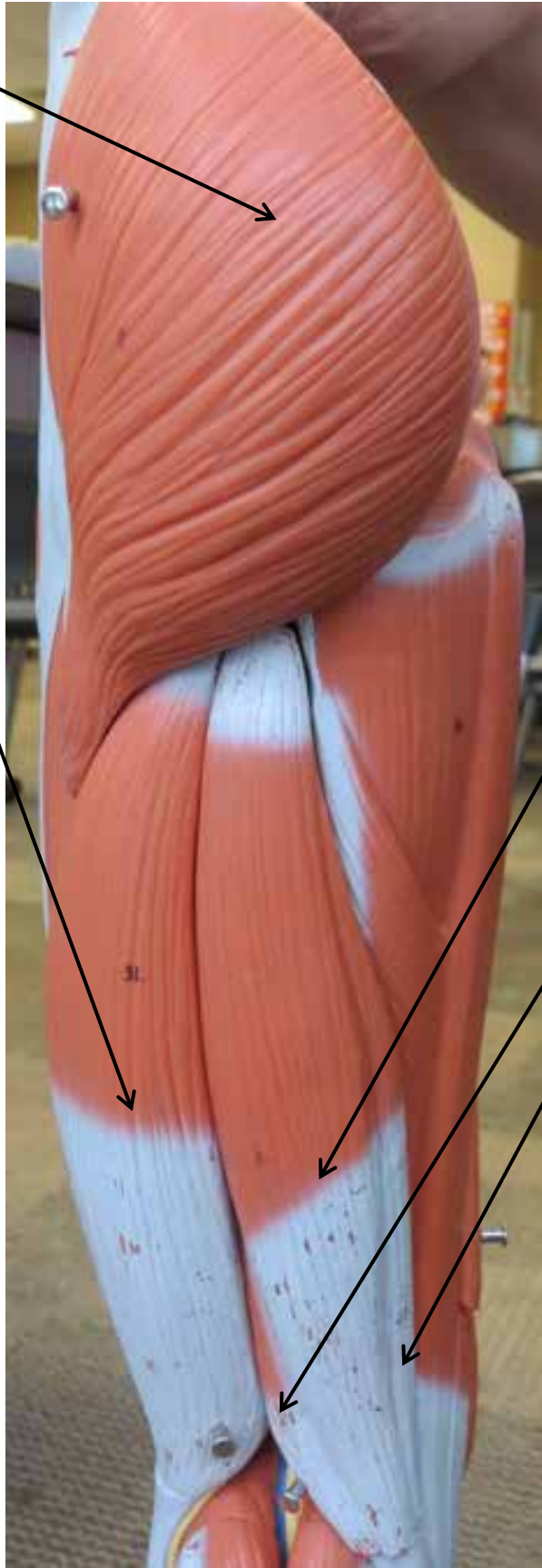
Gastrocnemius

Tendon of Gastrocnemius



# LEG MUSCLE MODEL


Gluteus Maximus



Biceps Femoris

Semitendinosus

Semimembranosus



Gastrocnemius


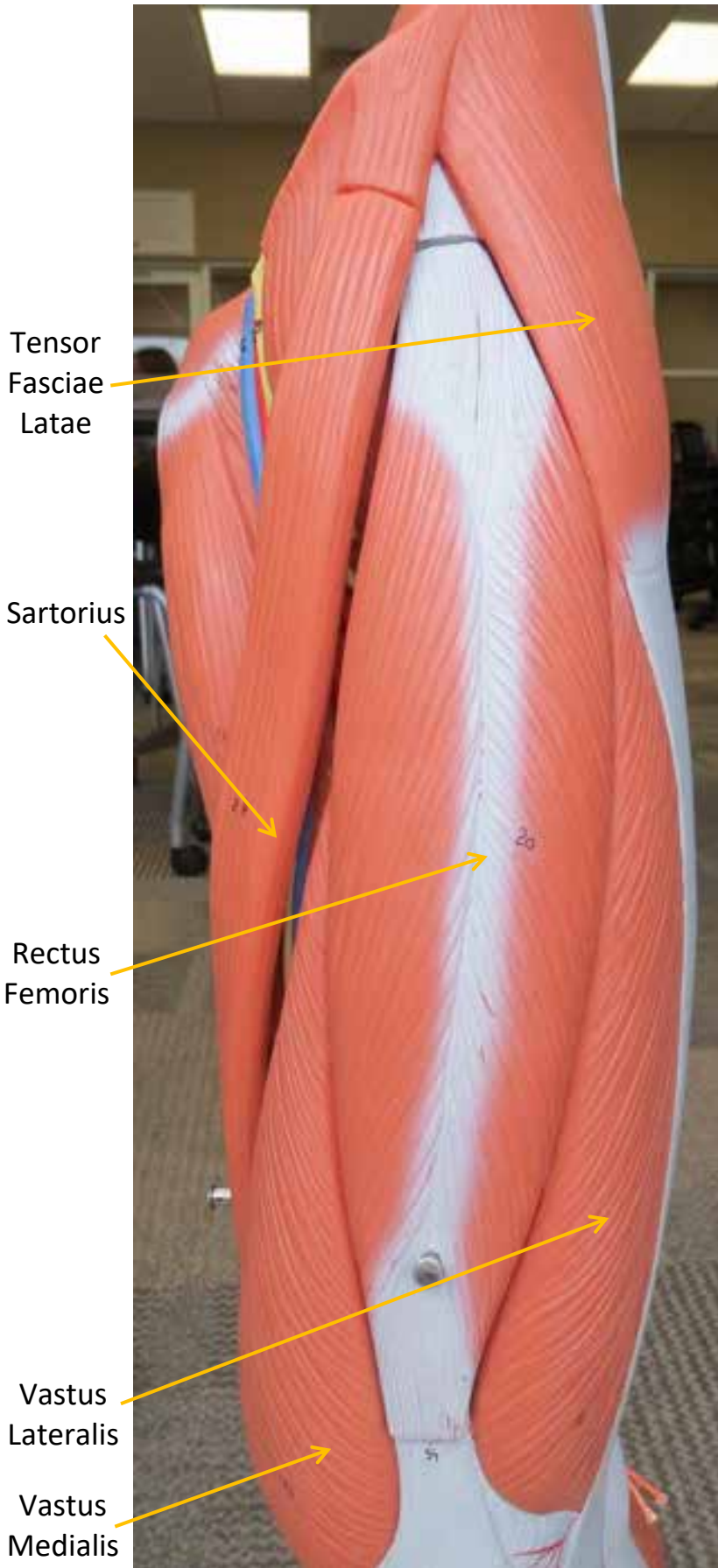
Soleus

Tendon of Gastrocnemius

Hamstrings



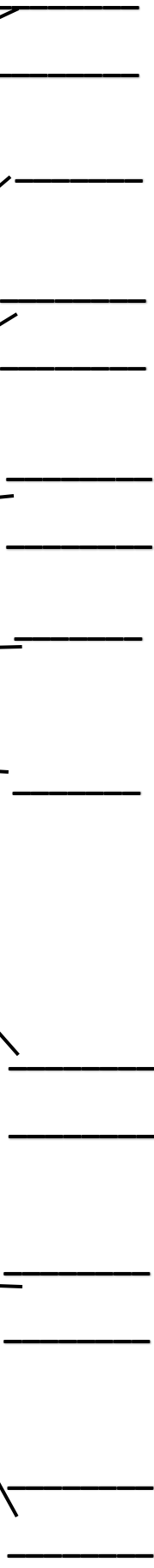
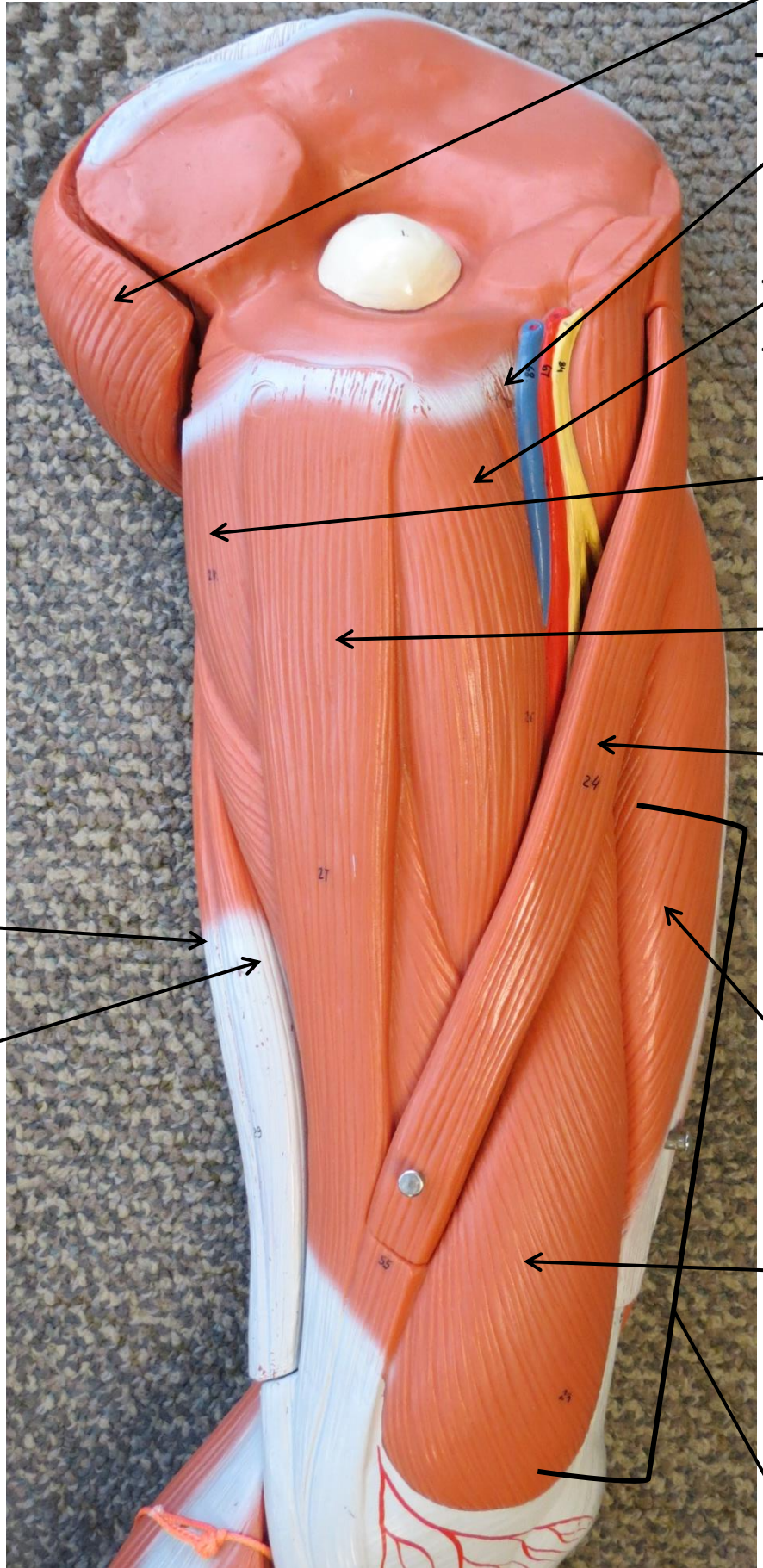
# LEG MUSCLE MODEL



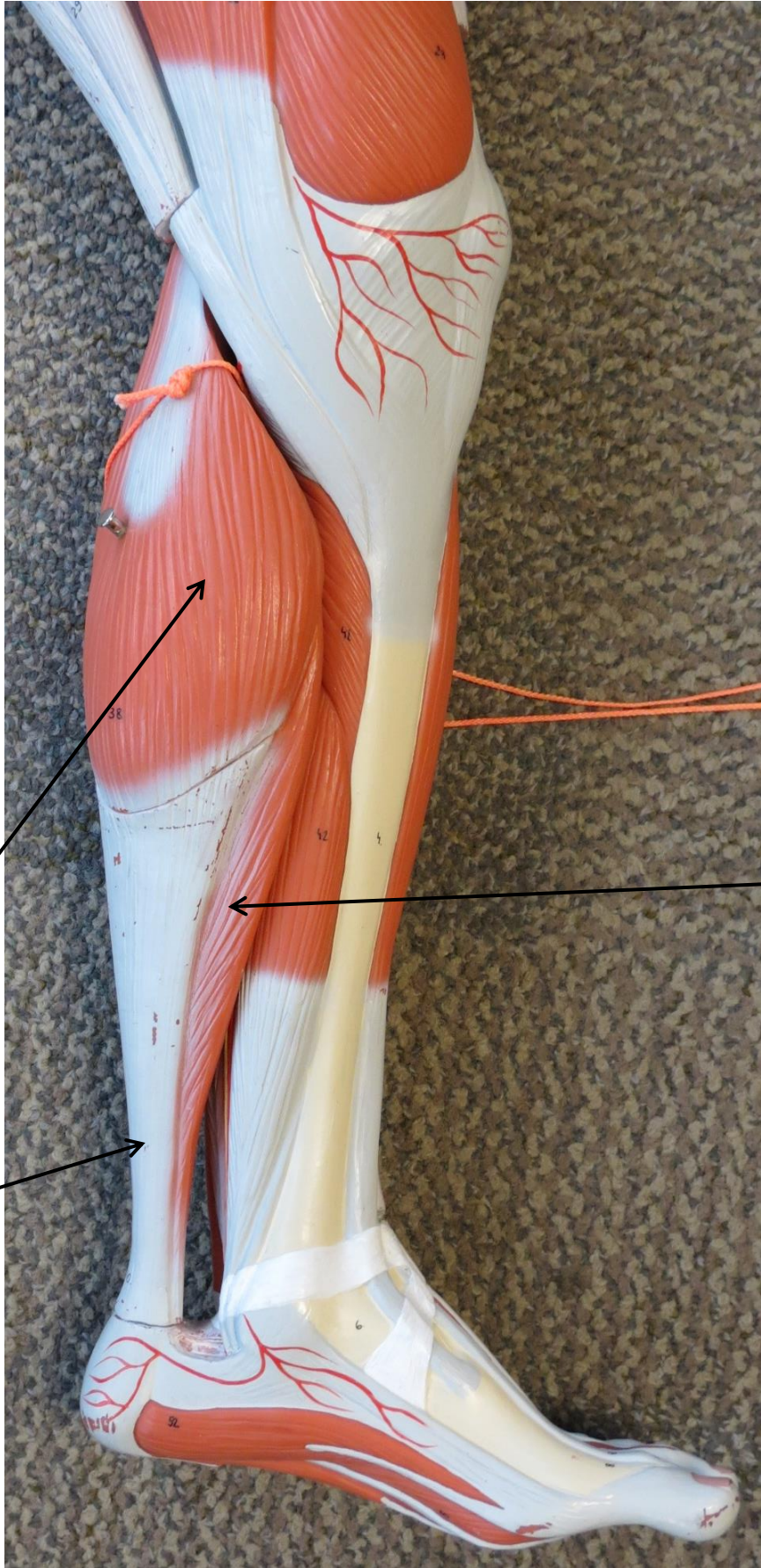
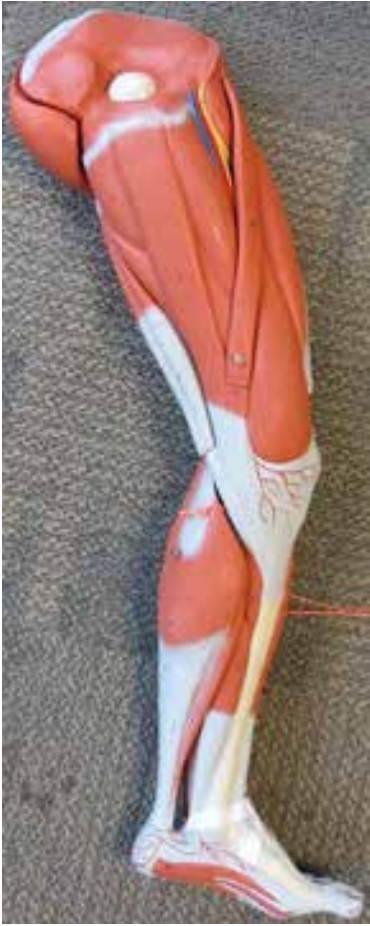Quadriceps Femoris



# LEG MUSCLE MODEL



# LEG MUSCLE MODEL




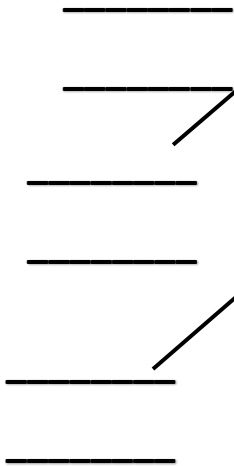
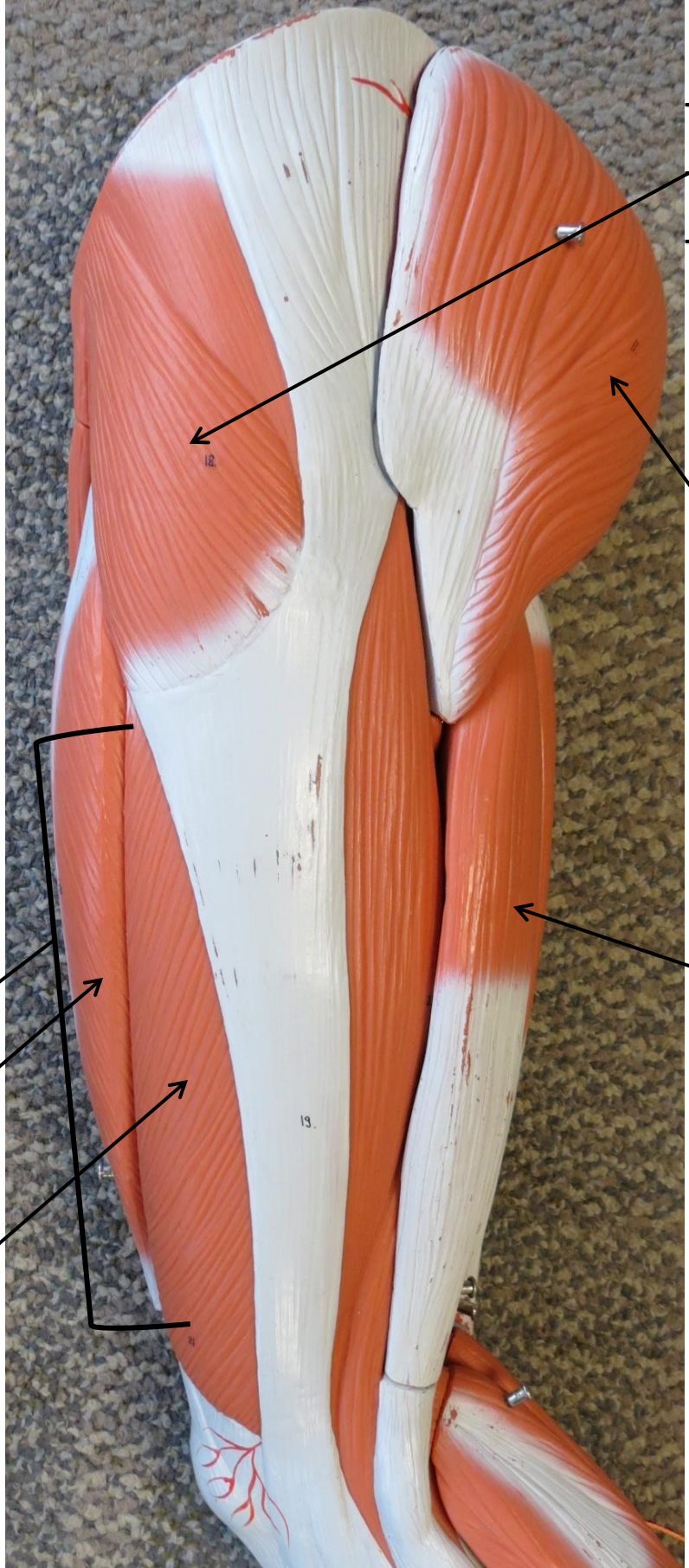
\_\_\_\_\_

\_\_\_\_\_

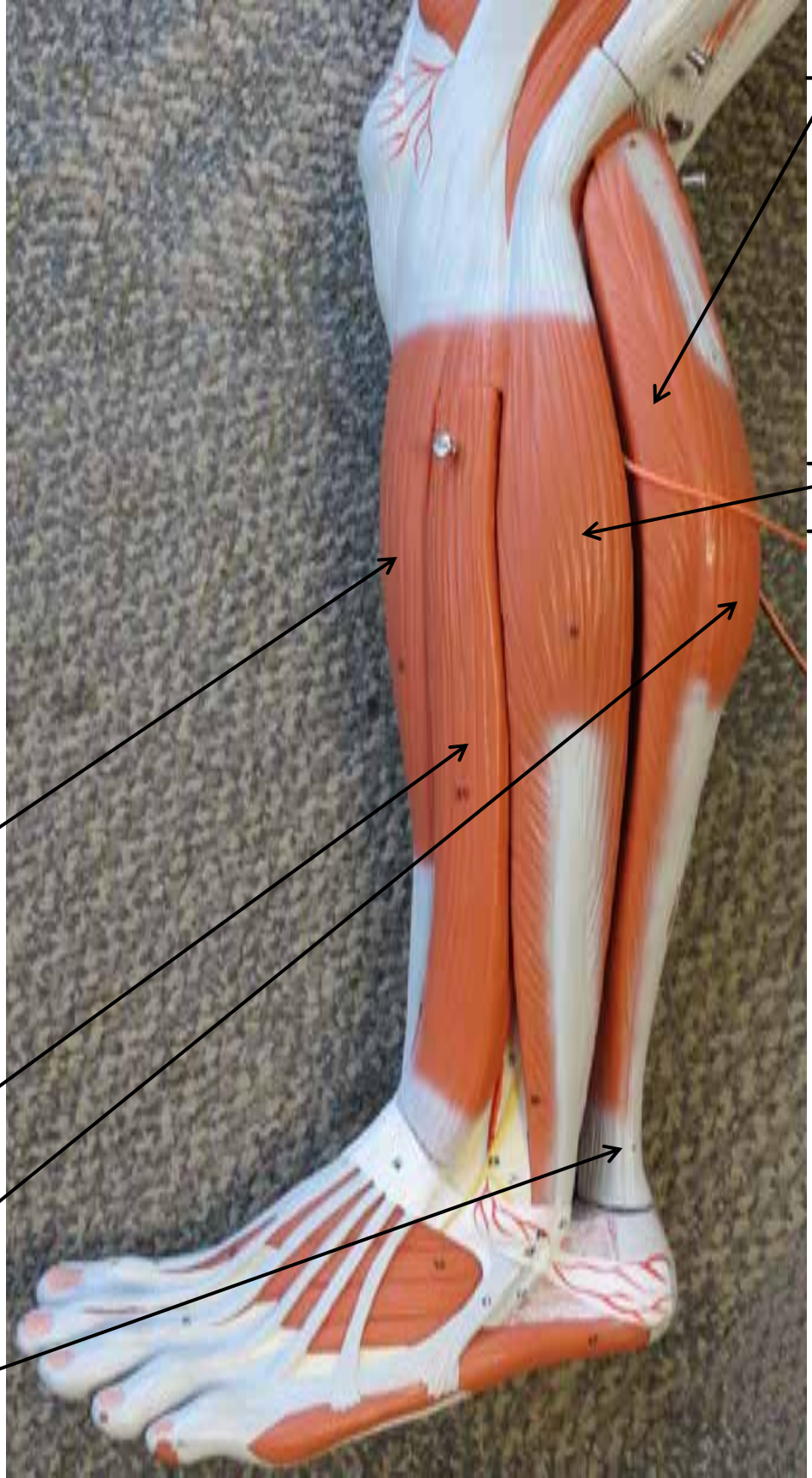
\_\_\_\_\_

\_\_\_\_\_

# LEG MUSCLE MODEL





# LEG MUSCLE MODEL



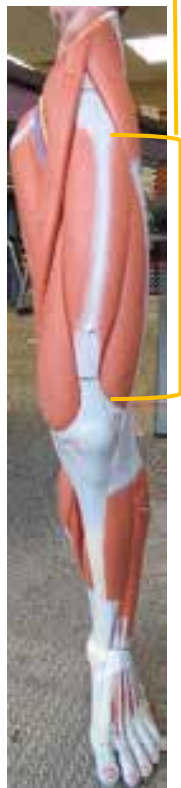

- \_\_\_\_\_
- \_\_\_\_\_
- \_\_\_\_\_
- \_\_\_\_\_
- \_\_\_\_\_
- \_\_\_\_\_
- \_\_\_\_\_

- \_\_\_\_\_
- \_\_\_\_\_
- \_\_\_\_\_

# LEG MUSCLE MODEL

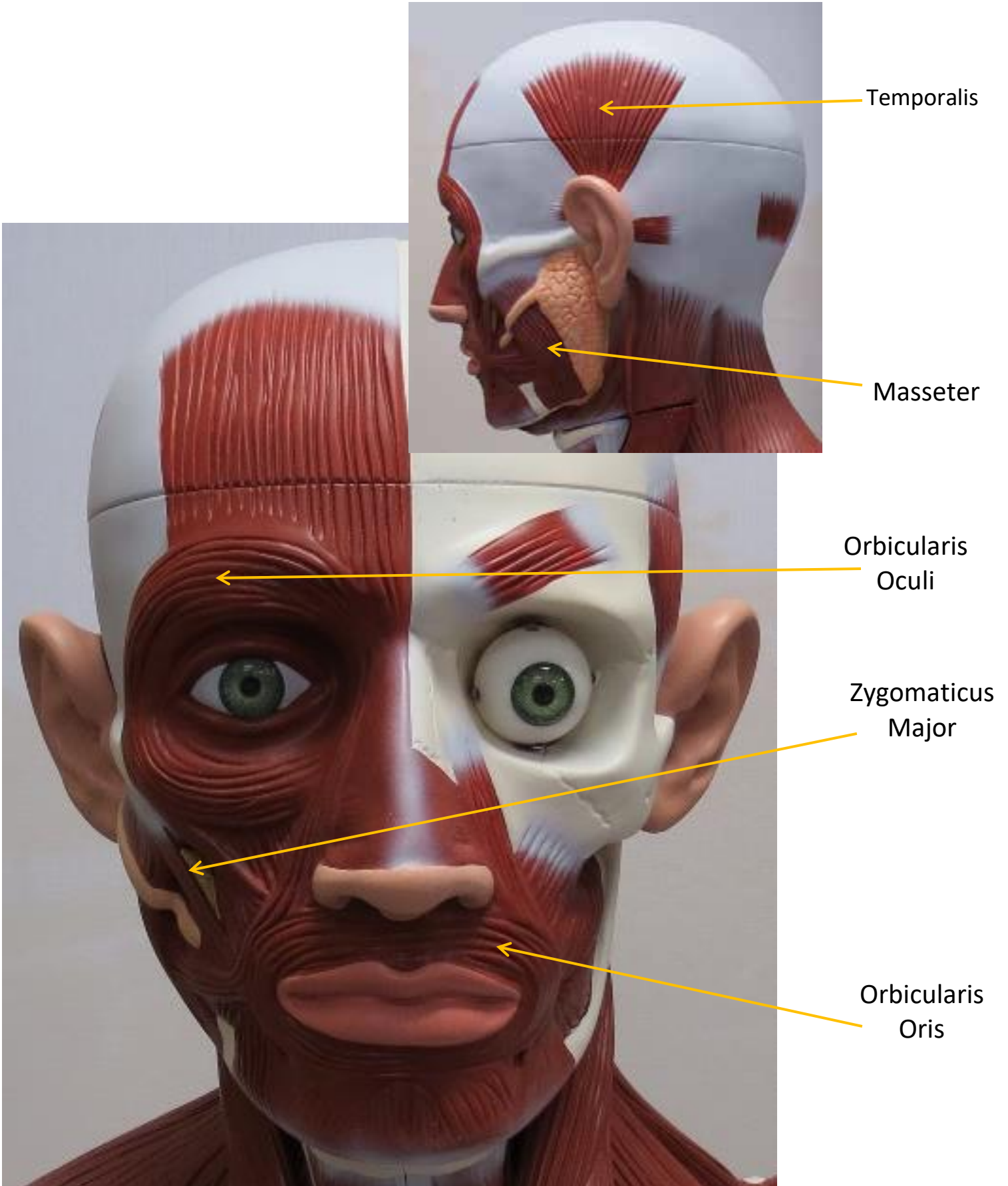


# LEG MUSCLE MODEL



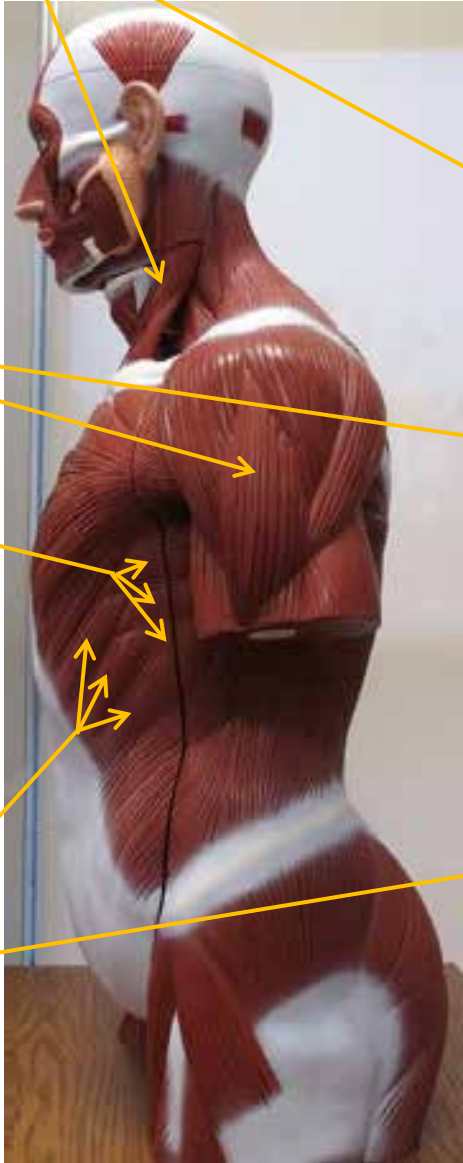


# LARGE MUSCLE MODEL



# LARGE MUSCLE MODEL

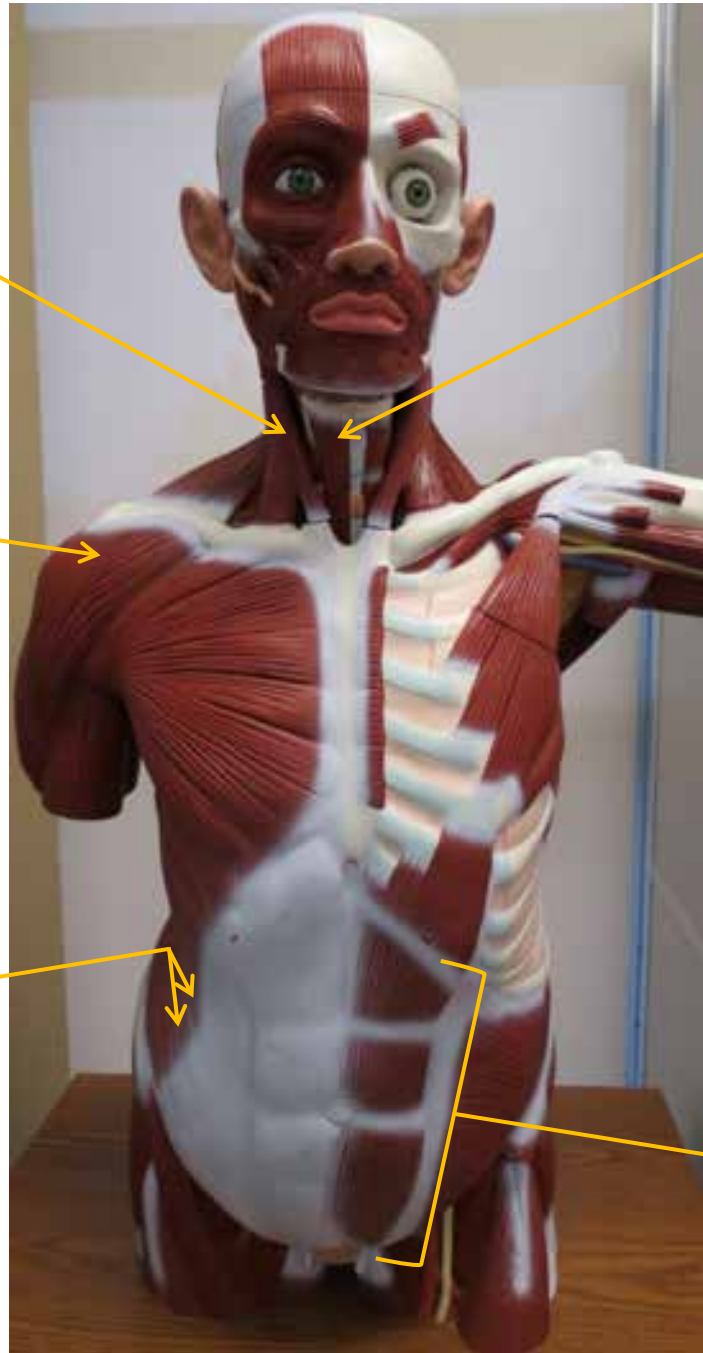
Sternocleid-  
omastoid



Deltoid

Serratus  
Anterior

External  
Obliques



Sternohyoid

Rectus  
Abdominis

# LARGE MUSCLE MODEL

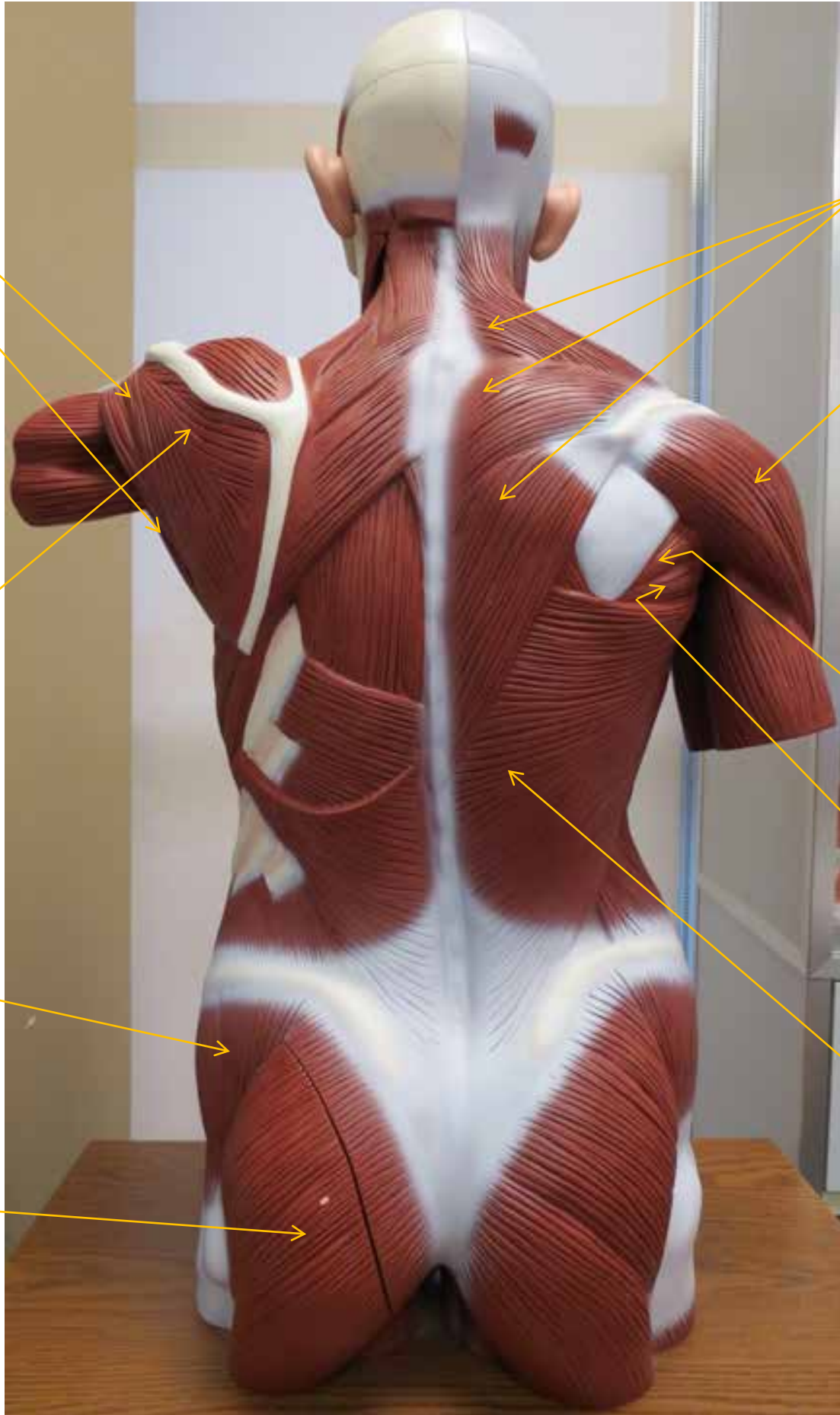
Teres Minor

Teres Major

Infraspinatus

Gluteus  
Medius

Gluteus  
Maximus



Trapezius

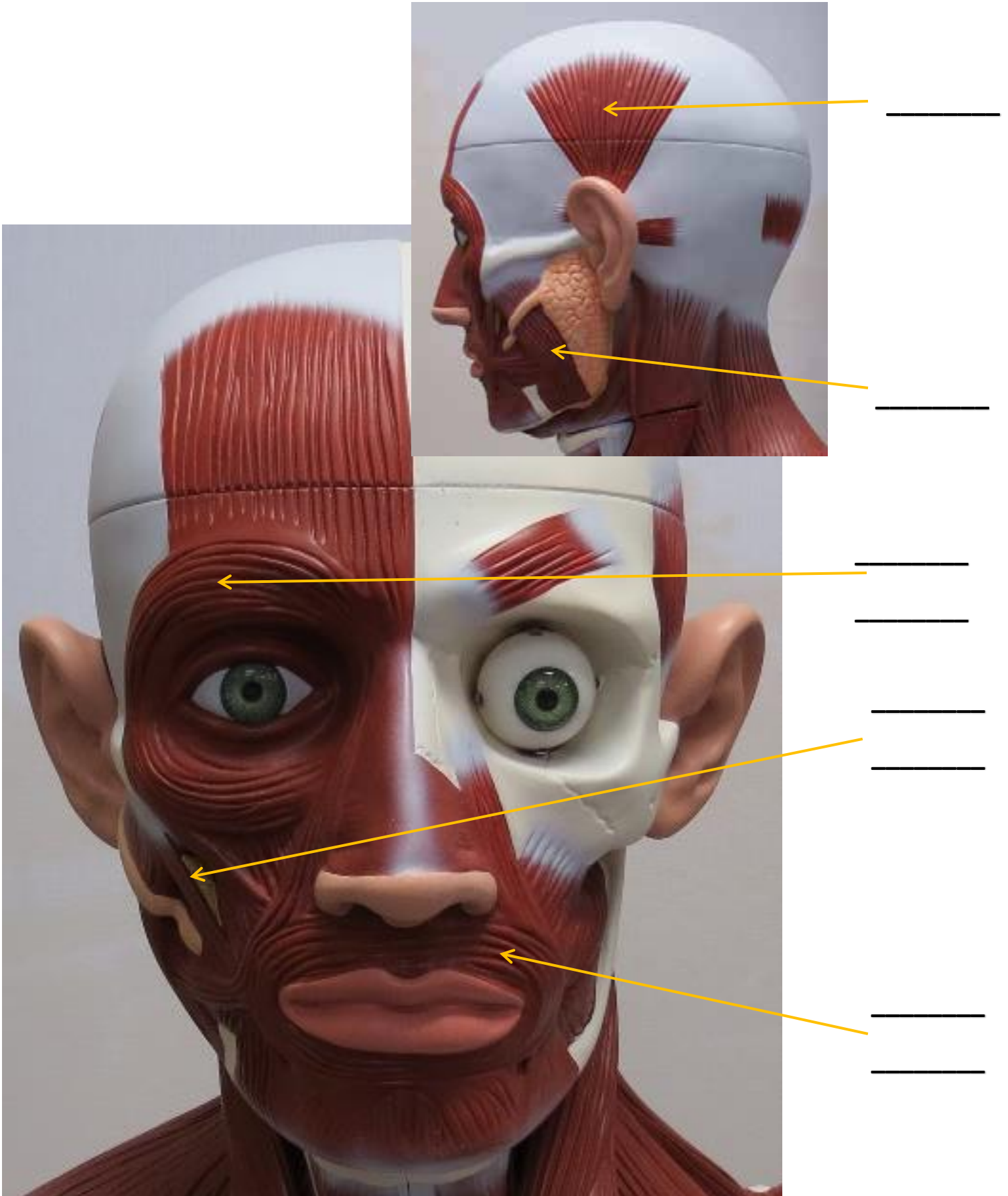
Deltoid

Teres  
Minor

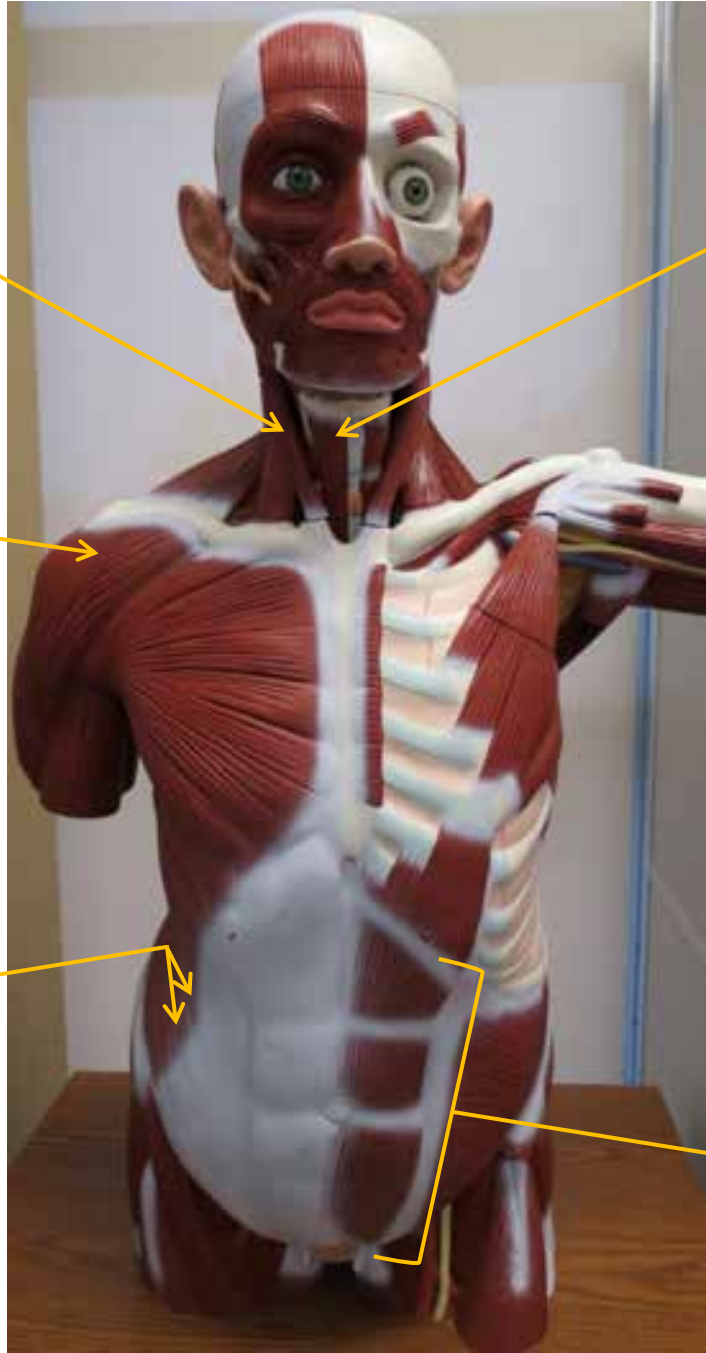
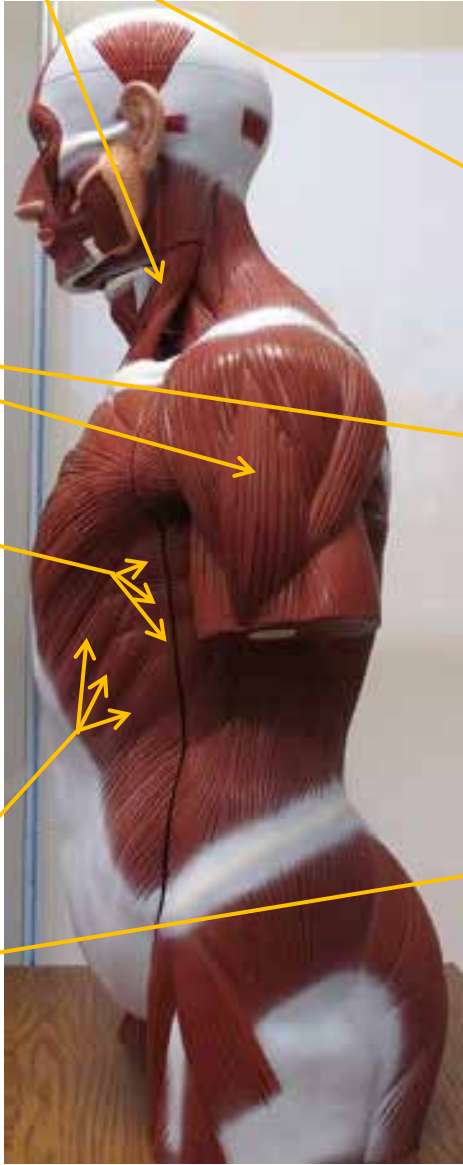
Teres Major

Latissimus  
Dorsi

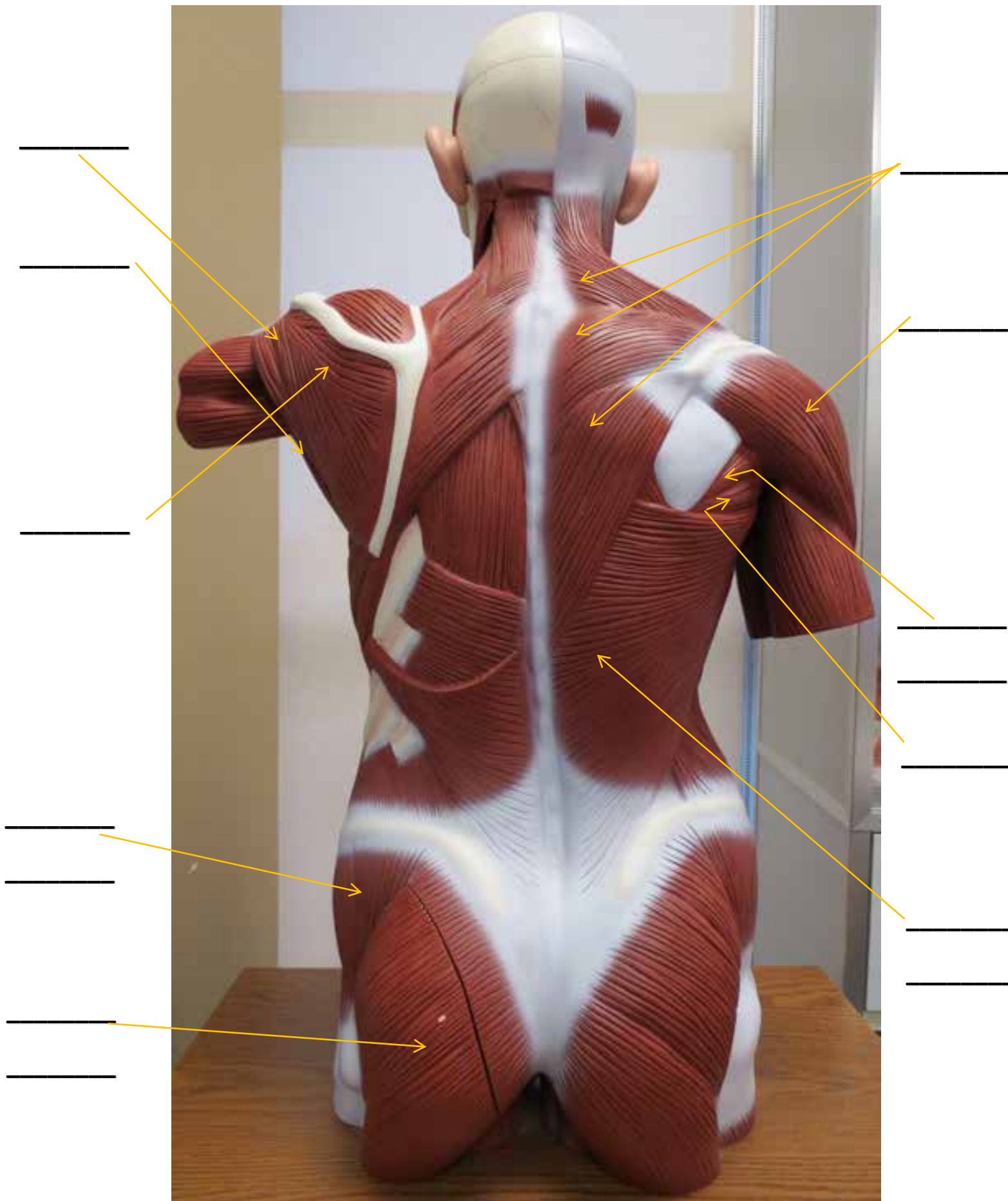
# LARGE MUSCLE MODEL



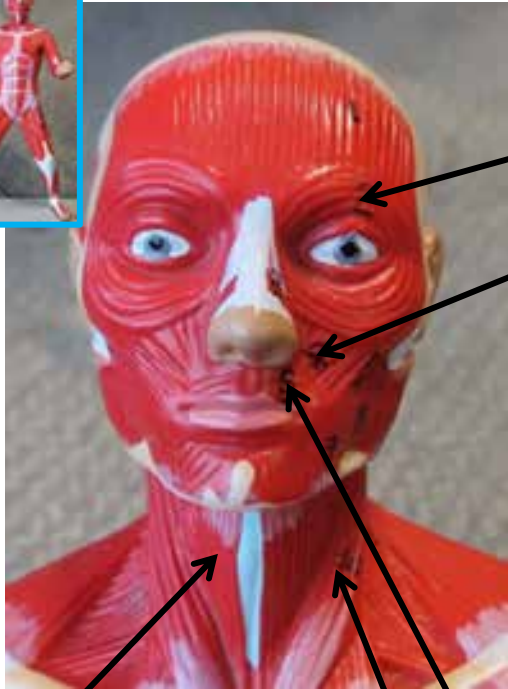
# LARGE MUSCLE MODEL



# LARGE MUSCLE MODEL



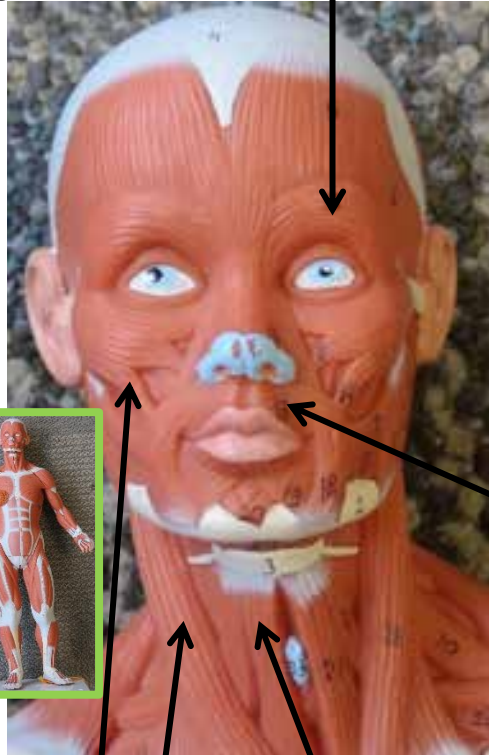
# SMALL MUSCLE MODELS



Sternohyoid

Sternocleidomastoid

Zygomaticus Major



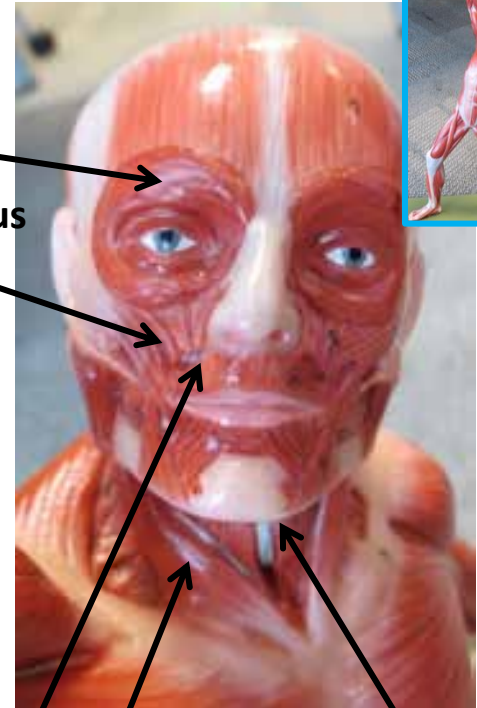
Orbicularis Oculi

Sternohyoid

Sternocleidomastoid

Zygomaticus Major


Orbicularis Oris



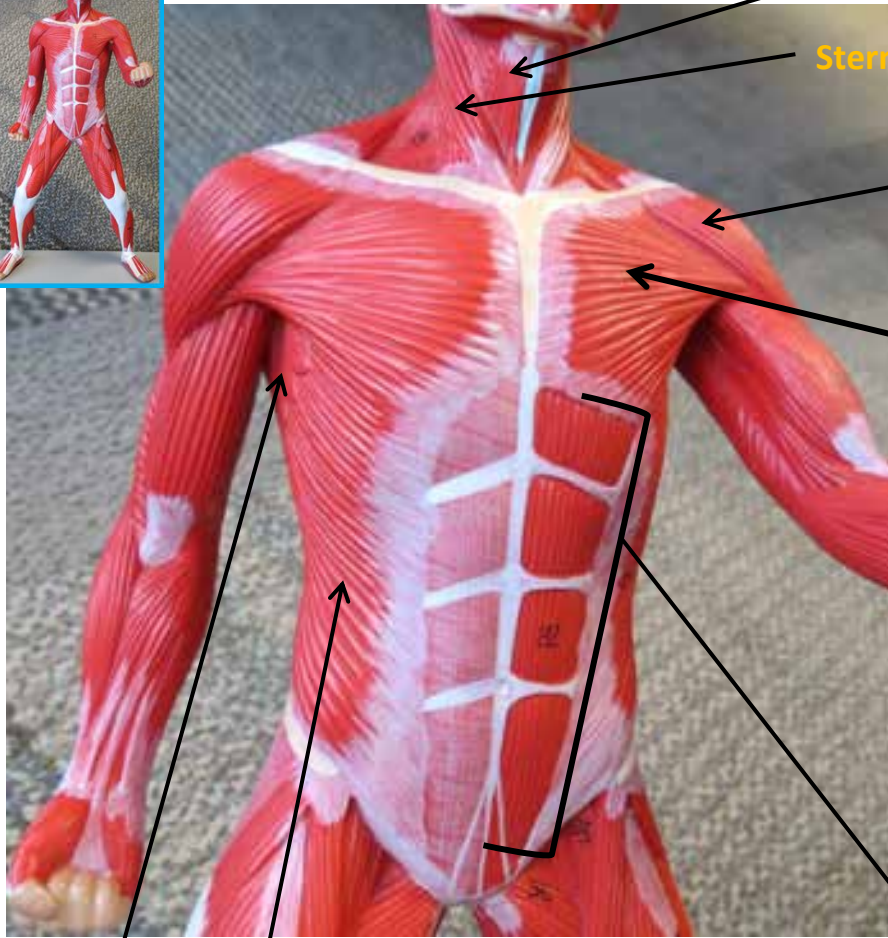
Sternohyoid

Sternocleidomastoid

Zygomaticus Major



# SMALL MUSCLE MODELS



Serratus Anterior

External Obliques

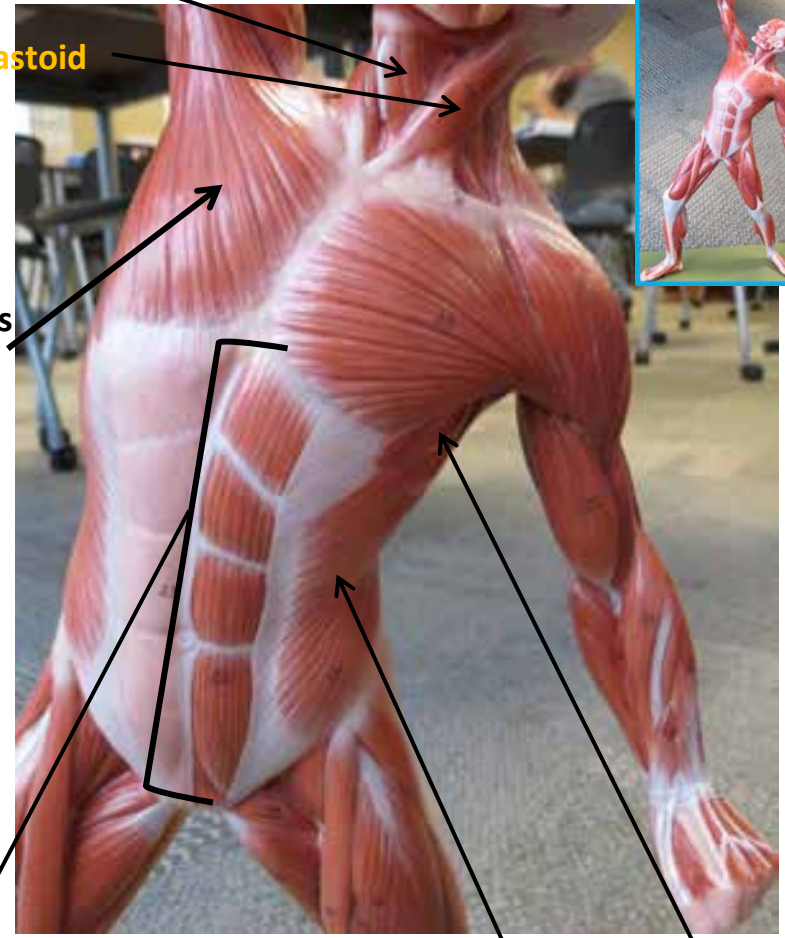
Rectus Abdominis

Sternohyoid

Sternocleidomastoid

Deltoid

Pectoralis Major

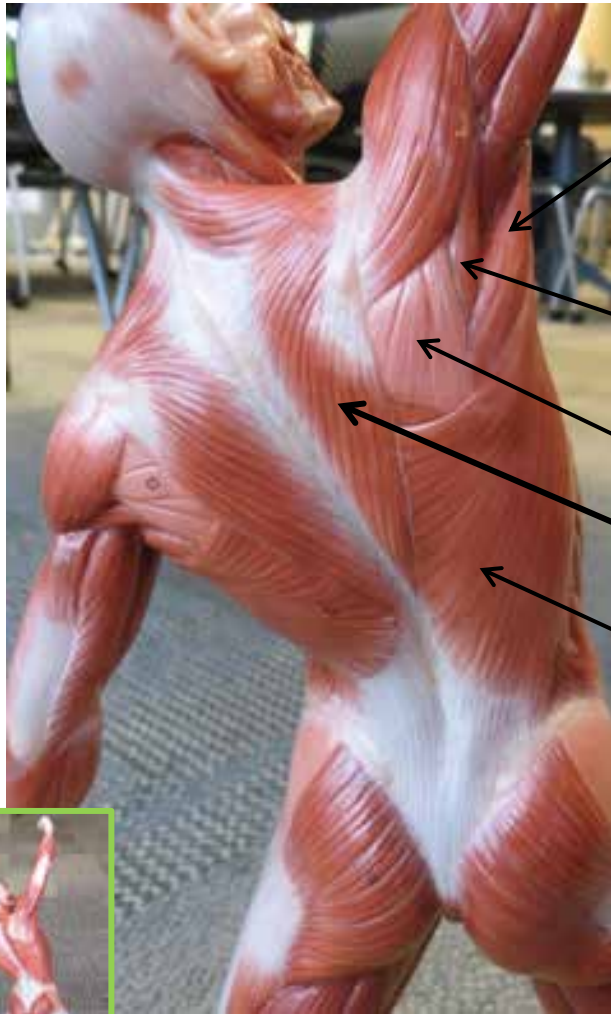


External Obliques

Serratus Anterior



# SMALL MUSCLE MODELS



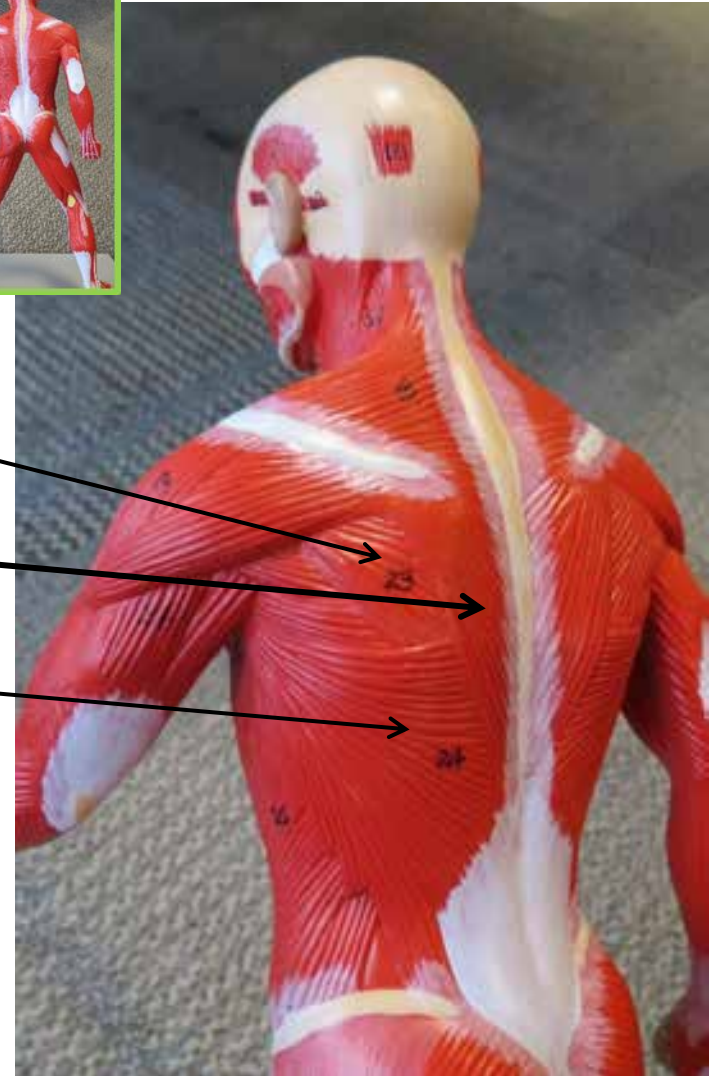

**Teres Major**

**Teres Minor**

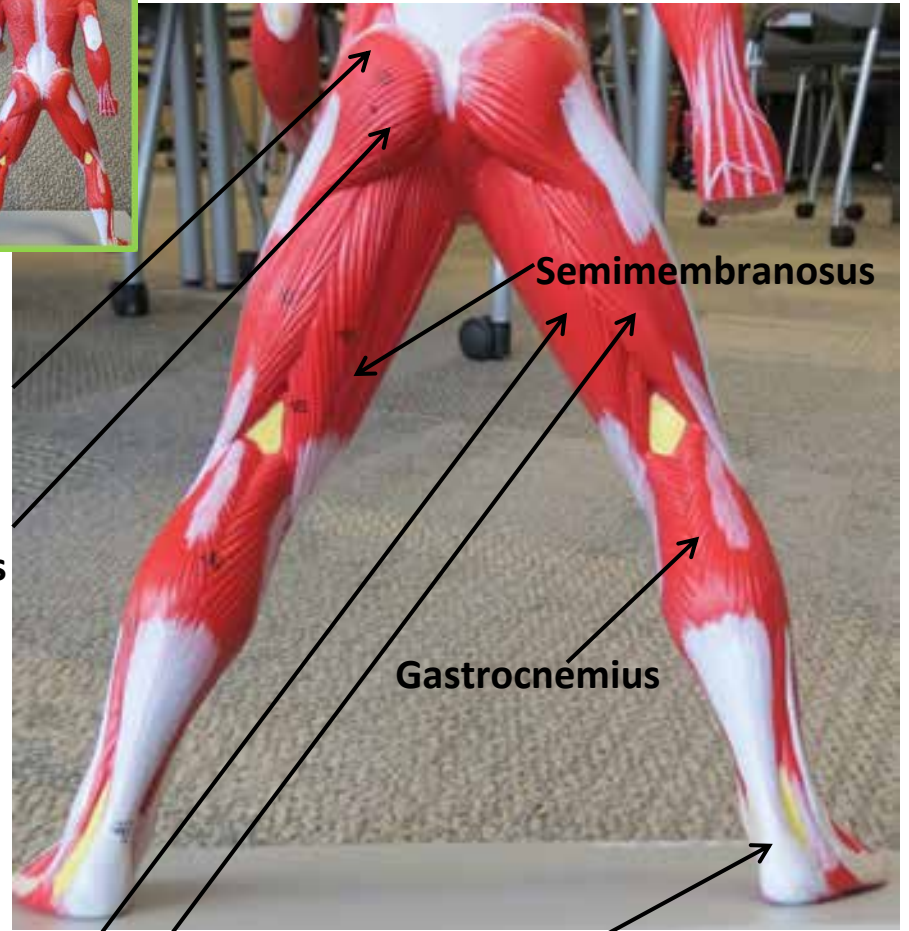
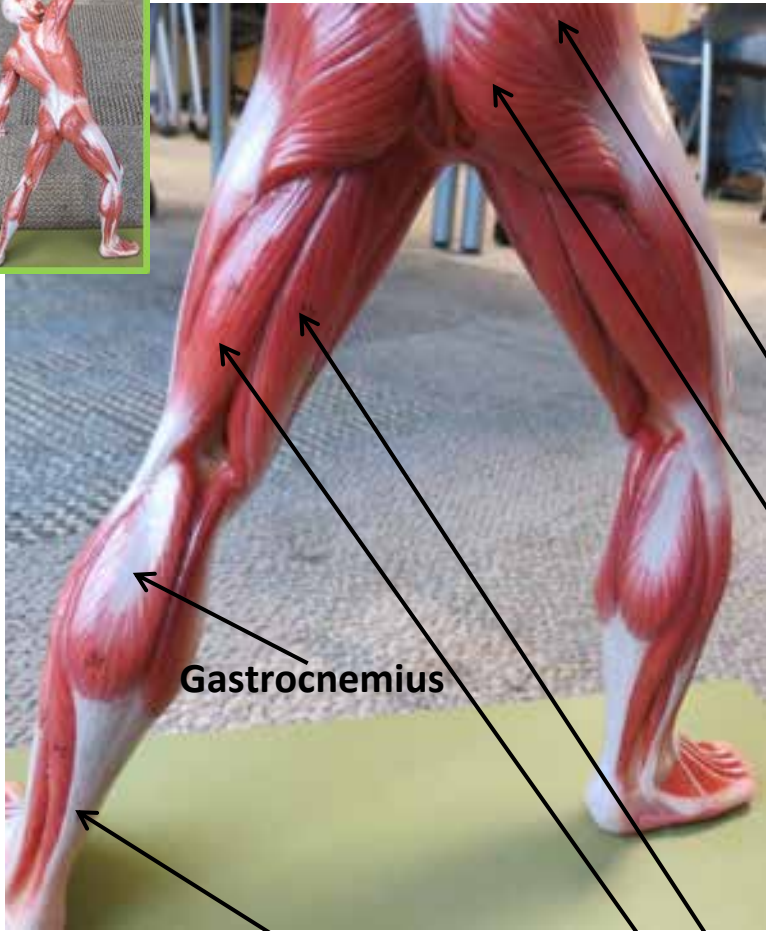
**Infraspinatus**

**Trapezius**

**Latissimus Dorsi**



# SMALL MUSCLE MODELS



**Gluteus Medius**

**Gluteus Maximus**

**Gastrocnemius**

**Semimembranosus**


**Gastrocnemius**

**Semitendinosus**

**Biceps Femoris**

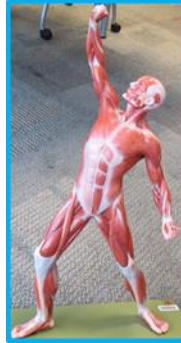**Tendon of Gastrocnemius**

# SMALL MUSCLE MODELS



**Sternocleidomastoid**

**Palmaris Longus**



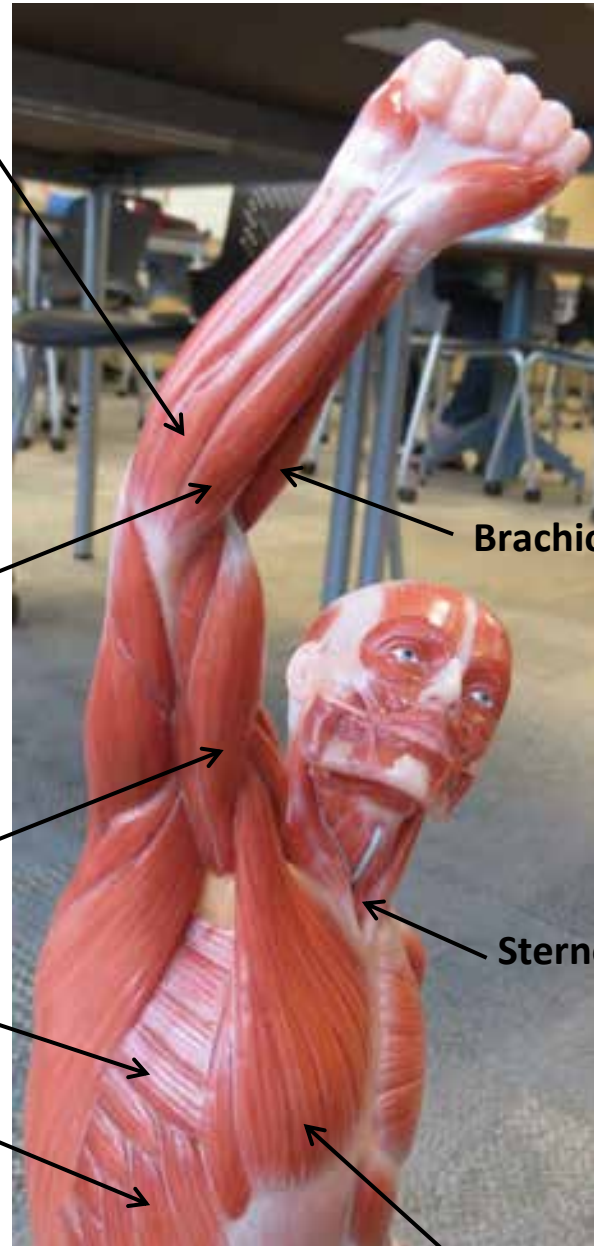
**Flexor Carpi Radialis**

**Deltoid**

**Biceps Brachii**

**Serratus Anterior**

**External Obliques**



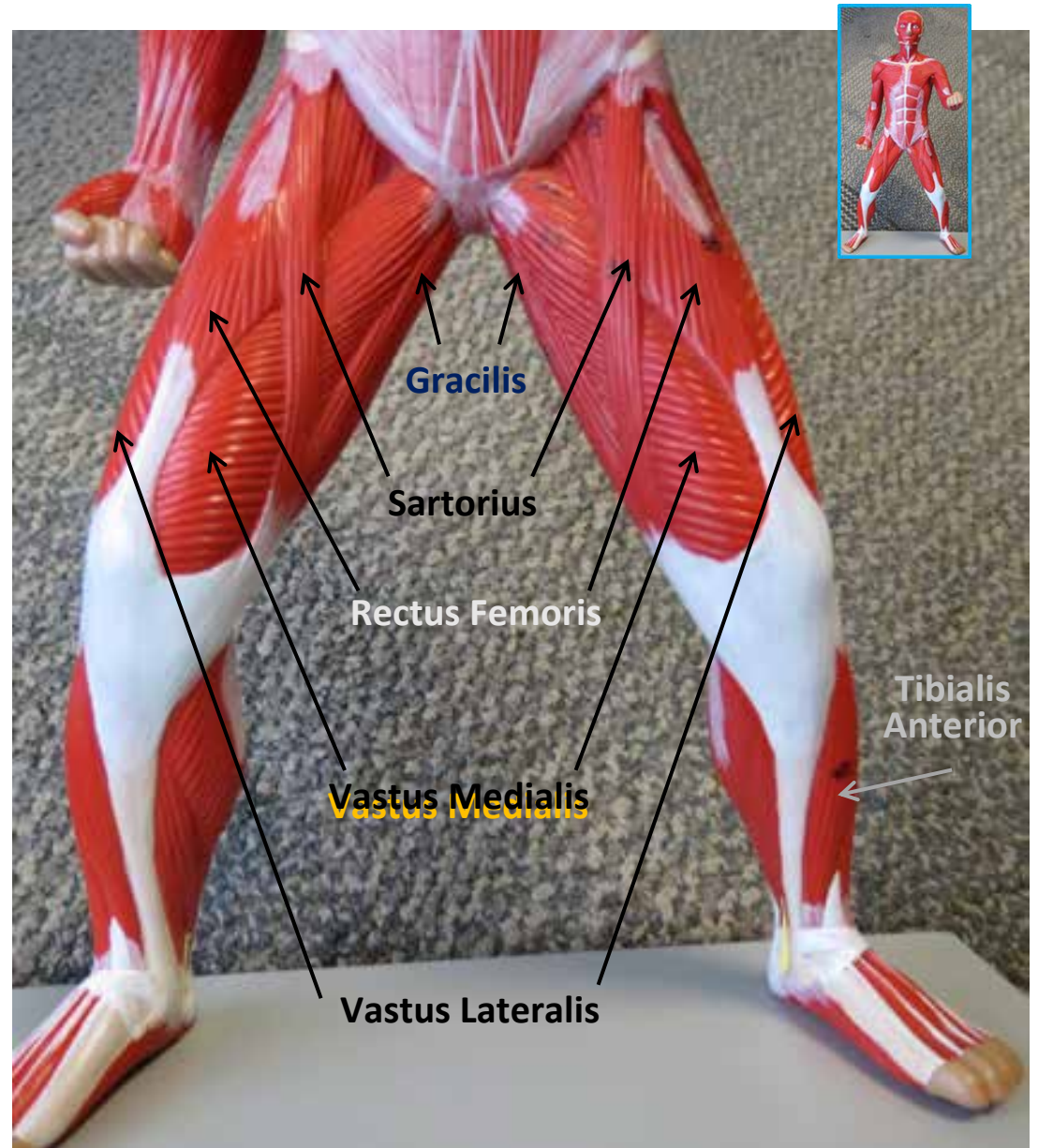
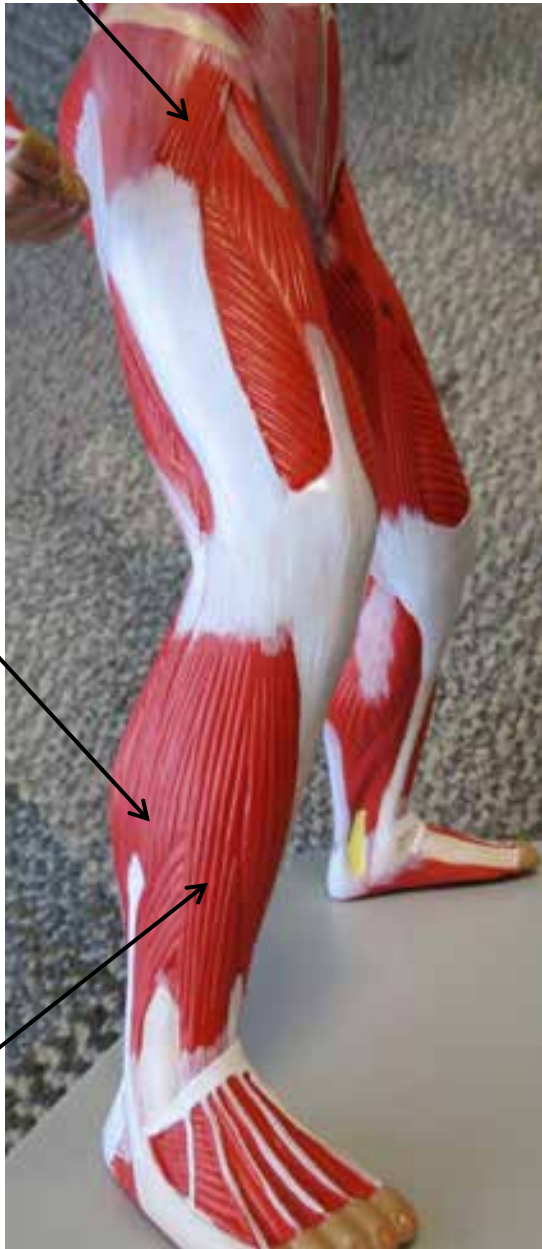
**Brachioradialis**

**Sternohyoid**

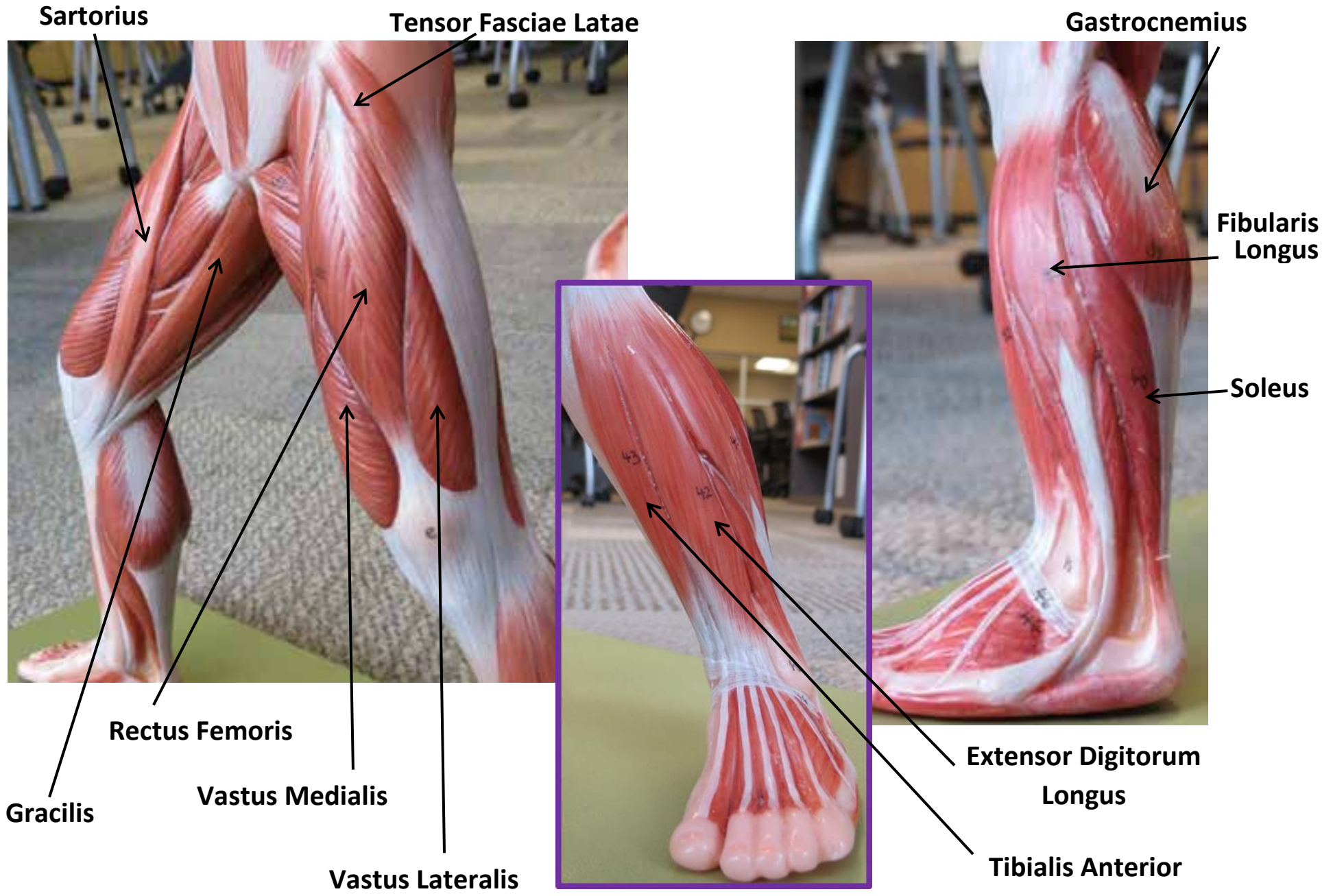
**Pectoralis Major**

# SMALL MUSCLE MODELS

Tensor Fasciae Latae



# SMALL MUSCLE MODELS



Sartorius

Tensor Fasciae Latae

Gastrocnemius

Fibularis Longus

Soleus

Extensor Digitorum Longus

Tibialis Anterior

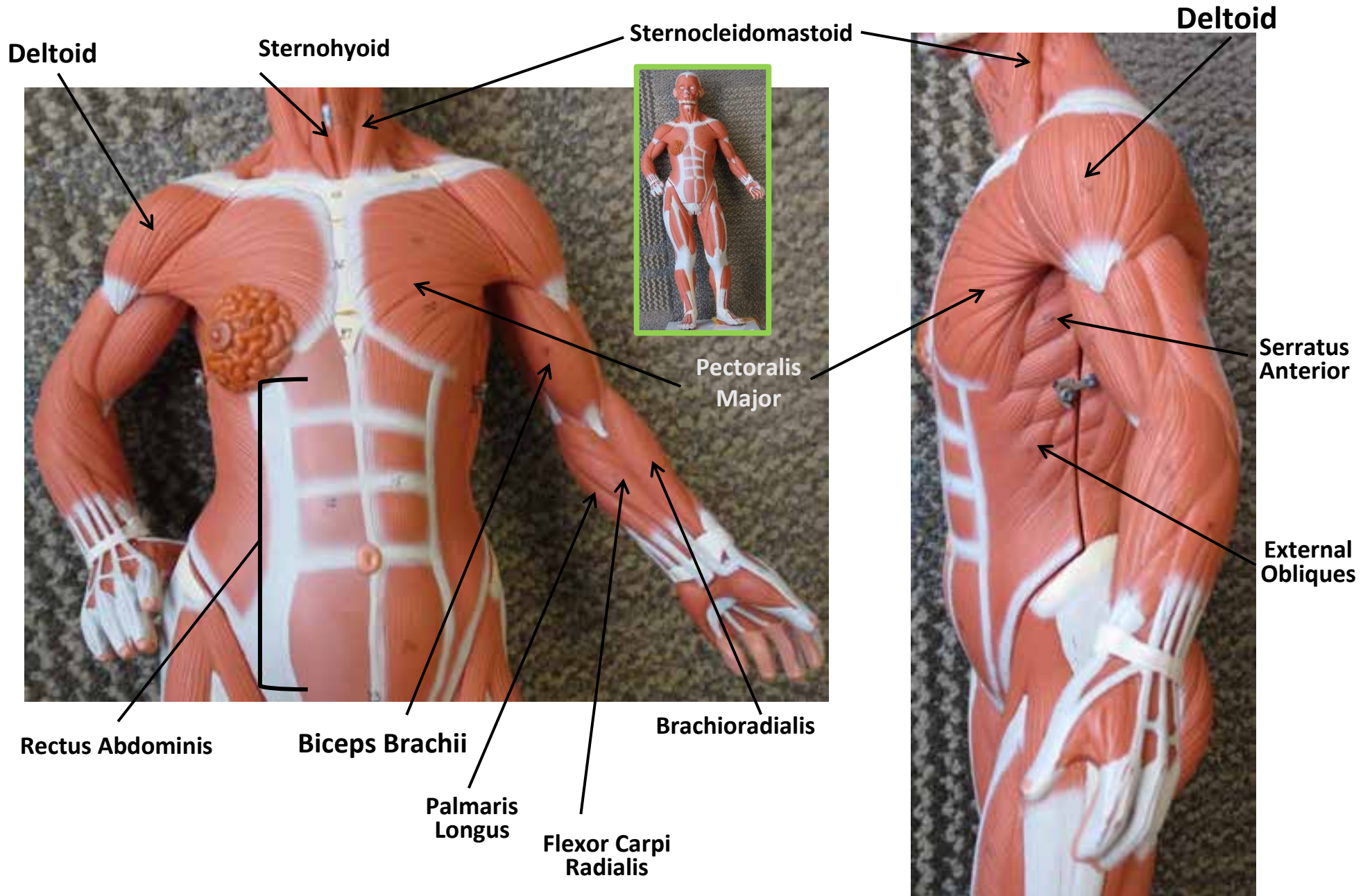
Rectus Femoris

Vastus Medialis

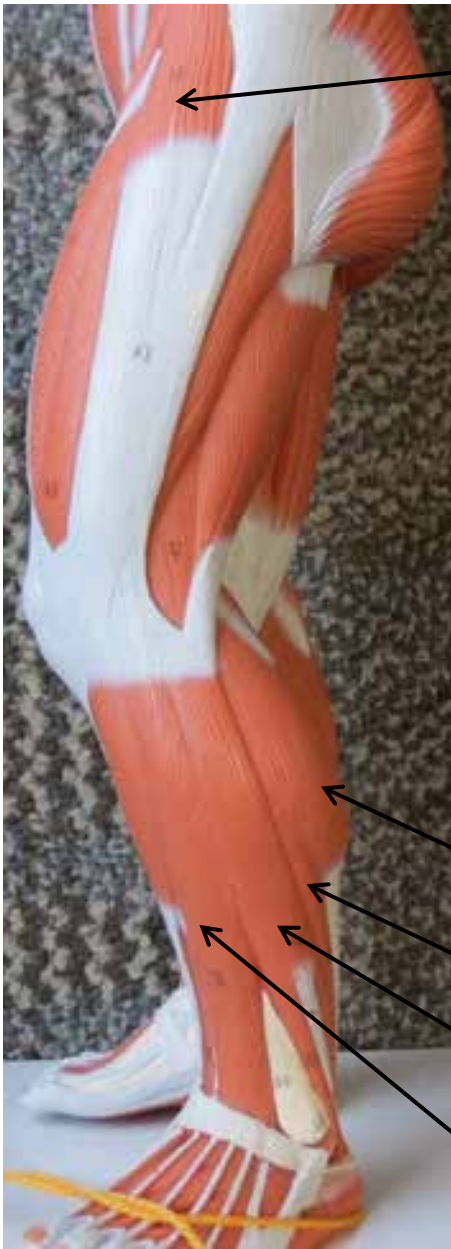Vastus Lateralis

Gracilis

# SMALL MUSCLE MODELS



# SMALL MUSCLE MODELS



Tensor Fasciae Latae

Sartorius

Vastus Lateralis

Rectus Femoris

Vastus Medialis

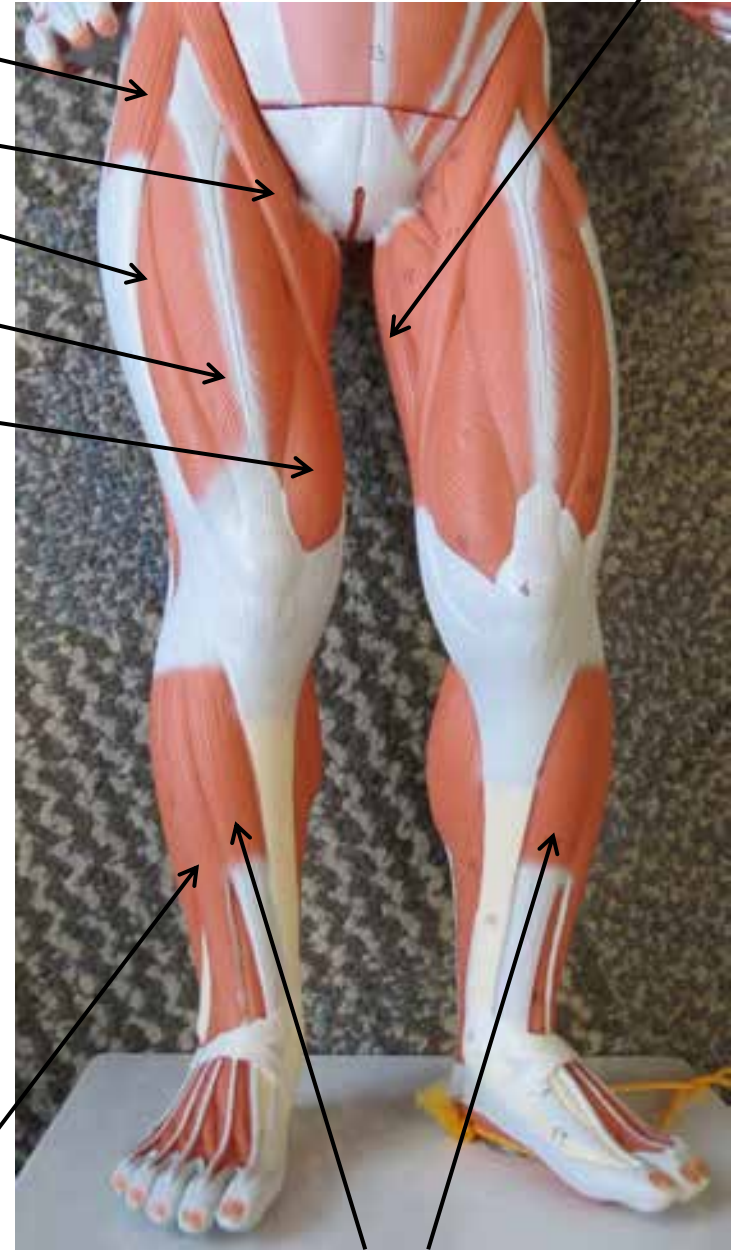


Gastrocnemius

Soleus

Fibularis Longus

Extensor Digitorum Longus



Gracilis

Tibialis Anterior

# SMALL MUSCLE MODELS



**Deltoid**

**Infraspinatus**

**Trapezius**

**Teres Minor**

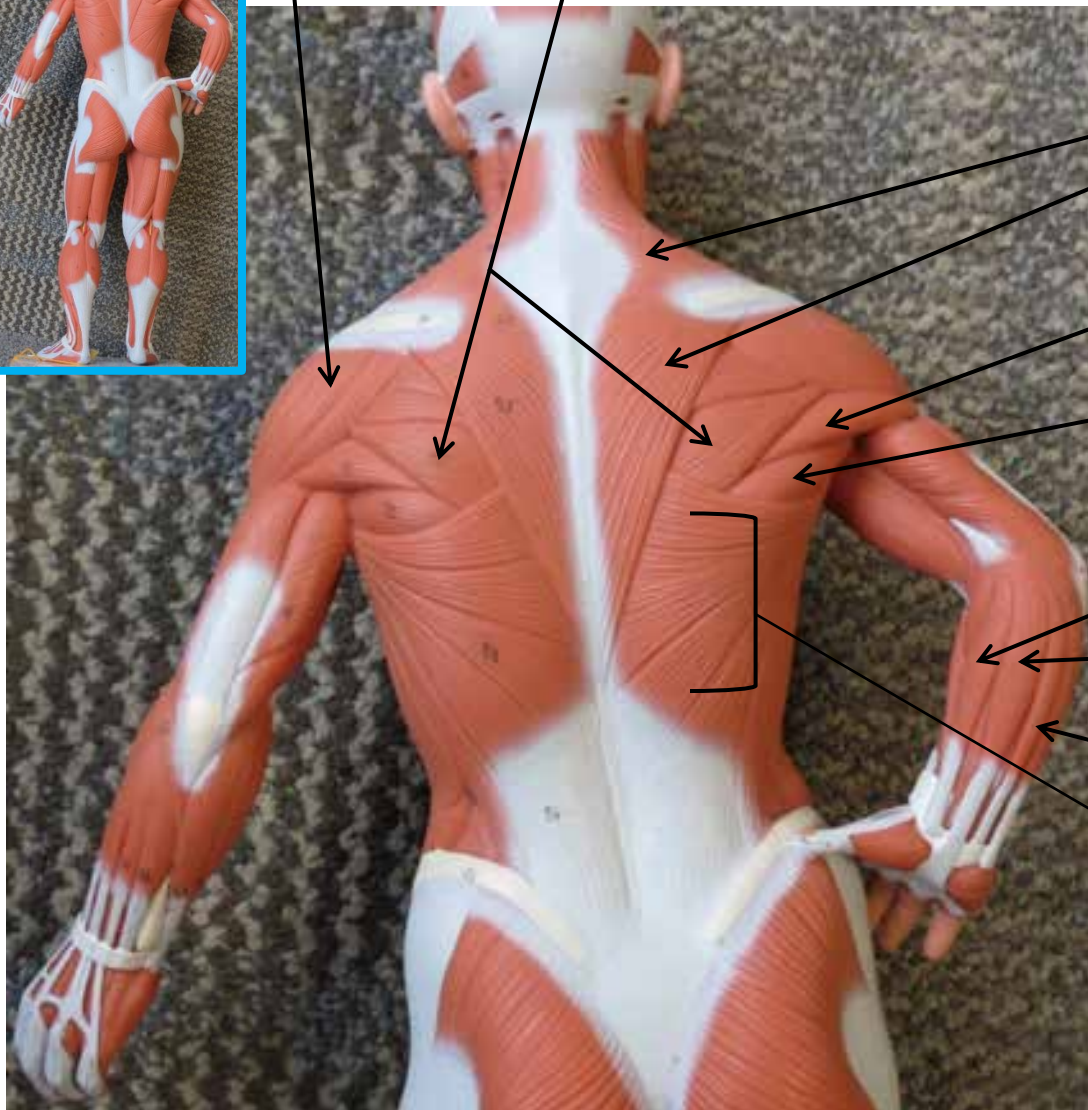
**Teres Major**

**Brachioradialis**

**Flexor Carpi Radialis**

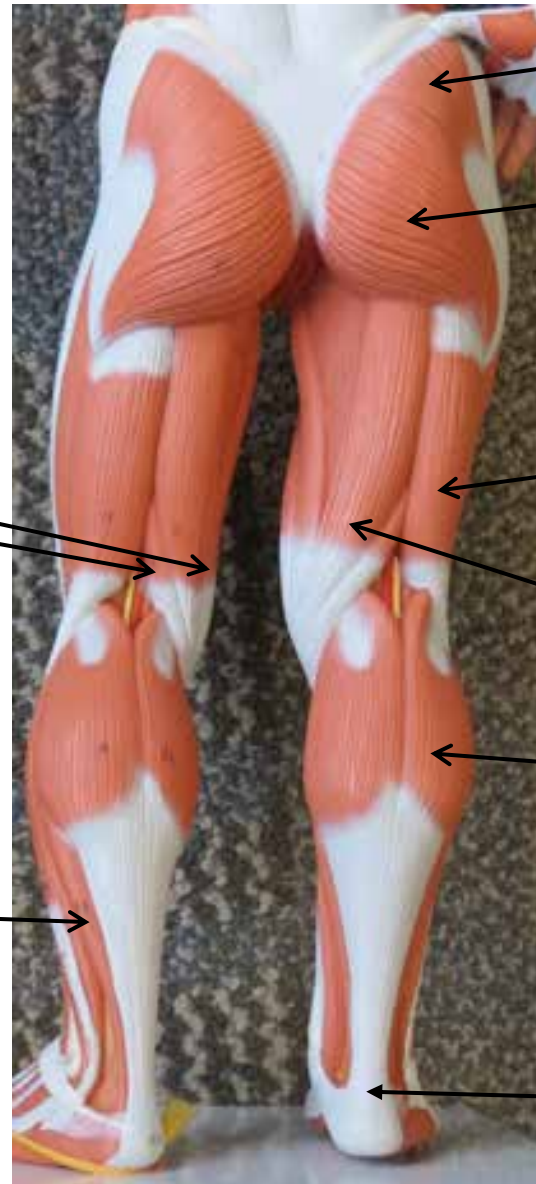
**Palmaris Longus**

**Latissimus Dorsi**





# SMALL MUSCLE MODELS



Gluteus Medius

Gluteus Maximus

Biceps Femoris

Semitendinosus

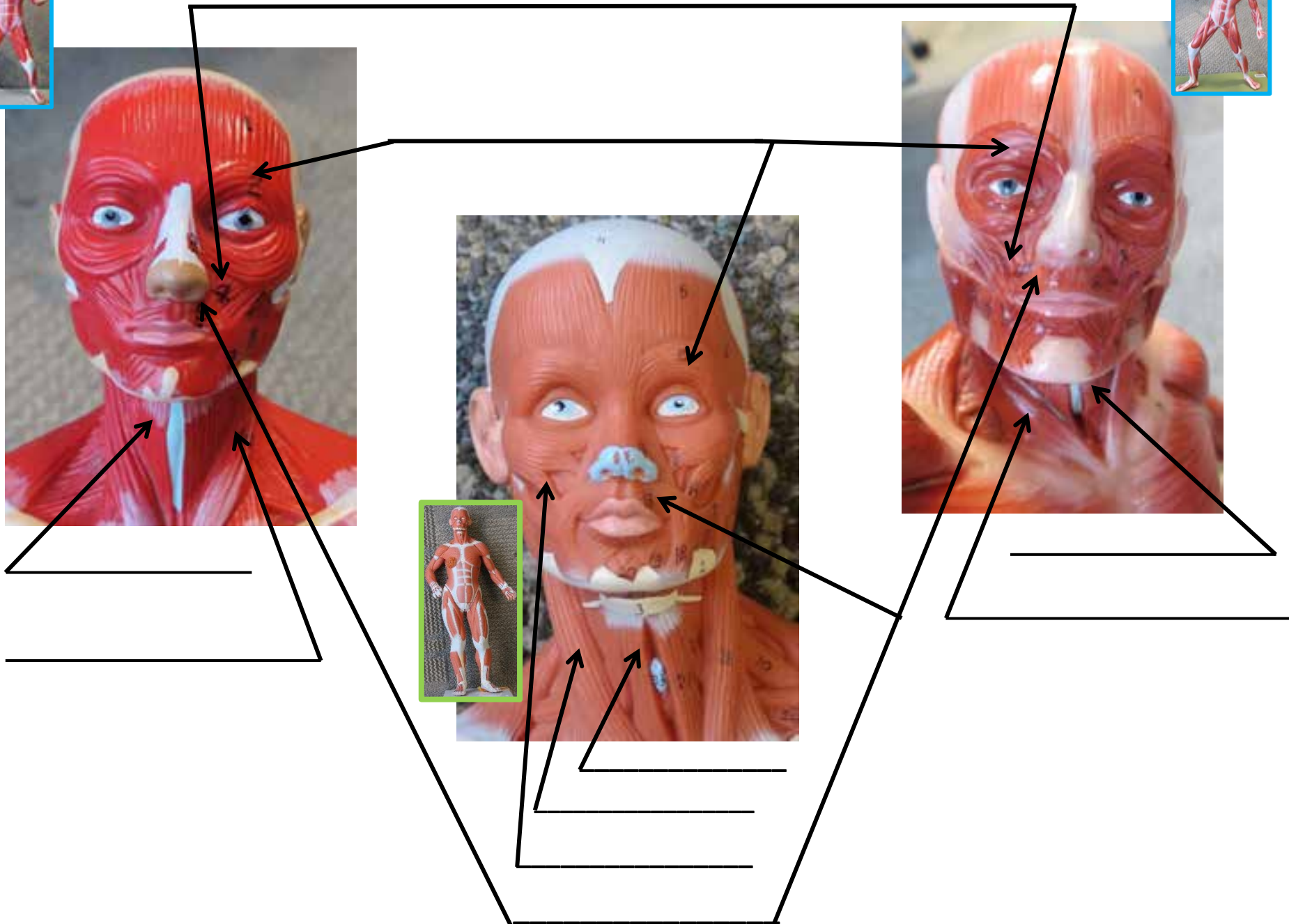
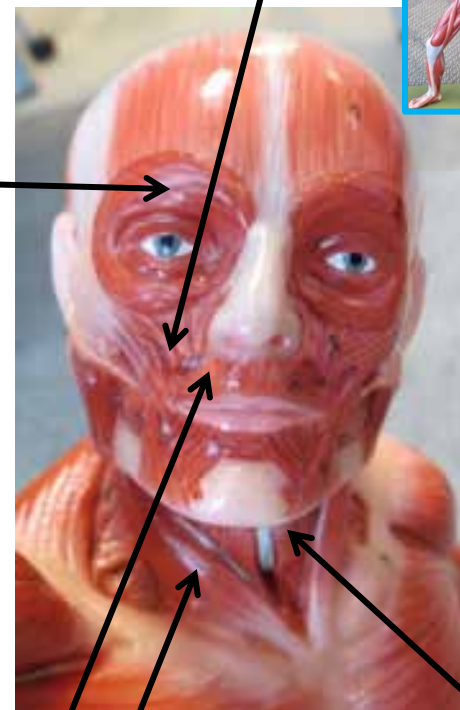
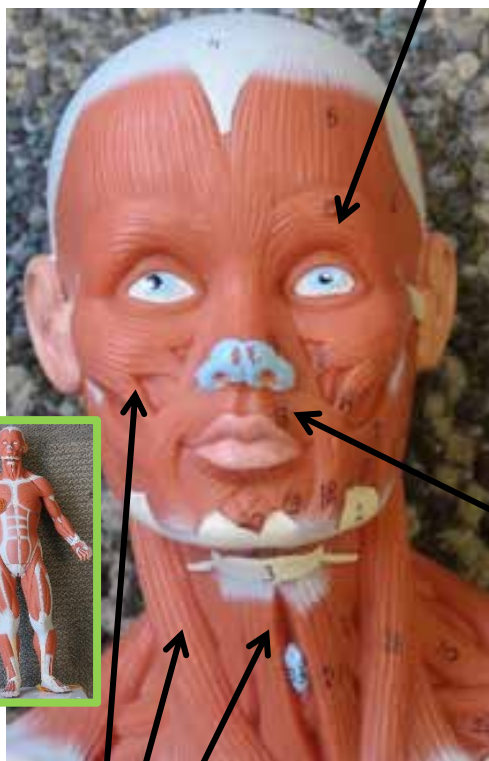

Gastrocnemius

Tendon of  
Gastrocnemius

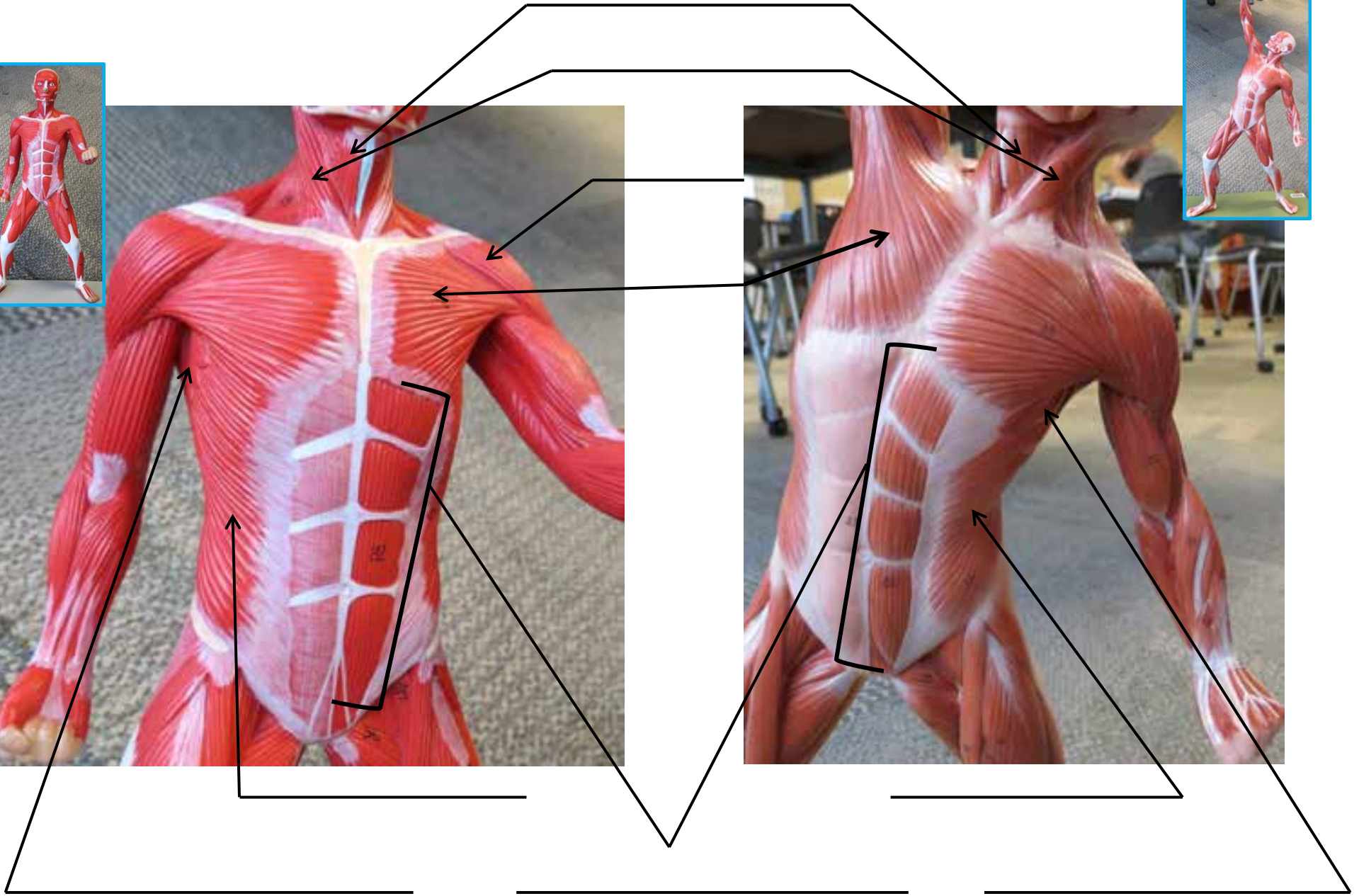
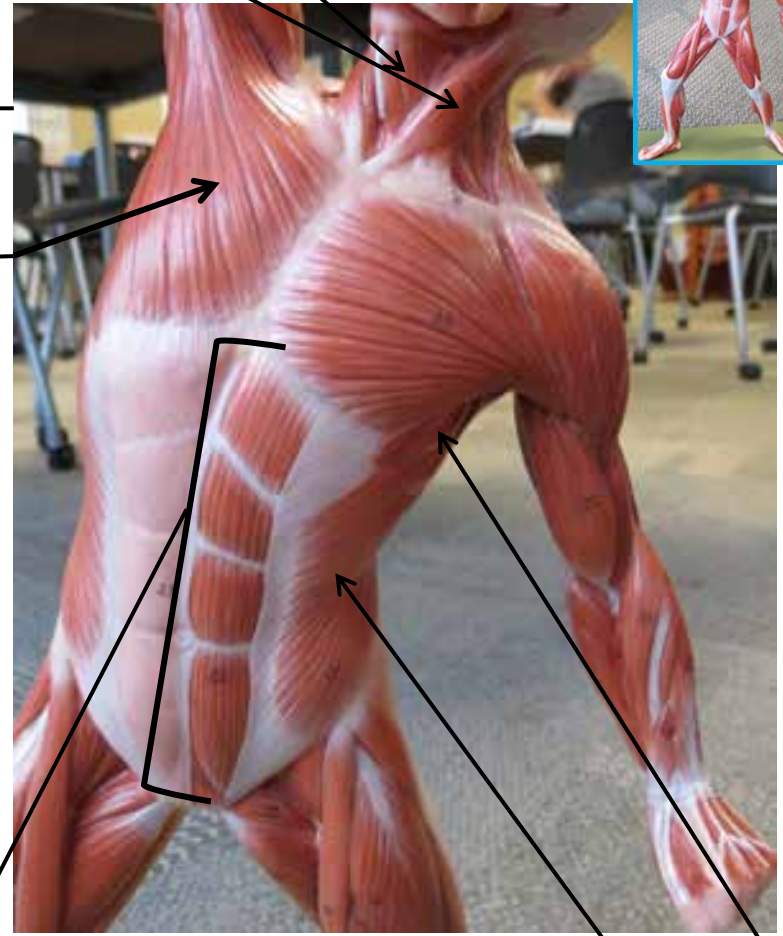
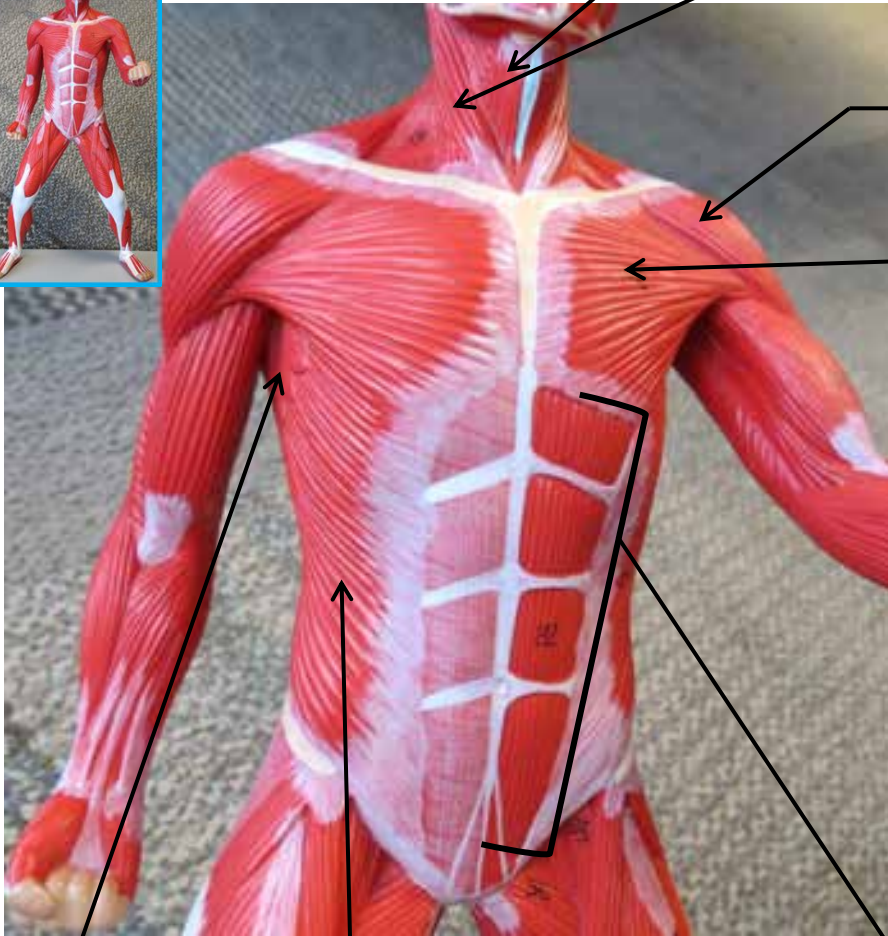
Semimembranosus

Soleus

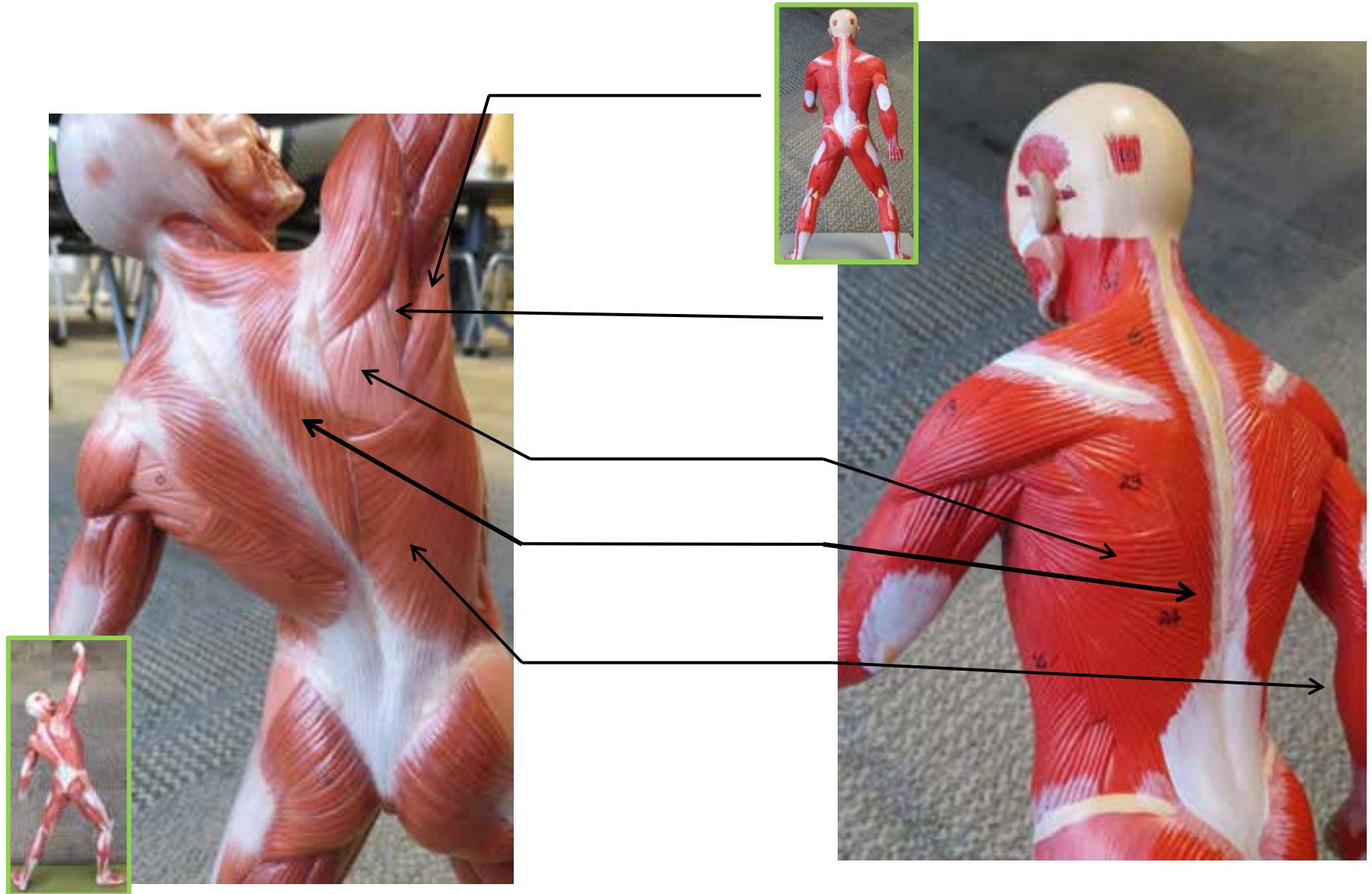
# SMALL MUSCLE MODELS



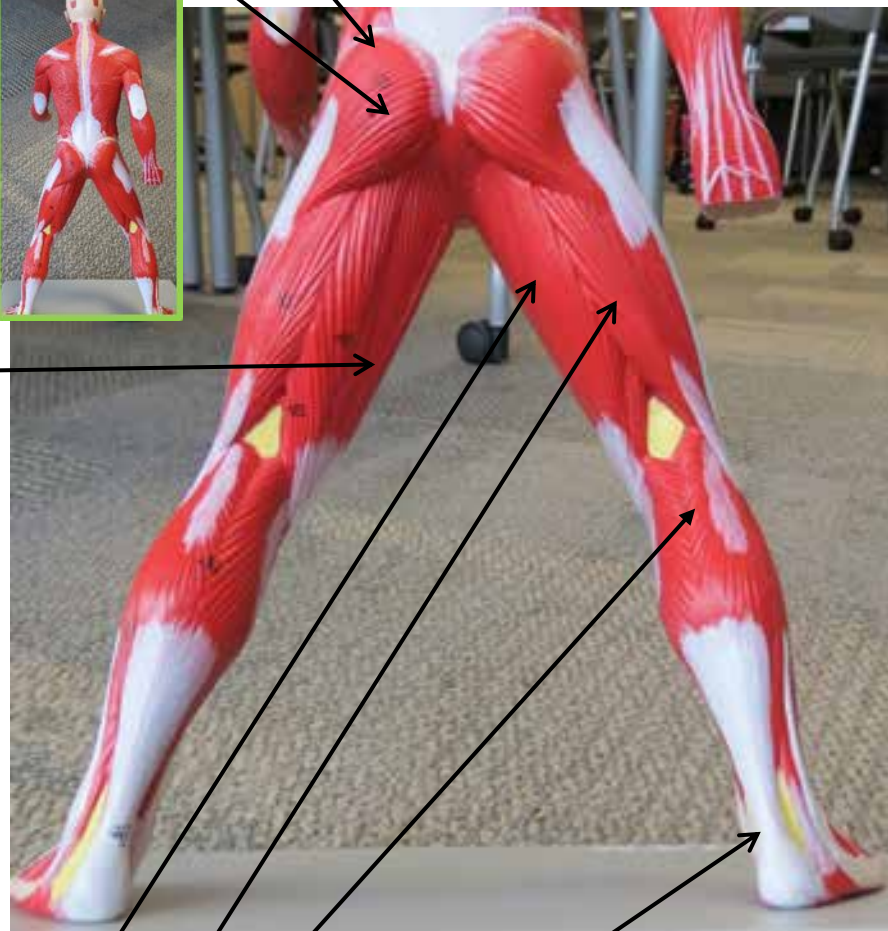
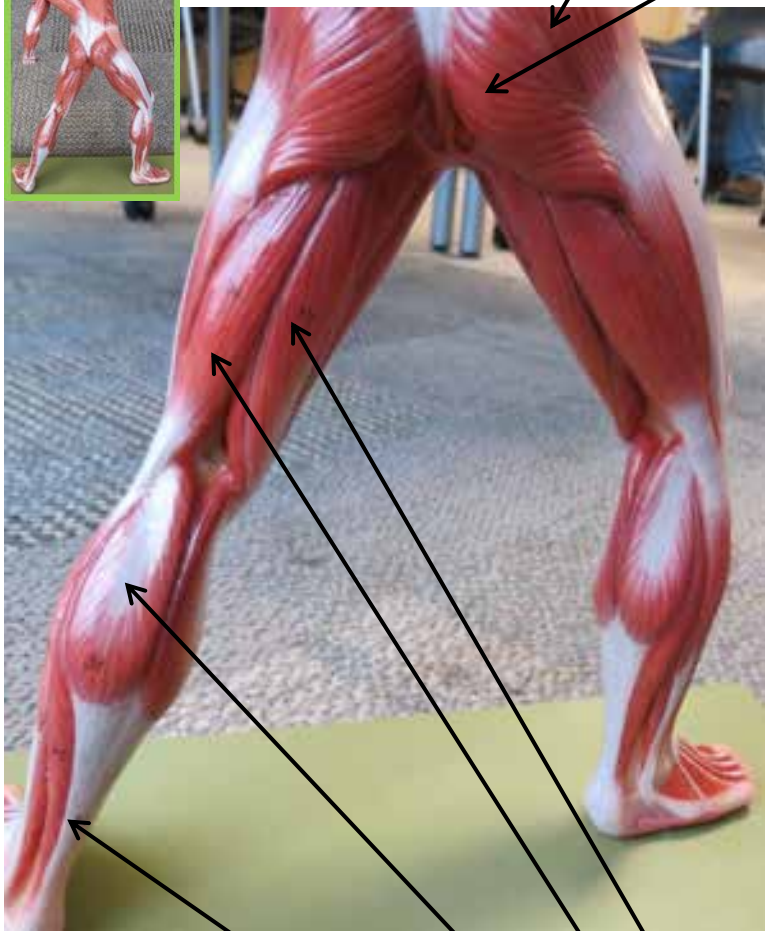
# SMALL MUSCLE MODELS




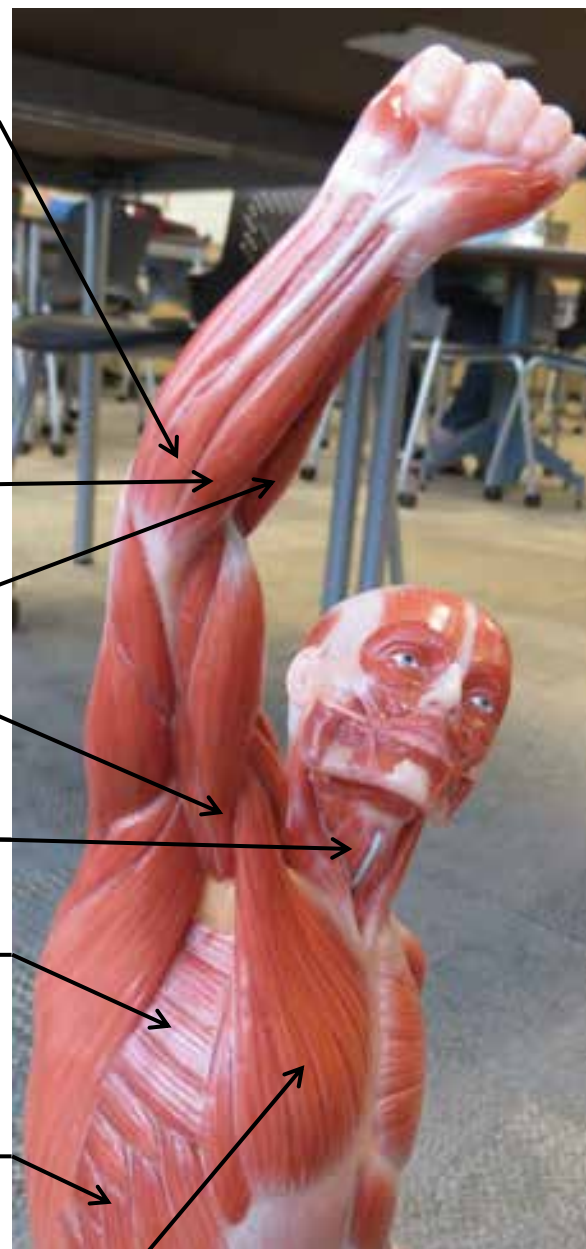
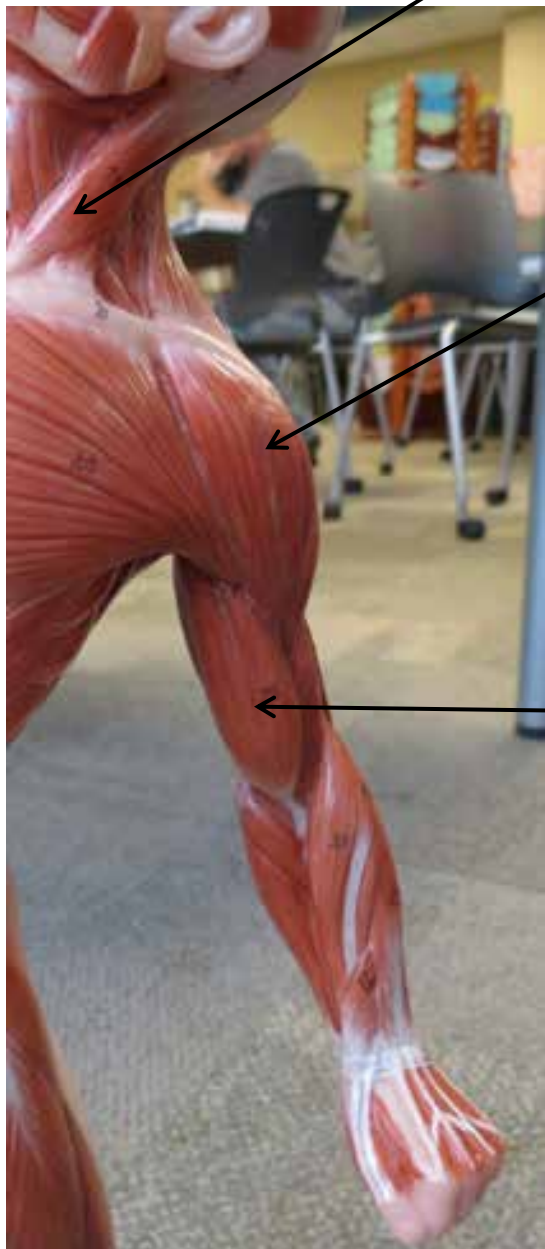
# SMALL MUSCLE MODELS




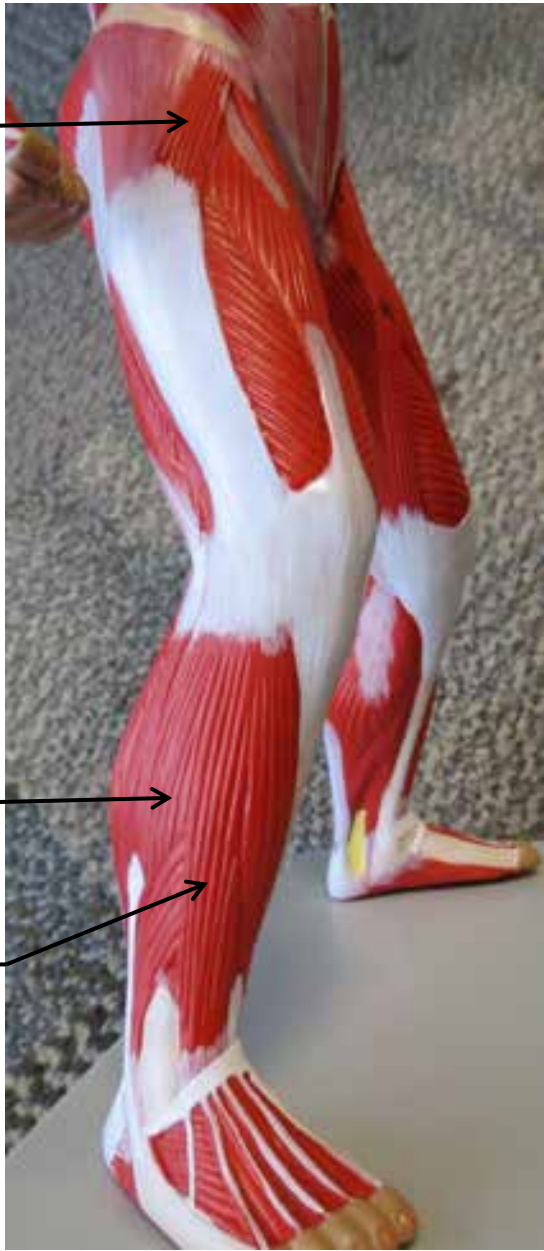
# SMALL MUSCLE MODELS



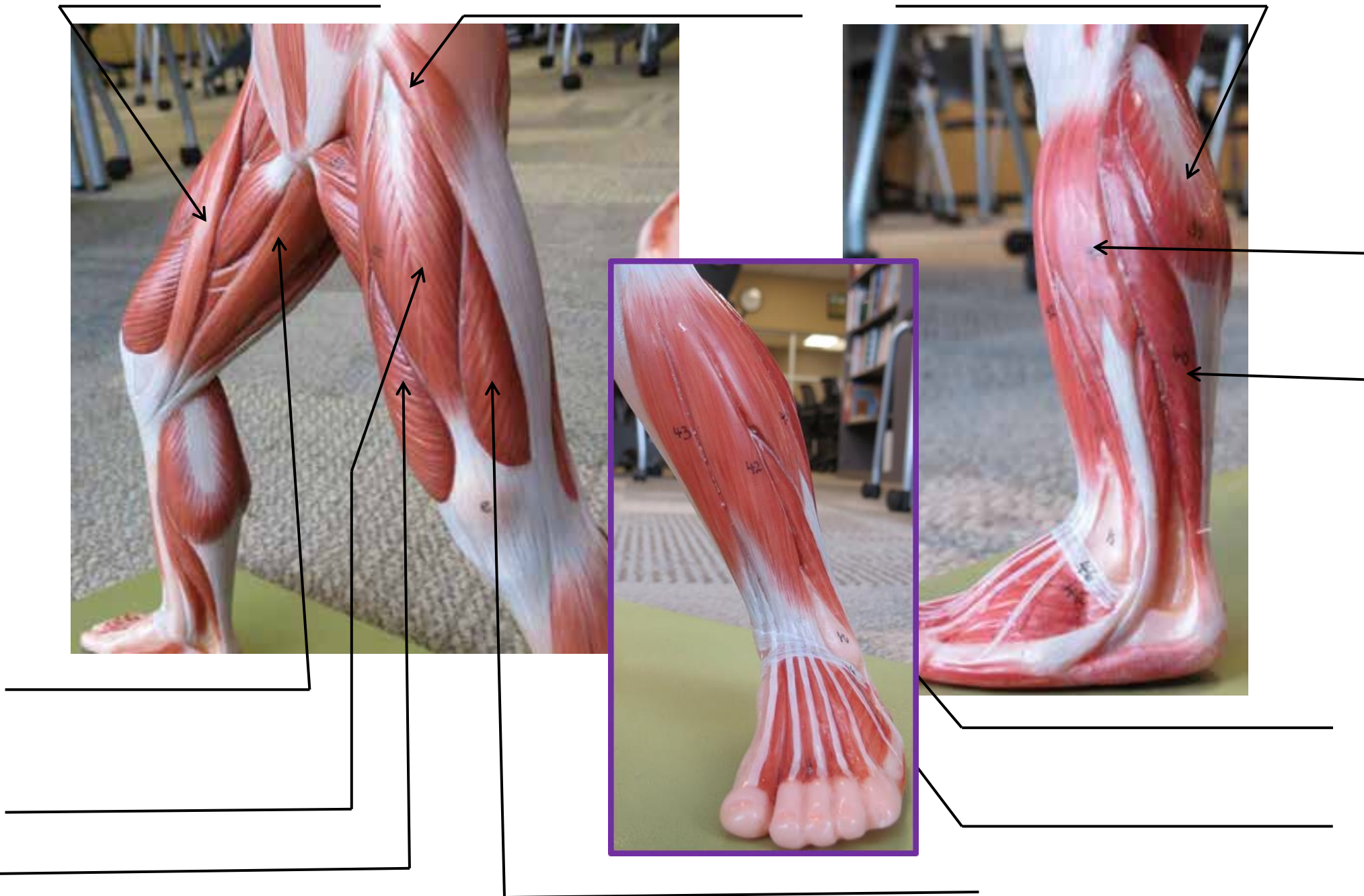
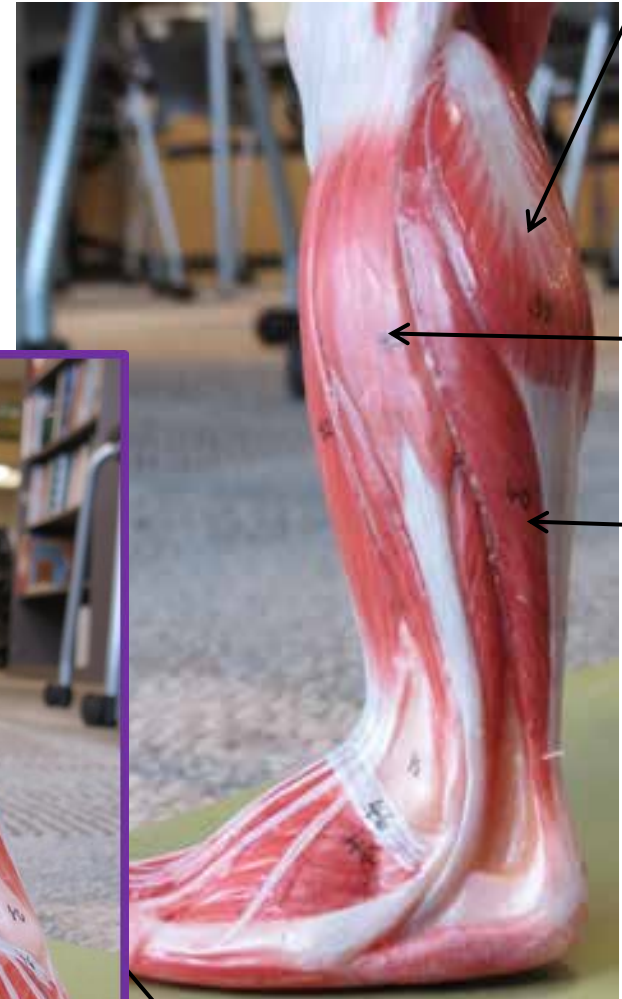
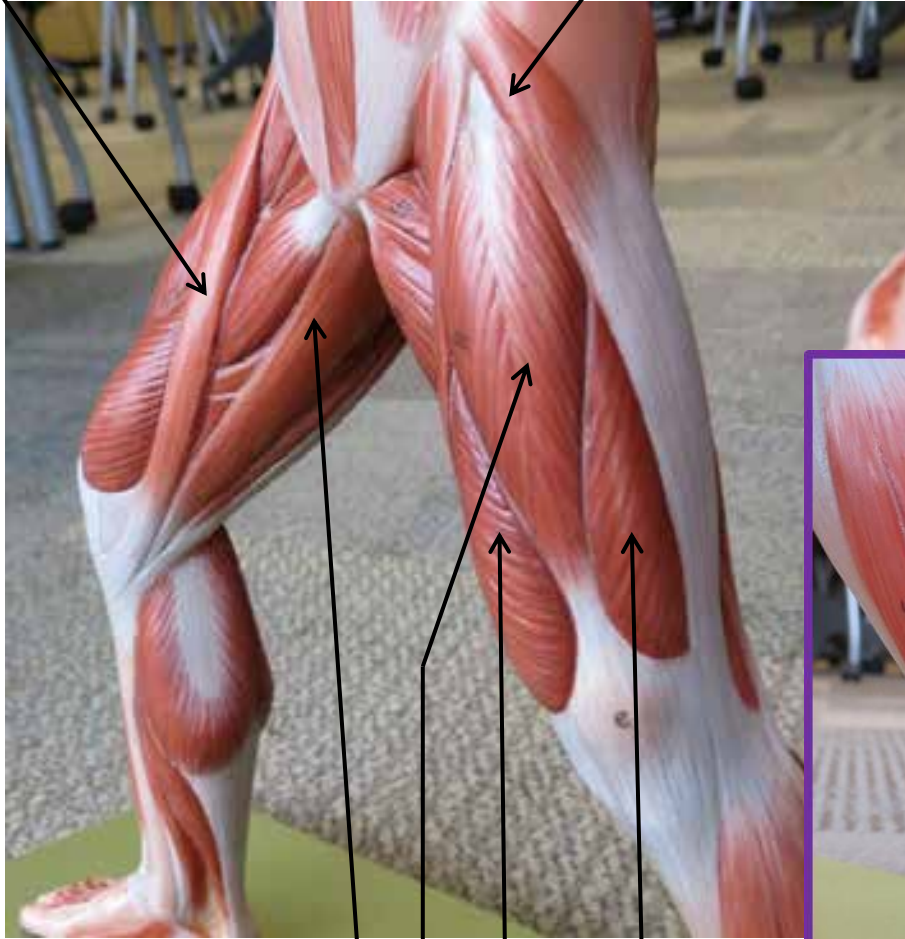
# SMALL MUSCLE MODELS



# SMALL MUSCLE MODELS

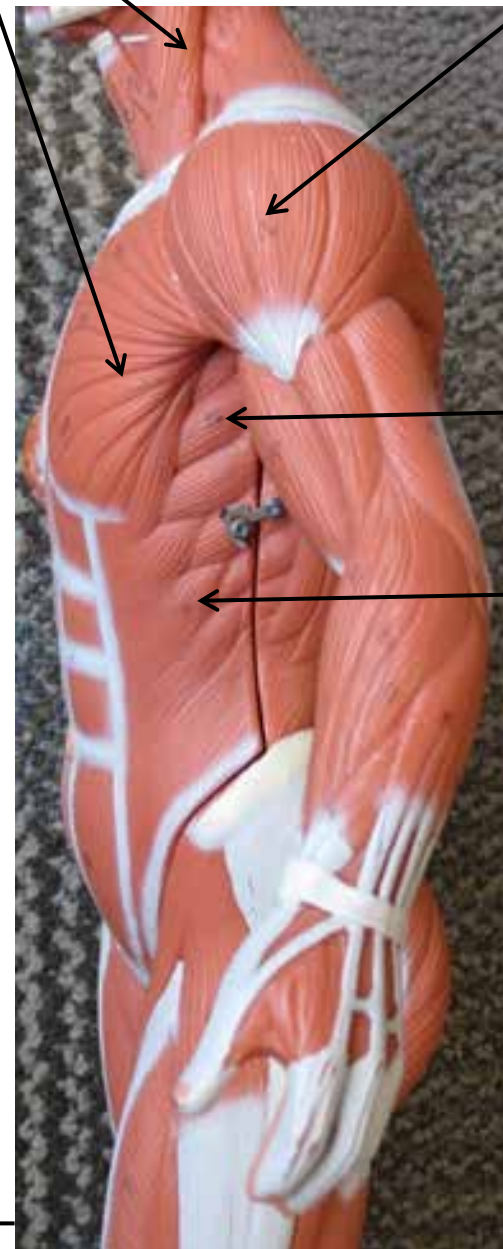
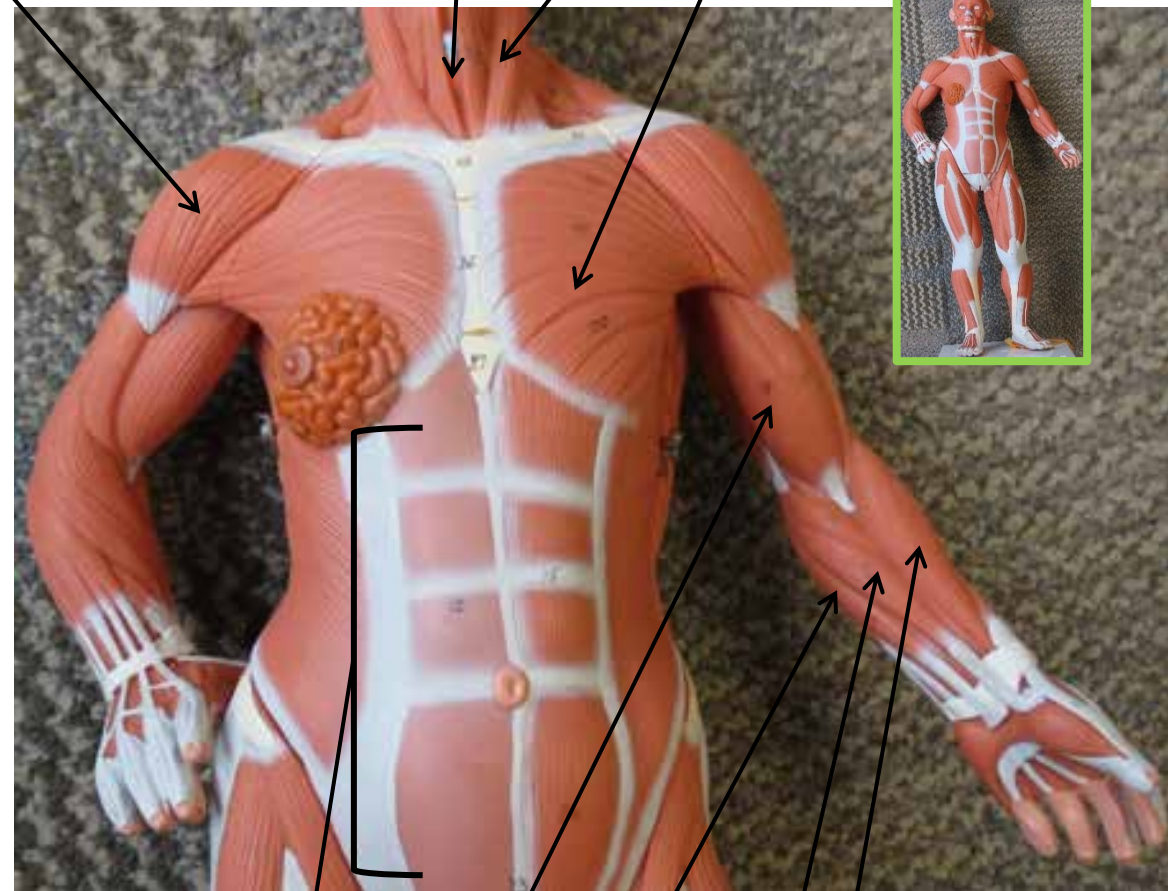


# SMALL MUSCLE MODELS

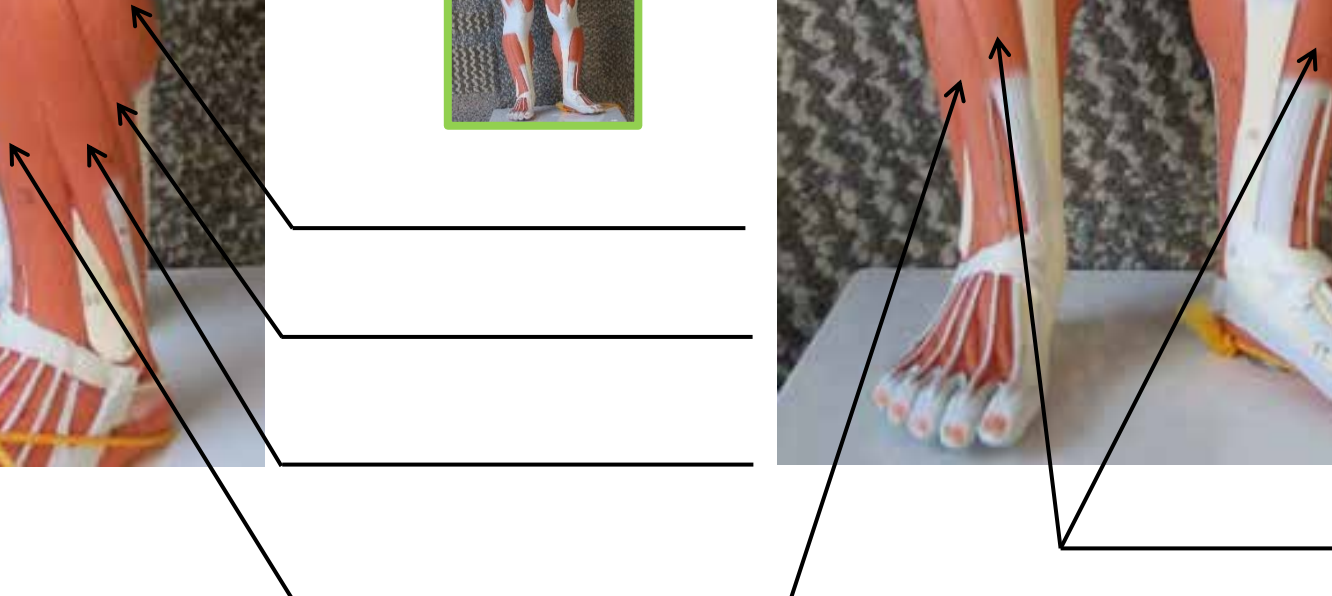
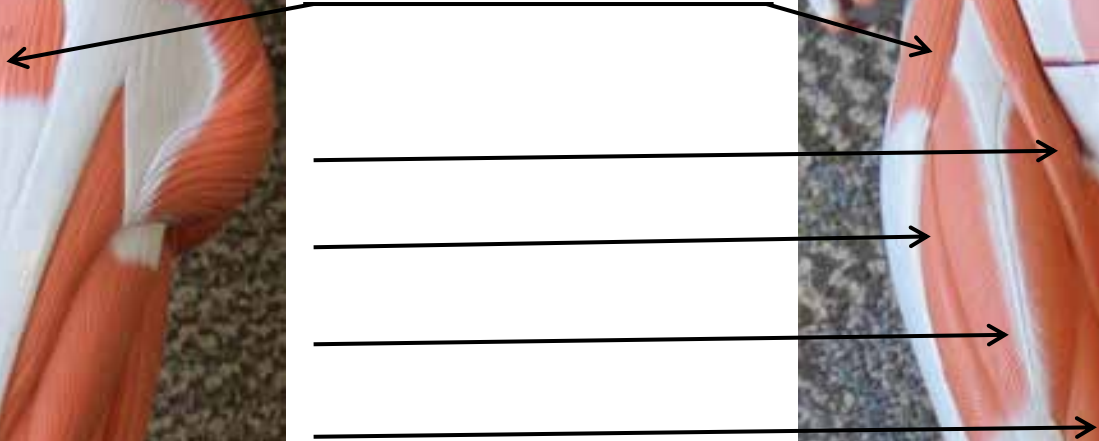
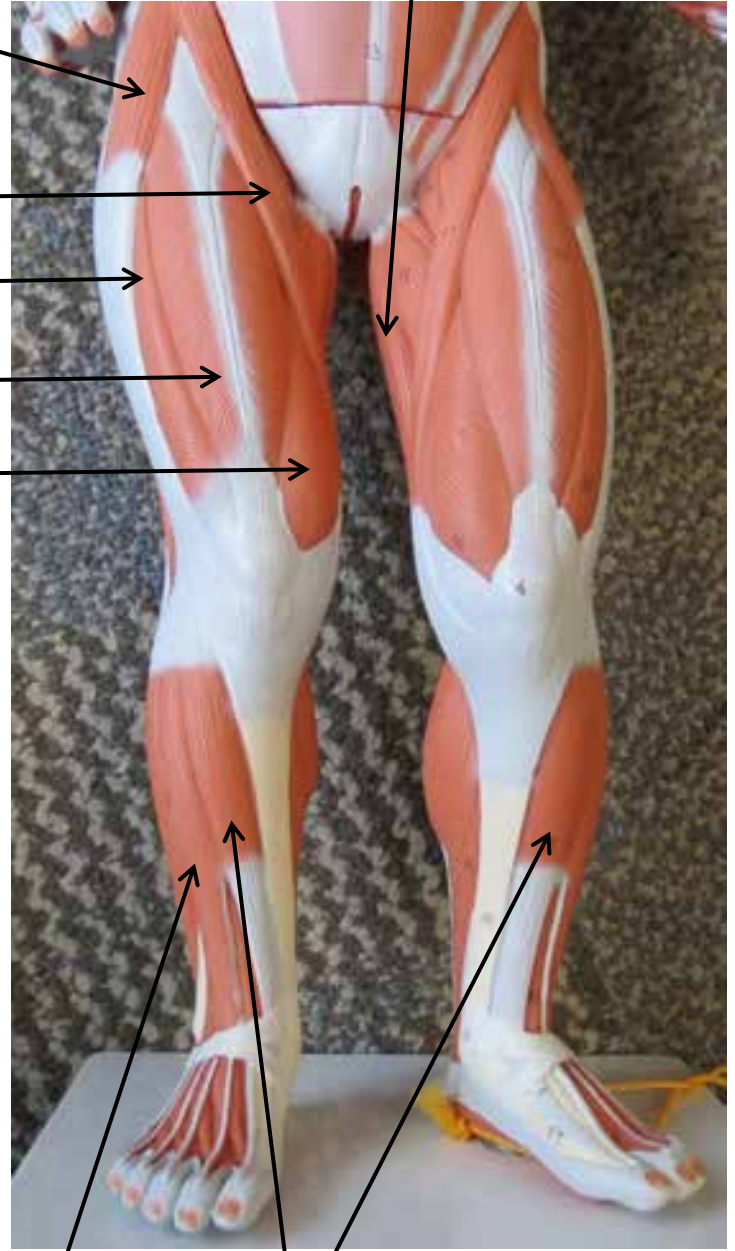
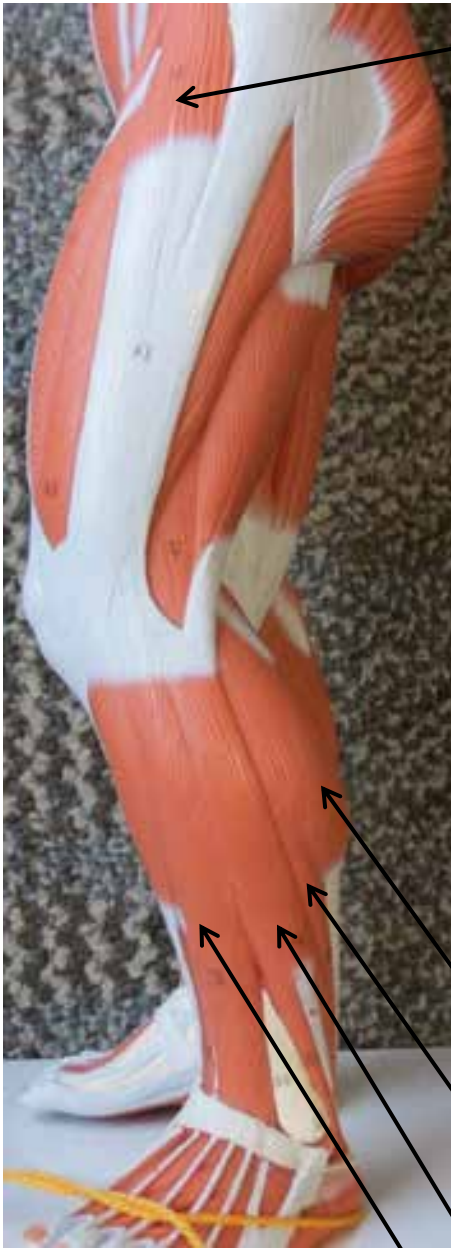



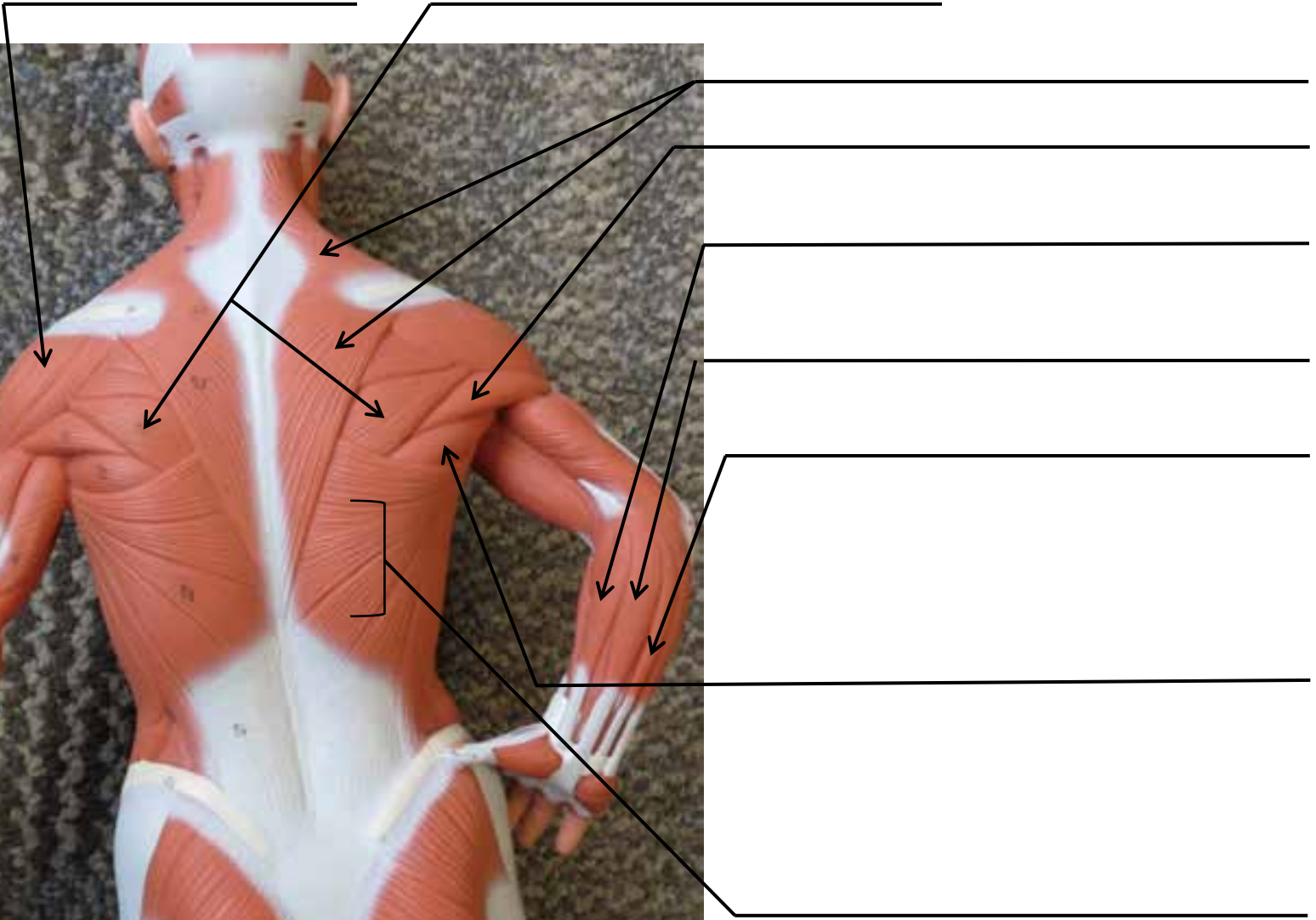
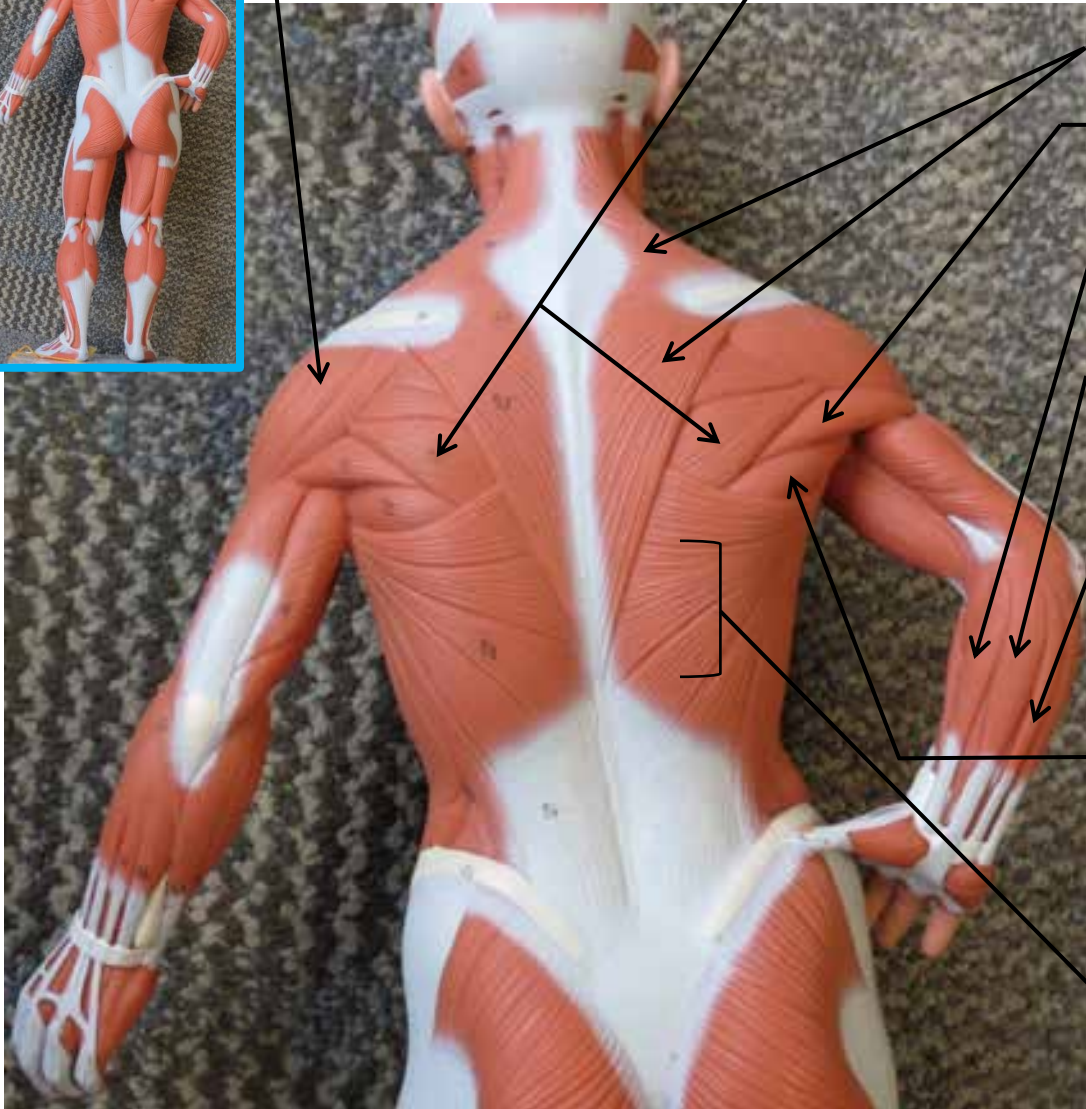
# SMALL MUSCLE MODELS



# SMALL MUSCLE MODELS



# SMALL MUSCLE MODELS



# SMALL MUSCLE MODELS

